



---

Year: 2022

---

## Clinical assessment of image quality, usability and patient comfort in dedicated spiral breast computed tomography

Schmidt, Cynthia Sabrina ; Zellweger, Caroline ; Wieler, Jann ; Berger, Nicole ; Marcon, Magda ; Frauenfelder, Thomas ; Boss, Andreas

**Abstract:** **OBJECTIVE** To investigate aspects of image quality, feasibility and patient comfort in dedicated spiral breast computed tomography (B-CT) in a large patient cohort. **METHODS** This retrospective study was approved by the institutional review board. 2418 B-CT scans from 1222 women examined between 04/16/2019 and 04/13/2022 were analyzed. Patients evaluated their comfort during the examination, radiographers carrying out the scans evaluated the patient's mobility and usability of the B-CT device, whereas radiologists assessed lesion contrast, detectability of calcifications, breast coverage and overall image quality. For semi-quantitative assessment, a Likert-Scale was used and statistical significance and correlations were calculated using ANOVAs and Spearman tests. **RESULTS** Comfort, mobility and usability of the B-CT were rated each with either "no" or "negligible" complaints in >99%. Image quality was rated with "no" or "negligible complaints" in 96.7%. Lesion contrast and detectability of calcifications were rated either "optimal" or "good" in 92.6% and 98.4%. "Complete" and "almost complete" breast coverage were reported in 41.9%, while the pectoral muscle was found not to be covered in 56.0%. Major parts of the breast were not covered in 2.1%. Some variables were significantly correlated, such as age with comfort ( $r = -0.168$ ,  $p < .001$ ) and mobility ( $r = -0.172$ ,  $p < .001$ ) as well as patient weight with lesion contrast ( $r = 0.172$ ,  $p < .001$ ) and breast coverage ( $r = -0.109$ ,  $p < .001$ ). **CONCLUSIONS** B-CT provides high image quality and contrast of soft tissue lesions as well as calcifications, while covering the pre-pectoral areas of the breast remains challenging. B-CT is easy to operate for the radiographer and comfortable for the majority of women.

DOI: <https://doi.org/10.1016/j.clinimag.2022.07.001>

Posted at the Zurich Open Repository and Archive, University of Zurich

ZORA URL: <https://doi.org/10.5167/uzh-220452>

Journal Article

Published Version

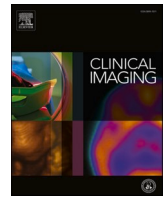

The following work is licensed under a Creative Commons: Attribution 4.0 International (CC BY 4.0) License.

Originally published at:

Schmidt, Cynthia Sabrina; Zellweger, Caroline; Wieler, Jann; Berger, Nicole; Marcon, Magda; Frauenfelder, Thomas; Boss, Andreas (2022). Clinical assessment of image quality, usability and patient comfort in dedicated spiral breast computed tomography. *Clinical Imaging*, 90:50-58.

DOI: <https://doi.org/10.1016/j.clinimag.2022.07.001>



## Breast Imaging

## Clinical assessment of image quality, usability and patient comfort in dedicated spiral breast computed tomography

Cynthia Sabrina Schmidt<sup>a,\*</sup>, Caroline Zellweger<sup>a</sup>, Jann Wieler<sup>a</sup>, Nicole Berger<sup>b</sup>, Magda Marcon<sup>c</sup>, Thomas Frauenfelder<sup>a</sup>, Andreas Boss<sup>a</sup><sup>a</sup> Institute of Diagnostic and Interventional Radiology, University Hospital Zurich, Raemistrasse 100, CH-8091 Zurich, Switzerland<sup>b</sup> Institute of Radiology, Spital Lachen, Oberdorfstrasse 41, CH-8853 Lachen, Switzerland<sup>c</sup> Department of Radiology, Ente Ospedaliero Cantonale (EOC), Via Tesserete 46, CH-6900 Lugano, Switzerland

## ARTICLE INFO

## Keywords:

Breast  
Breast neoplasms  
Tomography  
Spiral computed  
Mammography

## ABSTRACT

**Objective:** To investigate aspects of image quality, feasibility and patient comfort in dedicated spiral breast computed tomography (B-CT) in a large patient cohort.

**Methods:** This retrospective study was approved by the institutional review board. 2418 B-CT scans from 1222 women examined between 04/16/2019 and 04/13/2022 were analyzed. Patients evaluated their comfort during the examination, radiographers carrying out the scans evaluated the patient's mobility and usability of the B-CT device, whereas radiologists assessed lesion contrast, detectability of calcifications, breast coverage and overall image quality. For semi-quantitative assessment, a Likert-Scale was used and statistical significance and correlations were calculated using ANOVAs and Spearman tests.

**Results:** Comfort, mobility and usability of the B-CT were rated each with either “no” or “negligible” complaints in >99%. Image quality was rated with “no” or “negligible complaints” in 96.7%. Lesion contrast and detectability of calcifications were rated either “optimal” or “good” in 92.6% and 98.4%. “Complete” and “almost complete” breast coverage were reported in 41.9%, while the pectoral muscle was found not to be covered in 56.0%. Major parts of the breast were not covered in 2.1%. Some variables were significantly correlated, such as age with comfort ( $\rho = -0.168$ ,  $p < .001$ ) and mobility ( $\rho = -0.172$ ,  $p < .001$ ) as well as patient weight with lesion contrast ( $\rho = 0.172$ ,  $p < .001$ ) and breast coverage ( $\rho = -0.109$ ,  $p < .001$ ).

**Conclusions:** B-CT provides high image quality and contrast of soft tissue lesions as well as calcifications, while covering the pre-pectoral areas of the breast remains challenging. B-CT is easy to operate for the radiographer and comfortable for the majority of women.

## 1. Introduction

Breast cancer is the most frequent malignancy and most common cause of cancer-related death among women, with around 2.1 million newly diagnosed cases and 0.6 million deaths globally each year.<sup>1</sup> Early detection improves clinical outcome and survival of breast cancer patients.<sup>2,3</sup> Using mammography as a screening tool leads to earlier cancer detection and has been shown to reduce patient mortality.<sup>4</sup> Consequently, many countries have implemented nationwide routine breast cancer screening programs.

While being the most practical modality in the screening setting by providing high spatial resolution and being both time- and cost-efficient, two-dimensional mammography is prone to create breast tissue overlap and therefore potentially restricts differentiation between normal tissue and pathology. Diagnostic performance is most notably reduced for small lesions and non-calcifying tumors, particularly in dense breasts, where sensitivity can drop below 50%.<sup>5,6</sup> Furthermore, breast tissue visualization depends on adequate breast compression, which patients often describe as painful. This potentially leads to women dropping out of the screening program, which could lower its efficiency.<sup>7</sup>

**Abbreviations:** B-CT, Dedicated Breast CT; *MPR*, Multiplanar Reconstruction; *MIP*, Maximum Intensity Projection; *ACR*, American College of Radiology; *HHUS*, Hand-held Ultrasound; *ABUS*, Automated Breast Ultrasound System; *SD*, Standard Deviation; *BMI*, Body Mass Index; *PGMI*, Perfect, Good, Moderate, Inadequate; *MLO*, Mediolateral Oblique.

\* Corresponding author at: Institute of Diagnostic and Interventional Radiology, University Hospital Zurich, Raemistrasse 100, CH-8091 Zurich, Switzerland.

E-mail address: [cynthiasabrina.schmidt@uzh.ch](mailto:cynthiasabrina.schmidt@uzh.ch) (C.S. Schmidt).

<https://doi.org/10.1016/j.clinimag.2022.07.001>

Received 22 March 2022; Received in revised form 29 June 2022; Accepted 6 July 2022

Available online 11 July 2022

0899-7071/© 2022 The Authors. Published by Elsevier Inc. This is an open access article under the CC BY license (<http://creativecommons.org/licenses/by/4.0/>).

Consequently, alternative diagnostic modalities have been established, such as breast ultrasound and digital tomosynthesis, which are predominantly used to further investigate screening findings, and breast MRI, which additionally serves as a screening tool for high-risk groups. Breast MRI delivers high sensitivity while being compression- and radiation-free, but it is also expensive, time-consuming and relies on intravenous contrast injection.

One recent development in breast imaging has been the introduction of dedicated breast CT (B-CT) to the clinical setting. B-CT is a true three-dimensional imaging modality; thus, there is no breast tissue overlap. Compression of the breast is not required, and preliminary data suggests that patients are generally comfortable during B-CT.<sup>8–10</sup> Technical improvements of the initial cone-beam B-CT generations, such as the implementation of photon-counting spiral B-CT, have resulted in sufficient spatial resolution to reliably detect breast masses and microcalcifications<sup>8,9,11</sup> at similar dose levels compared to mammography.<sup>12</sup> Furthermore, the diagnostic accuracy of contrast-enhanced B-CT has been reported to be comparable to MRI in dense breasts.<sup>13</sup>

Compared to mammography, B-CT is considerably more expensive. Furthermore, processing the acquired image data necessitates high computing power and although scan times are short, the whole examination currently takes longer than mammography.

Due to its recent clinical introduction, B-CT is not (yet) available to most patients. Consequently, there is insufficient image quality data in large cohorts and little evidence on how to evaluate B-CT image quality.

The aim of this study is to provide an overview of the overall feasibility of B-CT as a new breast-imaging modality by evaluating B-CT examinations of a large patient cohort on aspects of image quality, comfort and usability as rated by radiologists, radiographers and patients. Furthermore, as performing the scan might be challenging for older or obese patients due to its horizontal design and the image acquisition taking place in the prone position, we also explore how those ratings differ between age-, weight- and height groups.

## 2. Material and methods

### 2.1. Patient population

This retrospective study was approved by the local ethics committee. Written informed consent was obtained from all participants prior to examination. From 04/16/2019 to 04/19/2022 a total number of 2194 women opted for B-CT imaging in our department as an alternative to mammography. Indications for the B-CT examination were as follows: 1) screening for early detection of breast cancer ( $n = 1637$ ), 2) follow-up after breast cancer and breast-conserving therapy ( $n = 449$ ), 3) follow-up of a BI-RADS 3 or 4 lesion ( $n = 86$ ) and 4) local staging of a known breast cancer ( $n = 22$ ).

follow-up of a BI-RADS 3 or 4 lesion ( $n = 86$ ) and 4) local staging of a known breast cancer ( $n = 22$ ).

Although we could obtain feasibility assessments by patients, radiographers and radiologists for the majority of examinations, documentation was entirely unavailable for 66 patients and partially incomplete for 906 cases, which were excluded from our analysis. Consequently, 1222 women were included in the study (Fig. 1).

### 2.2. Dedicated B-CT setup

All examinations were performed using a dedicated spiral B-CT scanner (nu:view, AB-CT – Advanced Breast-CT GmbH, Erlangen, Germany). The system consists of a horizontal CT gantry with an examination table, on which the patient is positioned in the prone position with the ipsilateral arm outstretched next to the body and the contralateral arm folded at head level. The head is rotated with the cheek resting on the patient table. Scans were performed separately for each side by placing the targeted breast compression-free through a tabletop opening into a plastic cylinder within the acquisition field of view. In some cases, a weighted pillow was placed on the ipsilateral shoulder to bring the chest wall closer to the field of view. Patients were instructed to keep their breathing calm and regular during image acquisition to reduce movement artifacts. All examinations were performed without contrast media.

The system is equipped with a photon-counting cadmium-telluride detector. Scan length can be adjusted to three different levels (80/120/160 mm) as needed according to the individual breast size. X-ray tube voltage is fixed at 60 kV. A fixed tube current of 32 mA was selected to allow for radiation doses similar to routine mammography.<sup>10</sup> Each data set was processed using the nu:view reconstruction software with a Feldkamp-type filtered back-projection algorithm. Both a smooth (smooth kernel,  $300\mu\text{m}^3$ ) and a high-resolution option (sharp kernel,  $150\mu\text{m}^3$ ) were reconstructed to further investigate lesions and microcalcifications.

Image analysis was conducted on a PACS workstation equipped with a dedicated breast imaging display software (AGFA Impax 6/ AGFA Impax EE R20, Mortsel, Belgium) and the option to perform multiplanar reconstruction (MPR) as well as the possibility to generate maximum intensity projection (MIP) images, which were predominantly used to detect calcifications and soft-tissue lesions.

Fig. 2 Provides two exemplary B-CT examinations; Case 1 shows a group of microcalcifications and Case 2 a soft-tissue mass, both corresponding to malignant lesions.

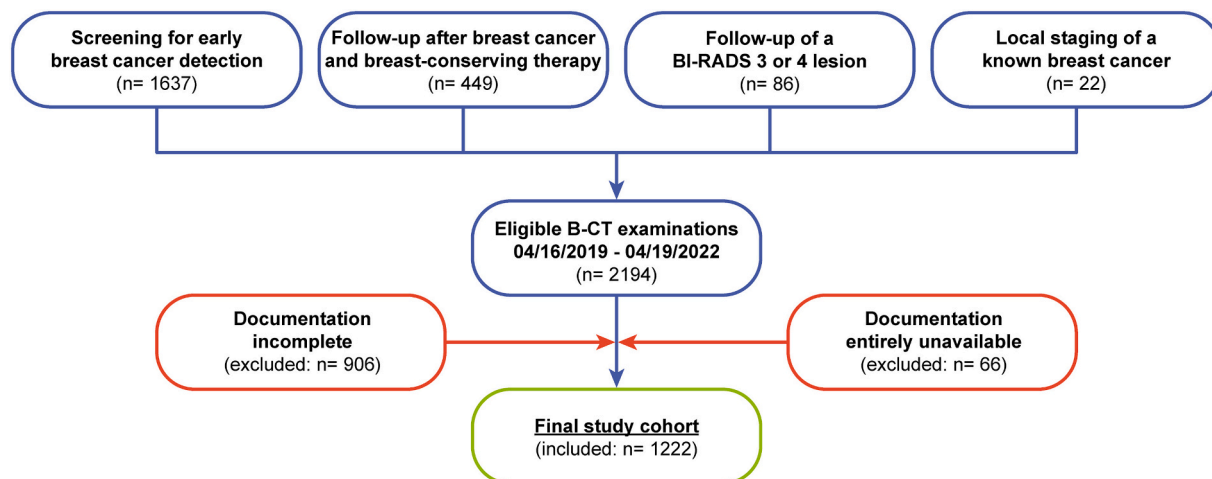
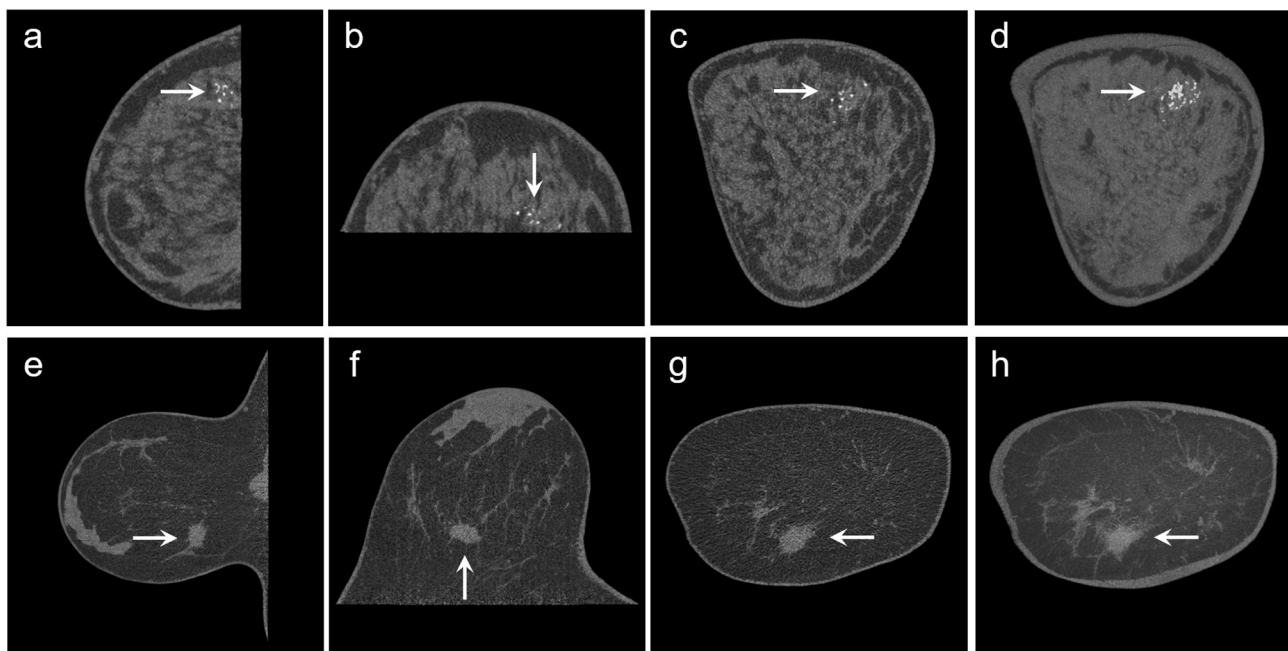


Fig. 1. Flowchart showing the inclusion and exclusion criteria to determine the final study population.



**Fig. 2.** B-CT examinations of two patients with each one sagittal (a,e), axial (b,f) and coronal (c,g) reconstruction and a corresponding 10 mm maximum intensity projection (MIP; d,h). Case 1 (a-d) shows the right breast of a 52-year-old patient with a group of microcalcifications, later confirmed as a ductal carcinoma in-situ (DCIS). Case 2 (e-h) shows the right breast of a 61-year-old patient with a soft-tissue lesion, later confirmed as an invasive ductal carcinoma.

### 2.3. Data acquisition and image evaluation

All data were systematically obtained as part of a post-market clinical follow-up (PMCF) plan for quality control of medical devices and retrospectively analyzed for this study.

After the B-CT examination, all participants were surveyed by one alternating radiographer with varying degrees of experience in breast imaging about their general comfort level during the scan as well as their degree of mobility during patient positioning, which was documented on a Likert scale ranging from 1 to 5. The radiographer also rated the usability of the B-CT on a Likert scale from 1 to 5.

B-CT image evaluation was performed by one of 18 residents with varying experience under supervision by one of 5 senior radiologists with ~4–20 years of experience in breast imaging directly after the B-CT scan based on the American College of Radiology (ACR) Breast Imaging Reporting and Data System (BI-RADS) 5th edition.<sup>14</sup> After the findings were discussed, breast tissue coverage (on a Likert scale of 1–4), overall image quality (1–5), and – if applicable – detectability of calcifications as well as lesion contrast (0–5) were documented by the radiology resident.

In patients with high glandular density, a history of breast cancer, clinical findings (e.g. a palpable mass or mastodynia) or suspected pathologies in B-CT, an additional ultrasound examination was performed, either using hand-held ultrasound (HHUS) or an automated breast ultrasound system (ABUS). B-CT images were compared to previous mammograms or B-CT studies, if available.

All assessment criteria and corresponding scales are listed in Table 1.

### 2.4. Statistical analysis

Continuous variables were reported as means with standard deviations (SD), ordinal variables as absolute numbers (n) and percent.

Patients were categorized by age, height, weight and Body Mass Index (BMI) as specified in Table 2. BMI was calculated and categorized according to the WHO classification.<sup>15</sup>

One-way ANOVAs with Bonferroni post hoc comparisons were used to test for significant differences between subgroups of age, height,

weight and BMI.

Correlation analyses were conducted using the Spearman's correlation test; correlation coefficients ( $\rho$ ) between 0.0 and 0.09 were interpreted as negligible,  $\rho$  between 0.1 and 0.39 as weak,  $\rho$  between 0.4 and 0.69 as moderate and  $\rho$  between 0.7 and 1.0 as strong associations.<sup>16</sup>

$P$ -values  $< .05$  were considered statistically significant. Statistical analyses were performed using commercially available software (SPSS, release 26.0; IBM Corp., Armonk, NY, USA).

## 3. Results

### 3.1. Patient demographics

Between 04/16/2019 and 04/13/2022, 1222 women received 2418 B-CT scans. Bilateral B-CT was performed in 1196 women (97.9%) while unilateral B-CT was performed in 26 women (2.1%). Mean age was 57.7 years, mean height was 165.8 cm, mean weight was 66.8 kg and mean BMI was 24.3 kg/m<sup>2</sup>.

Table 3 Provides more detailed patient characteristics.

### 3.2. Descriptive statistics

Almost all women declared “no” or “negligible” complaints about comfort ( $n = 1216$ ; 99.5%) and “no” or “negligible” complaints about mobility ( $n = 1213$ ; 99.3%). The radiographers rated B-CT usability with “no” or “negligible” complaints in 99.4% ( $n = 1215$ ). Radiologists rated image quality with “no” or “negligible” complaints in 96.7% ( $n = 1182$ ). Lesions were found in 525 patients (43.0%), for which contrast was rated “optimal” or “good” in 92.6% ( $n = 486/525$ ). Calcifications were reported in 926 examinations (75.8%), with detectability regarded as “optimal” or “good” in 98.4% ( $n = 911/926$ ). Complete and almost complete coverage were indicated in 41.9% ( $n = 512$ ); major parts of the breast were not covered in 2.1% ( $n = 26$ ).

Fig. 3 Gives an overview of comfort, mobility and usability ratings.

Fig. 4 Gives an overview of image quality, lesion contrast, detectability of calcifications and breast coverage ratings.

**Table 1**  
Description of all assessment criteria within the Likert scale scoring system

	0	1	2	3	4	5
Rating by patient	Comfort	No complaints	Negligible complaints	Minor injuries	Injuries requiring treatment	Serious injuries
Rating by radiographer	Mobility	No complaints	Negligible complaints	Minor complaints	Major complaints	Examination not possible
Rating by radiographer	Usability of the device	No complaints	Negligible complaints	Minor complaints	Major complaints	Examination not possible
Rating by radiologist	Image quality	No complaints	Negligible complaints	Minor complaints	Major complaints	Not diagnostic
Rating by radiologist	Lesion contrast	No lesion detected	Good contrast	Moderate contrast	Poor contrast	Not diagnostic
Rating by radiologist	Detectability of calcifications	No calcification detected	Optimal contrast	Moderate contrast	Poor contrast	Not diagnostic
Rating by radiologist	Breast coverage	Complete coverage including fat streak behind glandular tissue and almost complete coverage of the pectoral muscle	Good contrast	Almost complete coverage including pectoral muscle	Major parts of the breast are not covered	–

**Table 2**  
Patient groups as categorized by age, height, weight and Body Mass Index (BMI) with corresponding cases per subset (n)

Age groups	<50 years (n = 203/16.6%)	50–59 years (n = 574/47.0%)	60–69 years (n = 283/23.2%)	≥70 years (n = 162/13.3%)
Height groups	<160 cm (n = 150/12.3%)	160–164 cm (n = 318/26.0%)	165–169 cm (n = 406/33.2%)	≥170 cm (n = 348/28.5%)
Weight groups	<60 kg (n = 332/27.2%)	60–69 kg (n = 451/36.9%)	70–79 kg (n = 263/21.5%)	≥80 kg (n = 176/14.4%)
BMI groups	< 18.5 kg/m <sup>2</sup> (n = 50/4.1%)	18.5 kg/m <sup>2</sup> –24.9 kg/m <sup>2</sup> (n = 716/58.6%)	25.0 kg/m <sup>2</sup> –29.9 kg/m <sup>2</sup> (n = 329/26.9%)	≥30.0 kg/m <sup>2</sup> (n = 127/10.4%)



**Table 3**

Patient demographics and characteristics

Parameter	Value
No. of participants	1222
With unilateral mastectomy	26 (2.1)
With additional ultrasound examination	868 (71.0)
Soft-tissue lesions	525 (43.0)
Calcifications	926 (75.8)
Mean age (y)*	57.7 ± 10.1 (21–94)
Mean weight (kg)*	66.8 ± 12.4 (34–136)
Mean height (cm)*	165.8 ± 6.2 (137–185)
Mean BMI (kg/m <sup>2</sup> )*	24.3 ± 4.5 (12–50)

Note. – Unless otherwise indicated, data are number of patients. Data in parentheses are percentages.

\* Data are ±standard deviation; data in parentheses represent the range.

### 3.3. Group analyses

Ratings of comfort ( $p < .001$ ) and mobility ( $p < .001$ ) were significantly different between age groups, with older women reporting discomfort and decreased mobility more frequently (Fig. 5). Usability of the device was also rated worse for older women ( $p = .021$ ).

Ratings of breast coverage were significantly different between height groups ( $p = .01$ , Fig. 6), with tall women demonstrating decreased coverage more frequently.

Ratings of both usability of the device ( $p = .007$ ) and breast coverage ( $p < .001$ , Fig. 6) were significantly worse among heavier weight groups, while lesion contrast ( $p = .001$ ) was significantly better among heavier groups.

Ratings of usability of the device ( $p = .003$ ) and breast coverage ( $p = .008$ , Fig. 6) were significantly different between BMI groups, with both having been rated worse for women with higher BMI. BMI groups also demonstrated significantly different ratings of lesion contrast ( $p < .001$ ), as groups with higher BMI received ratings of optimal lesion contrast more frequently.

All other parameters showed no significant differences between groups.

### 3.4. Correlations

Weak correlations were found between comfort and age ( $\rho = -0.168$ ,

$p < .001$ ) as well as mobility and age ( $\rho = -0.172$ ,  $p < .001$ ); comfort and mobility were moderately correlated ( $\rho = 0.544$ ,  $p < .001$ ).

Usability of the device was moderately correlated with mobility ( $\rho = 0.446$ ,  $p < .001$ ) and weakly correlated with comfort ( $\rho = 0.314$ ,  $p < .001$ ).

Detectability of calcifications and lesion contrast were moderately correlated ( $\rho = 0.487$ ,  $p < .001$ ). Weak associations were found between detectability of calcifications and image quality ( $\rho = 0.397$ ,  $p < .001$ ) and between image quality and lesion contrast ( $\rho = 0.273$ ,  $p < .001$ ). Lesion contrast was weakly correlated with body weight ( $\rho = 0.172$ ,  $p < .001$ ) and BMI ( $\rho = 0.171$ ,  $p = .001$ ).

Breast coverage was weakly correlated with weight ( $\rho = -0.109$ ,  $p < .001$ ) and to a negligible extent with height ( $\rho = -0.088$ ,  $p = .002$ ).

All statistically significant correlations are listed in Table 4.

## 4. Discussion

This large-scale retrospective study of dedicated B-CT image data analyses characteristics of image quality and patient comfort in non-contrast B-CT examinations. The vast majority of patients rated the examination as comfortable, with some shortcomings for elderly and less mobile patients. The radiographers carrying out the examinations rated the device as easy to operate. Image quality as well as delineation of soft tissue lesions and calcifications overall received high ratings from radiologists, while breast coverage was found to be limited.

In order to increase diagnostic accuracy of mammography, quality criteria have been established, such as the PGMI (Perfect, Good, Moderate, Inadequate) assessment system introduced by the National Health Service Breast Screening Programme,<sup>17</sup> and the Breast imaging-reporting and data system (BI-RADS) implemented by the American College of Radiology.<sup>14</sup> Jung et al.<sup>18</sup> have demonstrated that BI-RADS criteria to describe intramammary lesions can be successfully applied to B-CT reports. However, so far, no comprehensive standards have been established for evaluating overall B-CT image quality.

In our study, B-CT image quality was generally regarded as high, with negligible complaints resulting from known “ring” artifacts caused by the image reconstruction algorithm or those artifacts caused by postinterventional tissue markers.<sup>10,19</sup> Exceptionally low image quality ratings, which very rarely occurred, might be explained by movement artifacts or technical problems during data acquisition.

Positioning of the breast is a crucial element to mammography.<sup>20</sup> As

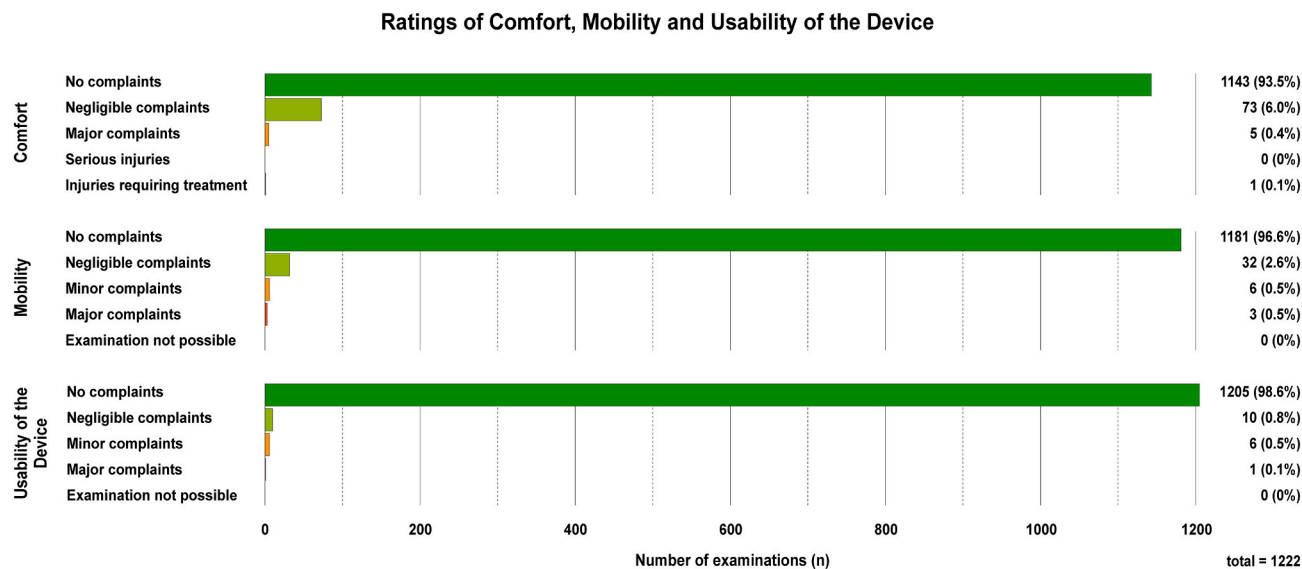
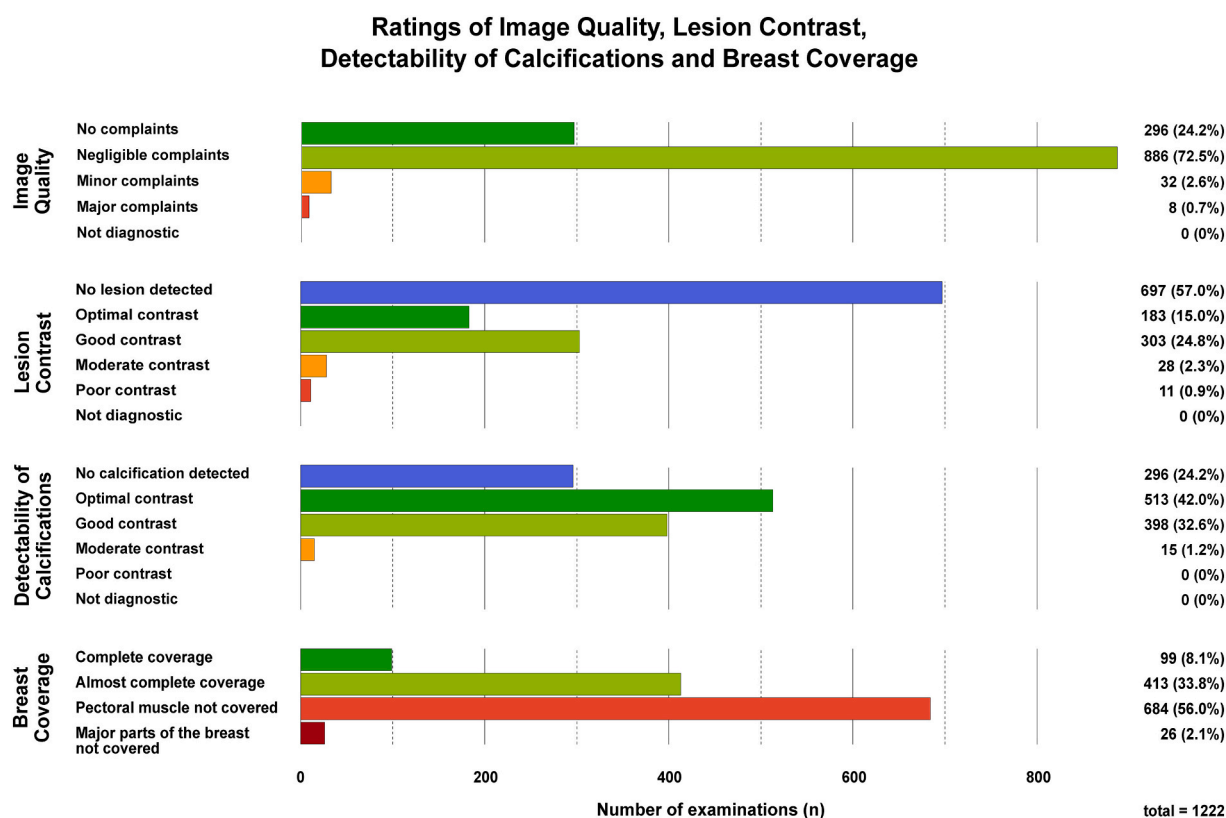
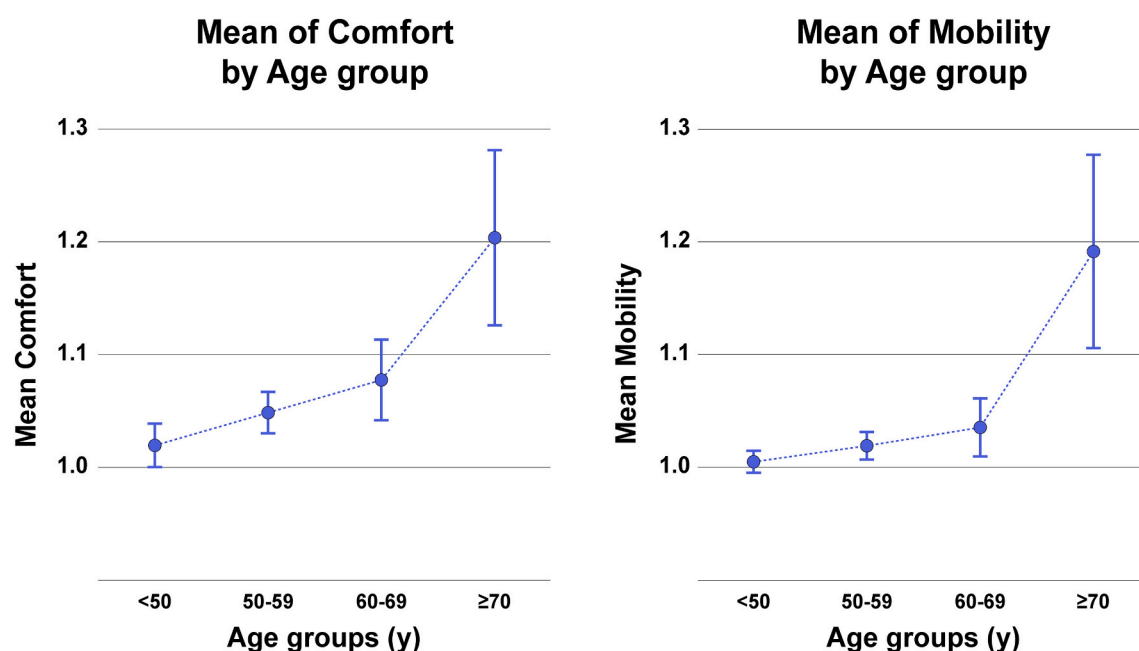


Fig. 3. Graphical representation of qualitative Likert scale ratings of comfort, mobility and usability of the device, ranging from a score of 1 (“no complaints”) to a score of 5 (comfort: “serious injuries”; mobility/ usability of the device: “examination not possible”).



**Fig. 4.** Graphical representation of qualitative Likert scale ratings of image quality, lesion contrast, detectability of calcifications and breast coverage, either ranging from a score of 0 (lesion contrast: “no lesion detected”; detectability of calcifications: “no calcification detected”) or a score of 1 (image quality: “no complaints”; breast coverage: “complete coverage”) to a score of 4 (breast coverage: “major parts of the breast not covered”) or 5 (lesion contrast/ detectability of calcifications/ image quality: “not diagnostic”).



**Fig. 5.** Mean ratings of comfort and mobility on a qualitative Likert scale ranging from a score of 1 (“no complaints”) to a score of 5 (comfort: “serious injuries”; mobility: “examination not possible”) for each age group (years) including error bars representing the 95% confidence interval.

optimal positioning and compression are associated with higher image quality, radiographers may substantially impact mammographic performance.<sup>21,22</sup> B-CT does not rely on breast compression to achieve high image quality, and our study could demonstrate that radiographers

regarded the device as easy to use, which includes positioning the breast into the scanners field of view. Intuitive handling might entail a steep learning curve, so that good image quality results might be achieved with little training.



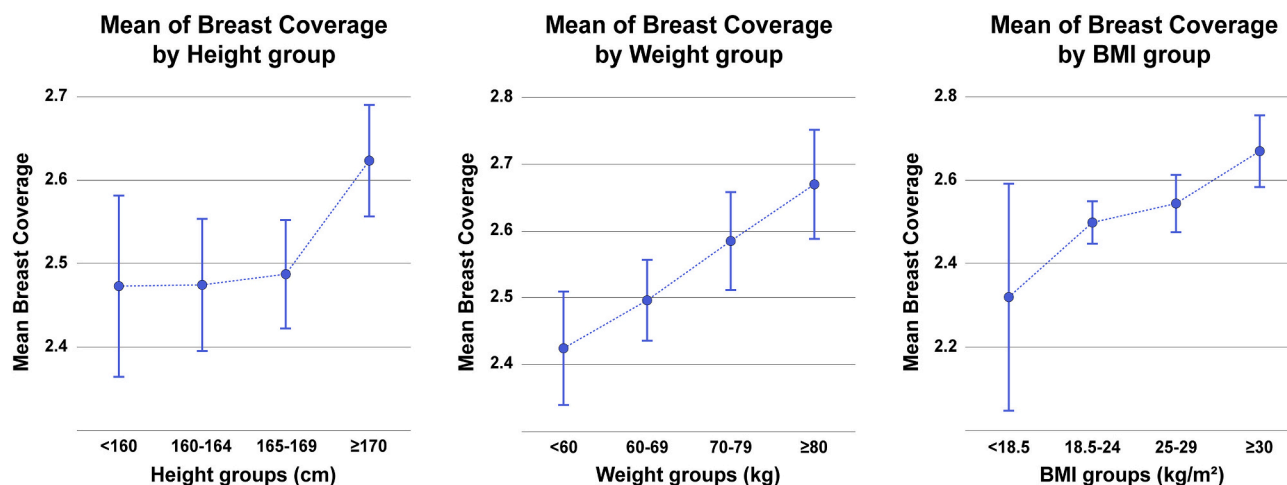


Fig. 6. Mean ratings of breast coverage on a qualitative Likert scale ranging from a score of 1 (“complete coverage”) to a score of 4 (“major parts of the breast not covered”) for each height group (cm), weight group (kg) and BMI group (kg/m<sup>2</sup>) including error bars representing the 95% confidence interval.

Table 4

Overview of all statistically significant correlations as calculated with Spearman's test

Variable 1	Variable 2	$\rho$	p-value	Strength
Comfort	& Mobility	0.544	<0.001	Moderate
Detectability of calcifications	& Lesion contrast	0.487	<0.001	
Mobility	& Usability of the device	0.446	<0.001	
Detectability of calcifications	& Image quality	0.397	<0.001	
Comfort	& Usability of the device	0.314	<0.001	Weak
Image quality	& Lesion contrast	0.273	<0.001	
Body height	& Body weight	0.254	<0.001	
Age	& Mobility	-0.172	<0.001	
Body weight	& Lesion contrast	0.172	<0.001	
BMI	& Lesion contrast	0.171	<0.001	
Age	& Comfort	-0.168	<0.001	
Age	& Body height	-0.164	<0.001	
Age	& BMI	0.111	<0.001	
Body weight	& Breast coverage	-0.109	<0.001	
Age	& Lesion contrast	0.092	0.036	Negligible
Body height	& Breast coverage	-0.088	0.002	
Breast coverage	& Image quality	0.082	0.004	
BMI	& Breast coverage	-0.079	0.005	
Comfort	& Image quality	-0.076	0.008	
Age	& Usability of the device	-0.073	0.011	
BMI	& Usability of the device	-0.058	0.044	

Coverage of the pectoral muscle is a major determinant of mammographic image quality,<sup>21,23</sup> which makes it a key component in most quality assurance guidelines, including the PGMI system.<sup>17</sup> Our data is consistent with previous studies reporting insufficient coverage of the pectoral muscle in B-CT examinations.<sup>9</sup> The mammographic mediolateral oblique (MLO) projection is performed with an x-ray tube angulation designed to display the lateral aspect of the breast and axillary tail.<sup>23,24</sup> Due to the current tabletop design, B-CT taking place in the prone position and the CT gantry rotating along the horizontal axis, covering the axillary tail is challenging.<sup>11</sup> Our study demonstrated that B-CT scans of women with higher body height and -weight had inferior breast coverage, which might be explained by difficulties of bringing the thoracic wall close to the tabletop opening. Incomplete breast coverage might result in missing relevant imaging findings. To counter this, weighted pillows were placed on the patients' ipsilateral shoulder,

pushing the chest further into the field of view. Also, additional breast ultrasound may be recommended in these cases.

In line with previous research,<sup>8,9,25</sup> our study found adequate ratings of delineation for soft tissue lesions and calcifications. While our study did not compare B-CT findings with mammography or MRI to validate the imaging results, prior studies have found B-CT lesion detection to be reliable and comparable to mammography.<sup>8,25</sup> In our department, soft-tissue lesions and suspicious or unclear findings are routinely double-checked with ultrasound and scheduled for follow-up or biopsy in accordance with the ACR BI-RADS recommendations.<sup>14</sup> Better ratings of lesion contrast were found in women with higher body weight. As body weight has a strong positive correlation with breast size and non-dense breast tissue,<sup>26,27</sup> lower breast density could have led to better delineation of soft tissue lesions; however, breast density itself was not investigated in our study. Few studies have been done on the assessment of breast density in B-CT and its relation to lesion delineation.<sup>9,28,29</sup> Dense glandular tissue reduces the detection rate of soft tissue lesions in both B-CT and mammography.<sup>30,31</sup> A classification system for breast density in dedicated B-CT was recently proposed, which aims to guide the decision on whether to perform additional ultrasound after B-CT to optimize lesion detection.<sup>31</sup> In our study, neither age, height nor weight had an influence on the detectability of calcifications.

Another benefit of B-CT is that no compression is needed to perform the scan, which is a common complaint of women undergoing mammography. While older women – who more frequently suffered from impaired mobility – were slightly less comfortable, in accordance with prior studies,<sup>9,10,32</sup> the majority of women reported high levels of comfort. Hence, B-CT could constitute an alternative imaging modality in the screening setting for women who would otherwise deny breast cancer screening due to breast compression and mastodynia during mammography. One study running a simulation of the potential impact of dedicated B-CT on the German breast cancer screening program found that B-CT might increase attendance rates and lead to earlier cancer detection.<sup>33</sup> Lack of compression could also be of interest to patients with breast implants, as these can be scanned without risk of rupture, which is a rare adverse effect of mammography.<sup>34</sup>

Whereas our study was focussed on the screening setting and (to a lesser extent) breast cancer follow-up, B-CT might also provide further characterization of unclear imaging findings. While MRI is considered the most sensitive breast imaging modality, it is restricted by the requirement of intravenous contrast injection, whereas non-enhanced B-CT can already provide valuable diagnostic information, e.g. on the presence of micro-calcifications, which cannot reliably be visualized by MRI. For patients with MRI contraindications, such as implanted devices or claustrophobia, B-CT could be a suitable alternative as it operates

without a magnetic field and has an open design.

Our study has several limitations. First, this is a retrospective analysis of data collected as part of a mandatory post-market clinical follow-up (PMCF) plan within the clinical workflow, which may introduce information bias and restricted the number of variables that we were able to assess. In this context and due to the clinical setting of the study, an interrater agreement between the several participating radiologists and radiographers could not be calculated and the analysis might be subject to inter-reader variabilities. Our study was focussed on aspects of B-CT feasibility and performance as part of the clinical workflow; in this regard, the grading of image quality parameters was performed by residents under the supervision of senior radiologists. While this constellation is representative to the clinical routine, the residents are at risk of losing independence in their assessments and ratings solely by senior radiologists could not be provided. Furthermore, especially patients with high levels of discomfort during previous mammographic studies opt for B-CT, which could lead to a selection bias. In that respect, our survey did not include a question regarding previous mammographic studies and we therefore could not compare ratings between cohorts with and without prior mammographic history. Also, we used a simple survey design consisting of Likert scales in which patients did not fill out the questionnaire themselves but were interviewed by the radiographer, which might cause interviewer bias. A multimodal comparison or the evaluation of radiation dose levels are outside the scope of this study. Moreover, given the low cancer detection rate among the general breast cancer screening cohort,<sup>35</sup> our sample size was too small for accurate calculations of sensitivity and specificity. Last, our study does not aim to represent a comprehensive synopsis of image quality criteria as it is still unclear which other factors are relevant in determining B-CT image quality.

## 5. Conclusions

Our study shows that B-CT examinations are comfortable for the majority of women, and the system is easy to use for the radiographer. B-CT overall provides high image quality and contrast of soft tissue lesions and calcifications. As such, B-CT could become a valuable screening tool for women who oppose the breast compression during mammography. Covering the pre-pectoral areas of the breast still poses a challenge with the current design, particularly in large and tall women.

## Funding

This research did not receive any specific grant from funding agencies in the public, commercial, or not-for-profit sectors.

## Declaration of competing interest

None.

## References

- Bray F, Ferlay J, Soerjomataram I, Siegel RL, Torre LA, Jemal A. Global cancer statistics 2018: GLOBOCAN estimates of incidence and mortality worldwide for 36 cancers in 185 countries. *CA Cancer J Clin* 2018;68(6):394–424. <https://doi.org/10.3322/caac.21492>.
- Saadatmand S, Bretveld R, Siesling S, Tilanus-Linthorst MMA. Influence of tumour stage at breast cancer detection on survival in modern times: population based study in 173 797 patients. *BMJ (Online)* 2015;351. <https://doi.org/10.1136/bmj.h4901>.
- Marcon M, Dedes K, Varga Z, Frauenfelder T, Boss A. Influence of breast cancer opportunistic screening on aesthetic surgical outcome: a single-center retrospective study in Switzerland. *Breast J* 2018;24(3):285–90. <https://doi.org/10.1111/tbj.12883>.
- Duffy SW, Tabár L, Yen AMF, et al. Mammography screening reduces rates of advanced and fatal breast cancers: results in 549,091 women. *Cancer* 2020;126(13):2971–9. <https://doi.org/10.1002/cncr.32859>.
- Kolb TM, Lichy J, Newhouse JH. Comparison of the performance of screening mammography, physical examination, and breast US and evaluation of factors that influence them: an analysis of 27,825 patient evaluations. *Radiology* 2002;225(1):165–75. <https://doi.org/10.1148/radiol.2251011667>.
- Weigel S, Heindel W, Heidrich J, Hense HW, Heidinger O. Digital mammography screening: sensitivity of the programme dependent on breast density. *Eur Radiol* 2017;27(7):2744–51. <https://doi.org/10.1007/s00330-016-4636-4>.
- Andrews FJ. Pain during mammography: implications for breast screening programmes. *Australas Radiol* 2001;45(2):113–7. <https://doi.org/10.1046/j.1440-1673.2001.00889.x>.
- O'Connell AM, Kawakyu-O'Connor D. Dedicated cone-beam breast computed tomography and diagnostic mammography: comparison of radiation dose, patient comfort, and qualitative review of imaging findings in BI-RADS 4 and 5 lesions. <sb: contribution><sb:title>J Clin Imaging</sb:title></sb:contribution><sb: host><sb:issue><sb:series><sb:title>Sci</sb:title></sb:series></sb:issue></sb: host> 2012;2(7):7. <https://doi.org/10.4103/2156-7514.93274>.
- Lindfors KK, Boone JM, Nelson TR, Yang K, Kwan ALC, Miller DF. Dedicated breast CT: initial clinical experience. *Radiology* 2008;246(3):725–33. <https://doi.org/10.1148/radiol.2463070410>.
- Berger N, Marcon M, Saltybaeva N, et al. Dedicated breast computed tomography with a photon-counting detector: initial results of clinical in vivo imaging. *Invest Radiol* 2019;54(7):409–18. <https://doi.org/10.1097/RLI.0000000000000552>.
- O'Connell A, Conover DL, Zhang Y, et al. Cone-beam CT for breast imaging: radiation dose, breast coverage, and image quality. *Am J Roentgenol* 2010;195(2):496–509. <https://doi.org/10.2214/AJR.08.1017>.
- Kalender WA, Kolditz D, Steiding C, et al. Technical feasibility proof for high-resolution low-dose photon-counting CT of the breast. *Eur Radiol* 2017;27(3):1081–6. <https://doi.org/10.1007/s00330-016-4459-3>.
- Wienbeck S, Fischer U, Luftner-Nagel S, Lotz J, Uhlig J. Contrast-enhanced cone-beam breast-CT (CBBCT): clinical performance compared to mammography and MRI. *Eur Radiol* 2018;28(9):3731–41. <https://doi.org/10.1007/s00330-018-5376-4>.
- D'Orsi CJ, Sickles EA, Mendelson EB, Morris EA. *Breast Imaging Reporting And Data System: ACR BI-RADS—Breast Imaging Atlas*. 5th ed. Reston VA: American College of Radiology; 2013. Published online.
- World Health Organization. *Obesity: Preventing And Managing the Global Epidemic*. World Health Organization Technical Report Series, 894; 2000.
- Schober P, Boer C, Schwarte LA. Correlation coefficients. *Anesth Analg* 2018;126(5):1763–8. <https://doi.org/10.1213/ANE.0000000000002864>.
- National Health Service Breast Cancer Screening Programme, National Quality Assurance Coordinating Group for Radiography. *Quality Assurance Guidelines for Mammography Including Radiographic Quality Control*. Sheffield: NHSBSP; 2006.
- Jung HK, Kuzmiak CM, Kim KW, et al. Potential use of American College of Radiology BI-RADS mammography atlas for reporting and assessing lesions detected on dedicated breast CT imaging: preliminary study. *Acad Radiol* 2017;24(11):1395–401. <https://doi.org/10.1016/j.acra.2017.06.003>.
- Wienbeck S, Nowak C, Zapf A, et al. Artifacts caused by breast tissue markers in a dedicated cone-beam breast CT in comparison to full-field digital mammography. *Acad Radiol* 2017;24(7):908–15. <https://doi.org/10.1016/j.acra.2016.11.017>.
- Popli MB, Teotia R, Narang M, Krishna H. Breast positioning during mammography: mistakes to be avoided. *Breast Cancer Basic Clin Res* 2014;8(1):119–24. <https://doi.org/10.4137/BCBCr.s17617>.
- Taplin SH, Rutter CM, Finder C, Mandelson MT, Houn F, White E. Screening mammography: clinical image quality and the risk of interval breast cancer. *Am J Roentgenol* 2002;178(4):797–803. <https://doi.org/10.2214/ajr.178.4.1780797>.
- Henderson LM, Benefield T, Marsh MW, et al. The influence of mammography technologists on radiologists' ability to interpret screening mammograms in community practice. *Acad Radiol* 2015;22(3):278–89. <https://doi.org/10.1016/j.acra.2014.09.013>.
- Bentley K, Poulos A, Rickard M. Mammography image quality: analysis of evaluation criteria using pectoral muscle presentation. *Radiography* 2008;14(3):189–94. <https://doi.org/10.1016/j.radi.2007.02.002>.
- Bassett LW, Gold RH. Breast radiography using the oblique projection. *Radiology* 1983;149(2):585–7. <https://doi.org/10.1148/radiology.149.2.6622708>.
- He N, Wu YP, Kong Y, et al. The utility of breast cone-beam computed tomography, ultrasound, and digital mammography for detecting malignant breast tumors: a prospective study with 212 patients. *Eur J Radiol* 2016;85(2):392–403. <https://doi.org/10.1016/j.ejrad.2015.11.029>.
- Boyd NF, Martin LJ, Sun L, et al. Body size, mammographic density, and breast cancer risk. *Cancer Epidemiol Biomark Prev* 2006;15(11):2086–92. <https://doi.org/10.1158/1055-9965.EPI-06-0345>.
- Reeves KW, Stone RA, Medngno F, et al. Longitudinal association of anthropometry with mammographic breast density in the Study of Women's Health Across the Nation. *Int J Cancer* 2009;124(5):1169–77. <https://doi.org/10.1002/ijc.23996>.
- Wienbeck S, Uhlig J, Luftner-Nagel S, et al. The role of cone-beam breast-CT for breast cancer detection relative to breast density. *Eur Radiol* 2017;27(12):5185–95. <https://doi.org/10.1007/s00330-017-4911-z>.
- Ma Y, Cao Y, Liu A, et al. A reliability comparison of cone-beam breast computed tomography and mammography: breast density assessment referring to the Fifth Edition of the BI-RADS Atlas. *Acad Radiol* 2019;26(6):752–9. <https://doi.org/10.1016/j.acra.2018.07.023>.
- Chen L, Abbey CK, Nosrateih A, Lindfors KK, Boone JM. Anatomical complexity in breast parenchyma and its implications for optimal breast imaging strategies. *Med Phys* 2012;39(3):1435–41. <https://doi.org/10.1118/1.3685462>.
- Wieler J, Berger N, Frauenfelder T, Marcon M, Boss A. Breast density in dedicated breast computed tomography: proposal of a classification system and interreader reliability. *Medicine* 2021;100(18):e25844. <https://doi.org/10.1097/MD.00000000000025844>.

32. Rößler AC, Wenkel E, Althoff F, Kalender W. The influence of patient positioning in breast CT on breast tissue coverage and patient comfort. *RoFo* 2015;36(2):115–22. <https://doi.org/10.1055/s-0034-1385208>.
33. Ruile G, Djanatljev A, Kriza C, et al. Screening for breast cancer with breast-CT in a ProHTA simulation. *JCompEffectRes* 2015;4(6):553–67. <https://doi.org/10.2217/cer.15.42>.
34. Brown SL, Todd JF, Luu HMdo. Breast implant adverse events during mammography: reports to the Food and Drug Administration. *JWomen's Health* 2004;13(4):371–8. <https://doi.org/10.1089/154099904323087042>.
35. Sprague BL, Coley RY, Kerlikowske K, et al. Assessment of radiologist performance in breast cancer screening using digital breast tomosynthesis vs digital mammography. *JAMA Netw Open* 2020;3(3). <https://doi.org/10.1001/JAMANETWORKOPEN.2020.1759>. e201759-e201759.