

Atlas of various colposcopic findings as my contribution to IFCPC educational material

Professor Goran Grubišić

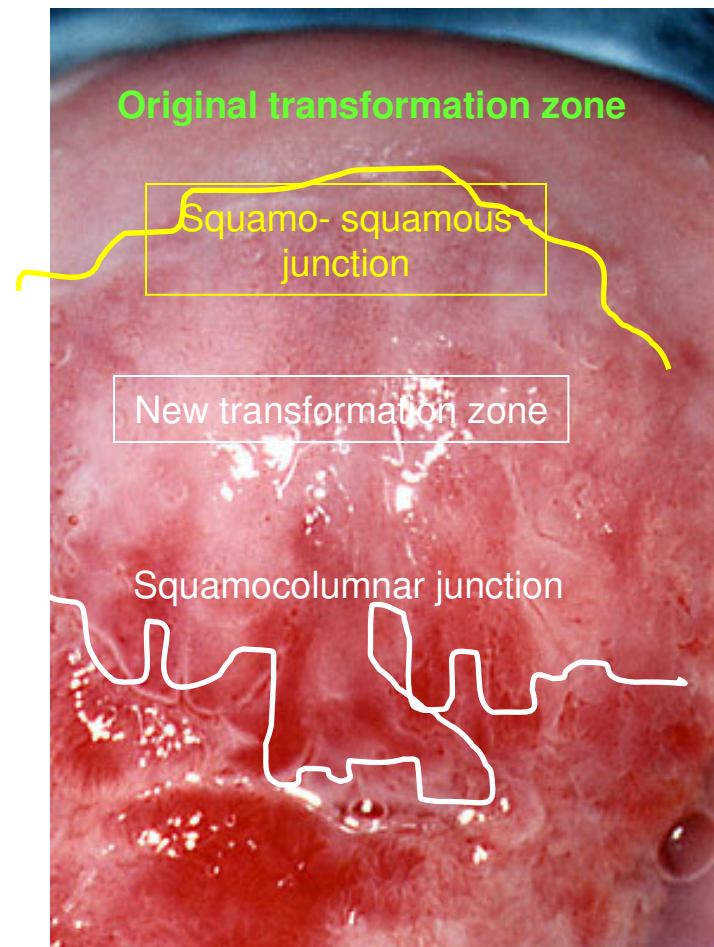
President of Croatian Society for Colposcopy and
Cervical Pathology, CMA

Head of OB/GYN Clinic in University Hospital *Sisters of
Charity* in Zagreb, Vinogradska 29, Croatia

www.kbsm.hr/kolposkopija
ginekologija@kbsm.hr

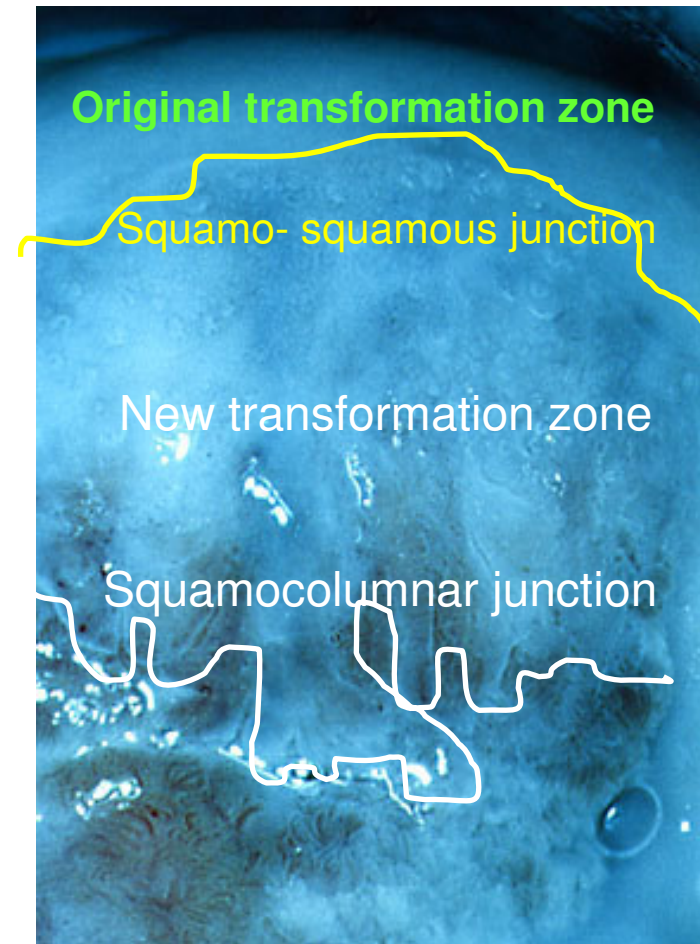
Transformation zone on the anterior lip of the uterine cervix

- Transformation zone on the anterior lip of the uterine cervix demonstrates:
- New squamocolumnar junction (*white scribble*), and the so-called squamo-squamous junction (*yellow scribble*)
- New transformation zone between *white and yellow scribble*
- Primordial transformation zone at the periphery of the anterior lip (*green letters*)
- New squamocolumnar junction arises from pluripotent cells of the basal layer of cervical epithelial coat, as a result of permanent external irritation i.e. Inflammatory agents, HPV infection, etc.



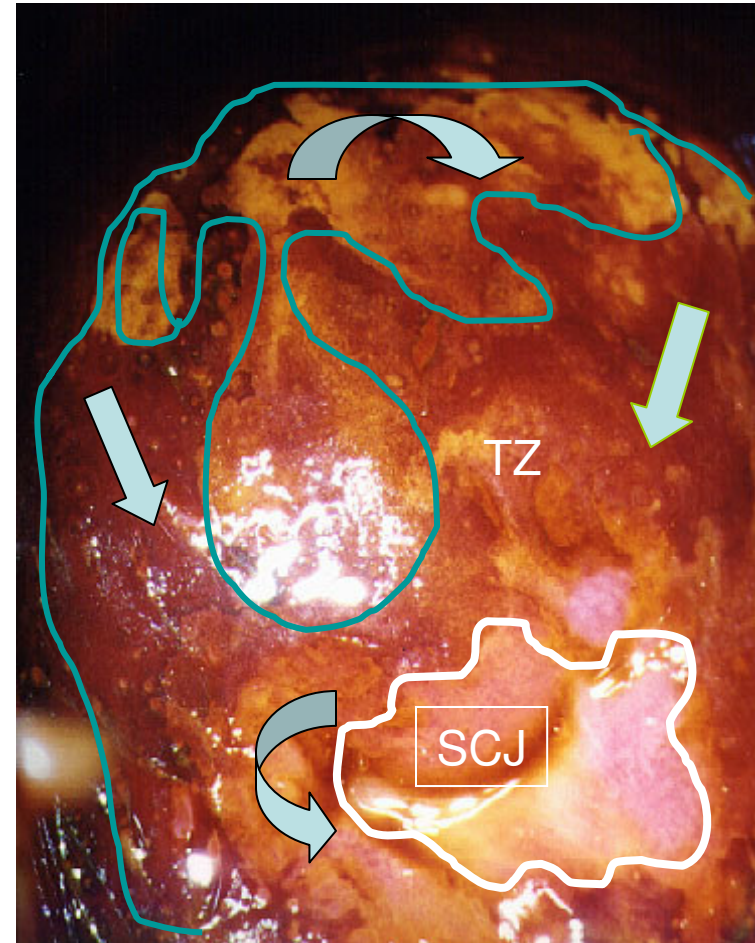
Transformation zone on the anterior lip of the uterine cervix- Kraatz green filter

- Transformation zone on the anterior lip of the uterine cervix demonstrates:
- New squamocolumnar junction (*white scribble*), and the so-called squamo-squamous junction (*yellow scribble*)
- New transformation zone between *white* and *yellow scribble*
- Primordial transformation zone at the periphery of the anterior lip (*green letters*)
- New squamocolumnar junction arises from pluripotent cells of the basal layer of cervical epithelial coat, as a result of permanent external irritation i.e. inflammatory agents, HPV infection, etc.



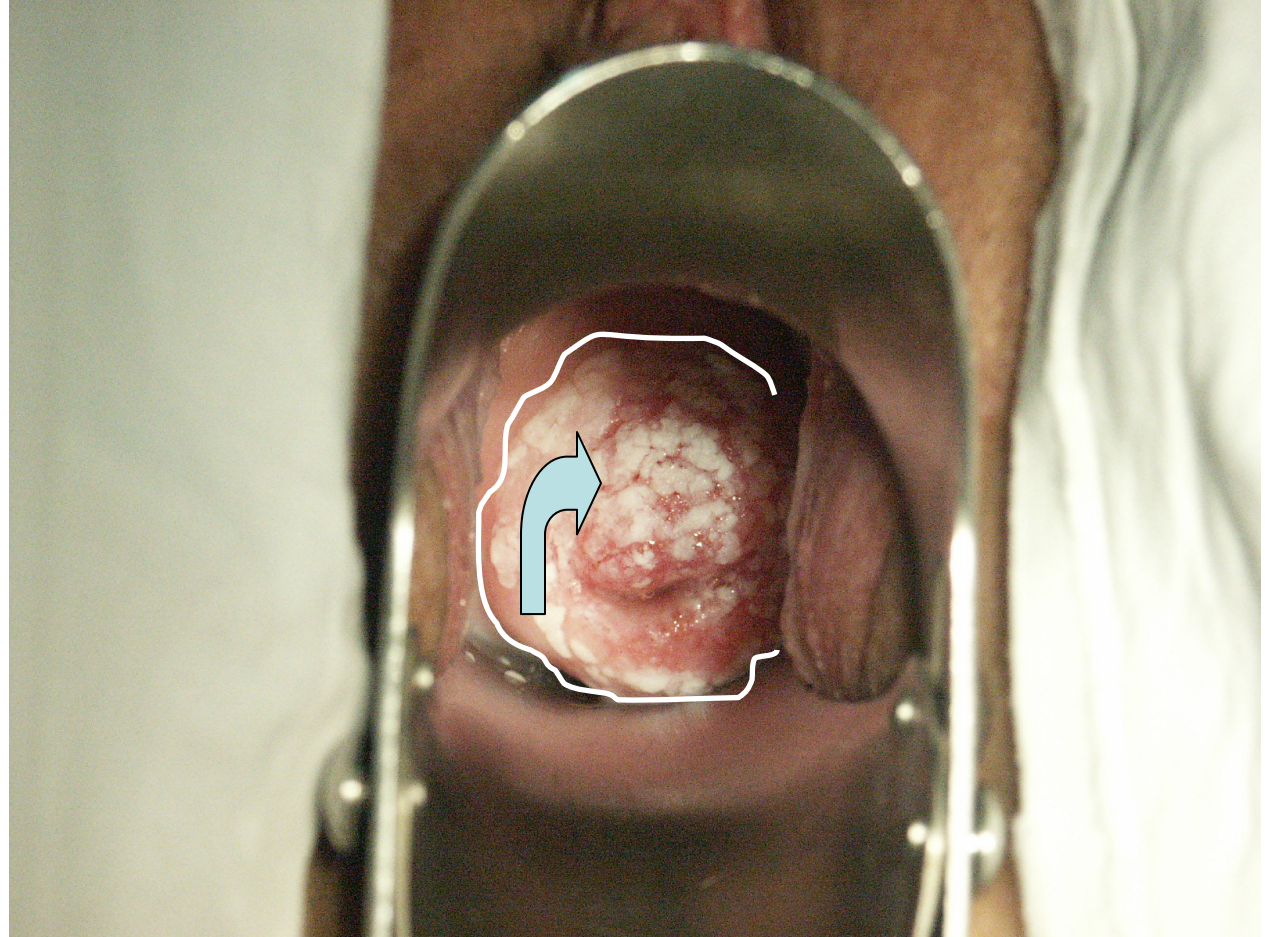
What can we see with Schiller's test?

- SCJ visible (*curved right arrow*)
- In TZ (Transformation Zone) of the anterior lip of the uterine cervix areas with mildly captured iodine may represent metaplastic pluristratified epithelium (*curved down arrow*), while dark captured epithelium (*down arrow on right and down arrow on left*) may represent original squamous epithelium. Here the ever-present question arises of the importance of Schiller's iodine test.



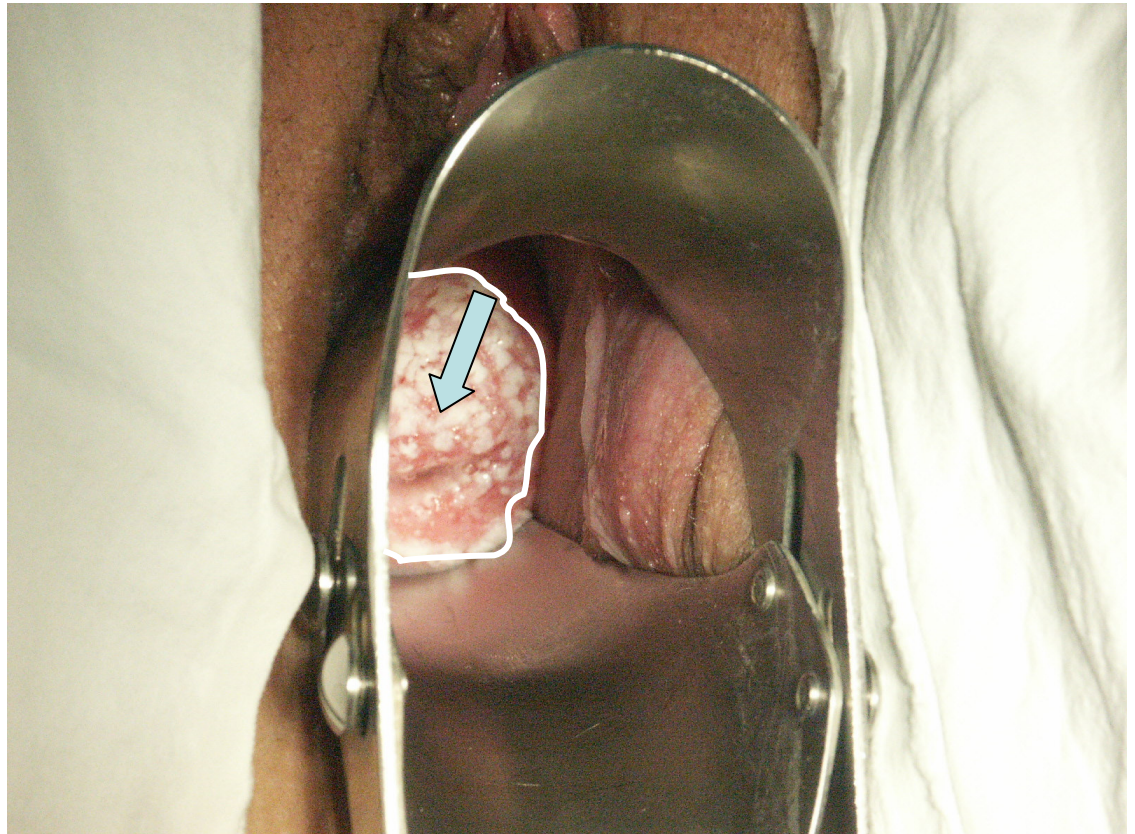
Nulliparous woman, 23 years old, with speculoscopic pattern of large coarse and confluent acetowhite areas

- ***Bent arrow demonstrates a coarse area of acetowhitening, fully visible to the naked eye, with highly suspected HPV infection. Pathohistology on punch biopsy revealed CIN II and koilocytosis. LETZ was the selected therapy.***



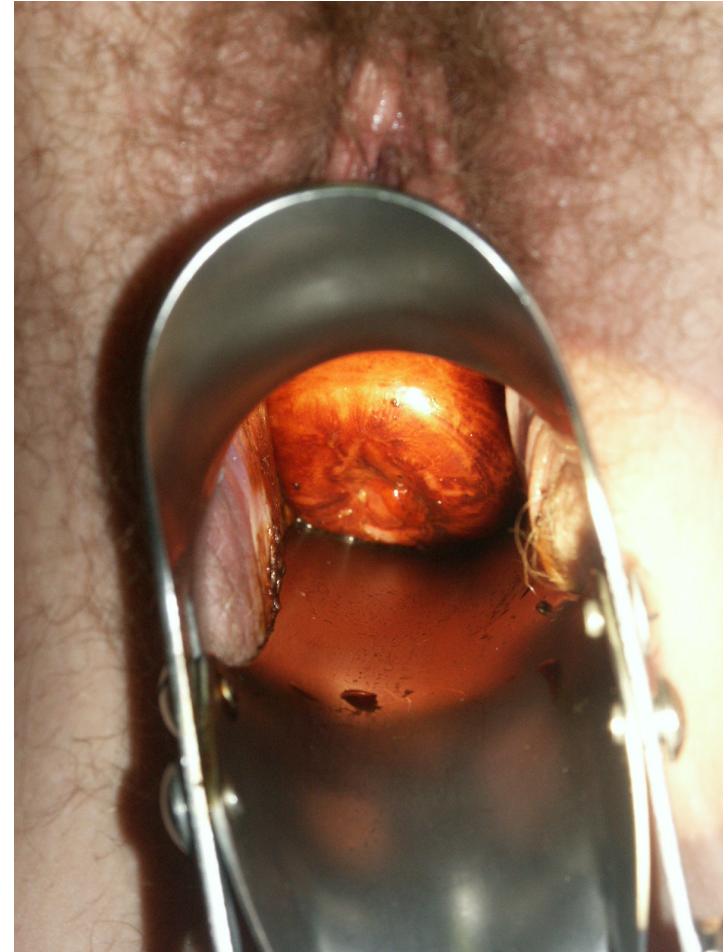Nulliparous woman, 23 years old, with speculoscopic pattern of large coarse and confluent acetowhite areas

- **The same patient, but better visibility of the left half of the uterine cervix.**
Down arrow demonstrates a coarse area of acetowhitening, fully visible to the naked eye, with highly suspected HPV infection. Pathohistology on punch biopsy revealed CIN II and koilocytosis. LETZ was the selected therapy.



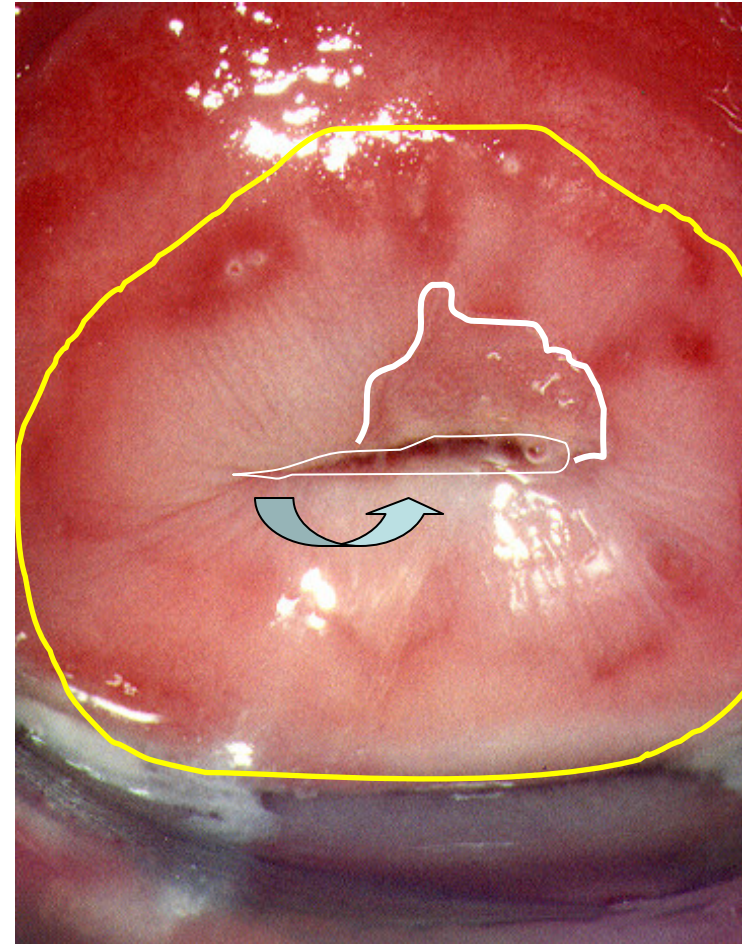
Schiller's test and speculoscopy

- Thanks to speculoscopy it is possible to see the shape of the uterine cervix, gain visibility of SCJ, as well as iodine captation, but colposcopy is inevitable for a precise analysis of this surface.



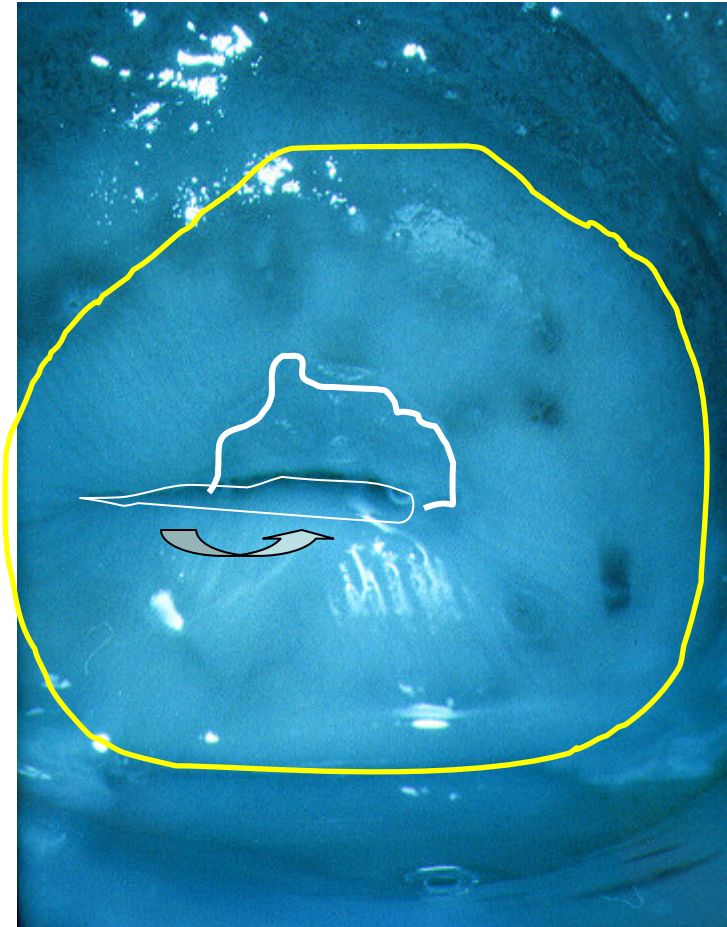
Portio suspecta. Status post coagulationem sec. Semm.
*Suspected finding on uterine portio two years after
Semm's cold coagulation*

- *SCJ visible (curved up arrow), as well as some slight acetowhitening from 12 to 3 o'clock area, there is also a radial pattern characteristic of thermal treatment of the uterine portio surface*



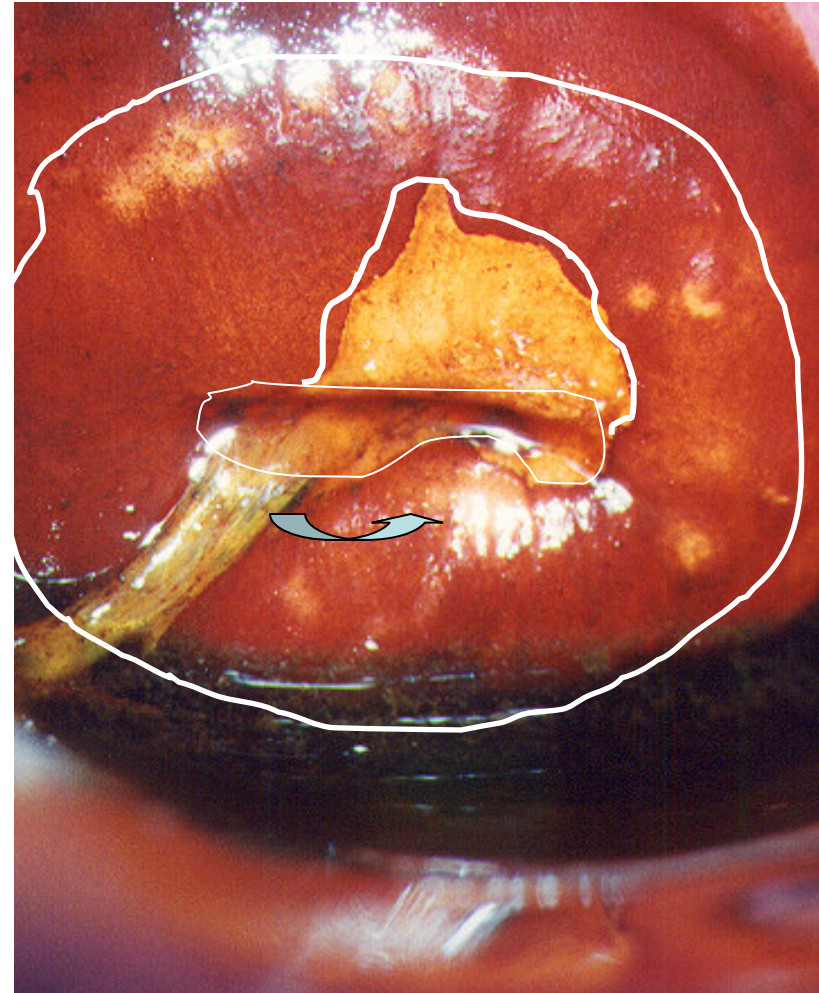
Portio suspecta. Status post coagulationem sec. Semm.
*Suspected finding on uterine portio two years after
Semm's cold coagulation*

- *SCJ visible
(curved up arrow),
as well as some
slight
acetowhitening
from 12 to 3
o'clock area, there
is a radial pattern
characteristic of
thermal treatment
of the uterine
portio surface*



Portio suspecta. Status post coagulationem sec. Semm.
*Suspected finding on uterine portio two years after
Semm's cold coagulation*

- SCJ visible (*curved up arrow*), as well as some slight acetowhitening from 12 to 3 o'clock area, **iodine negative area**, there is a radial pattern characteristic of thermal treatment of the uterine portio surface



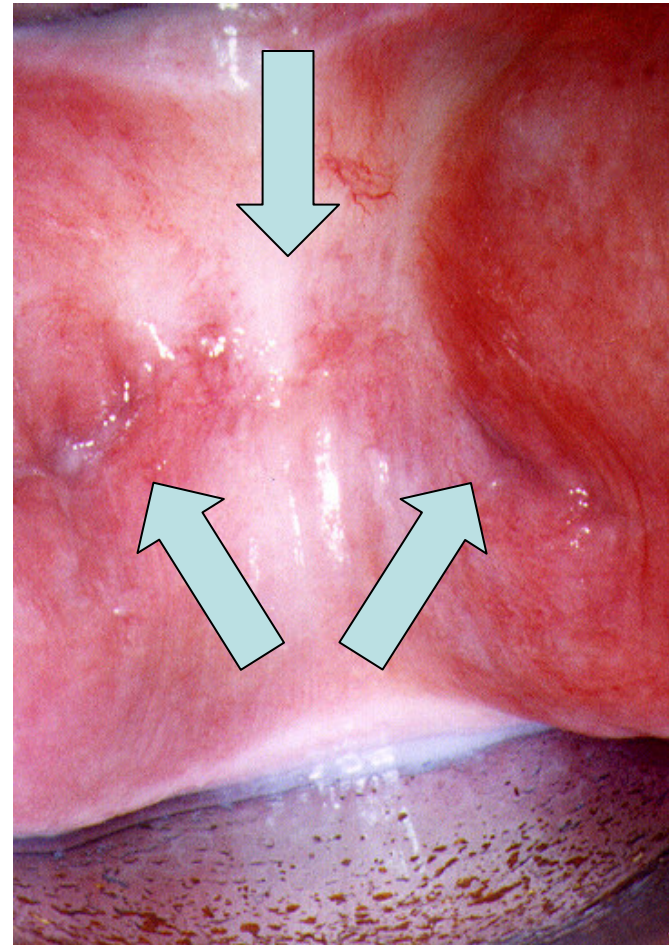
Further treatment?

- Excochleatio canalis cervicis et excisio probatoria cervicis

- Endocervical curettage and punch biopsy from iodine negative area

Difficulties in posthysterectomic cuff colposcopy

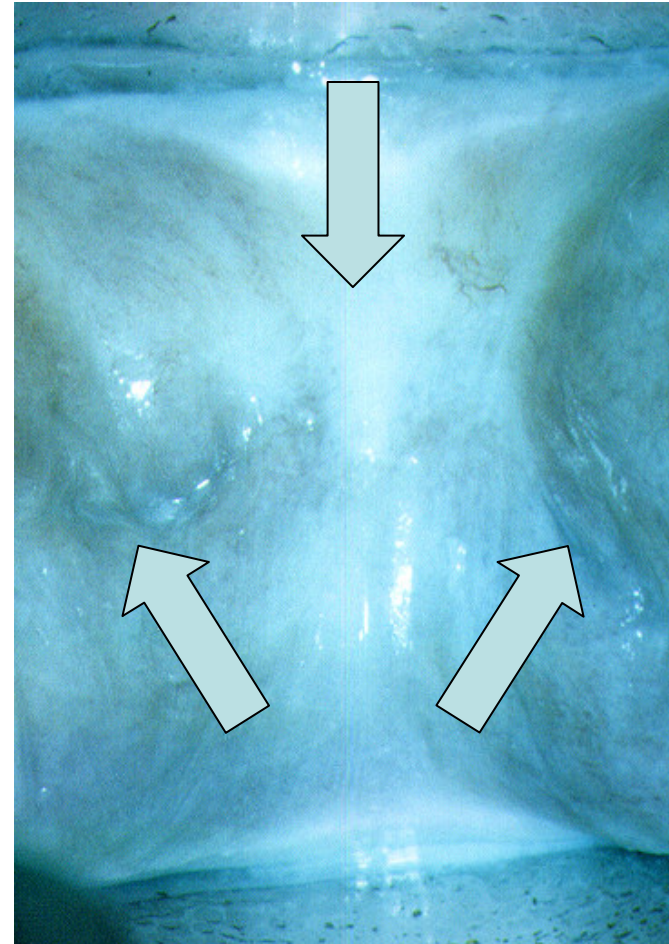
- The difficulty in posthysterectomic vaginal cuff colposcopy lies in incomplete colposcopy. It is possible to perform colposcopy of the middle of the vaginal cuff (*down arrow*), but the lateral “angle” (the so-called “dog's ears”) (*up arrows*) must be visualised by Kogan's speculum insertion. If this is difficult to perform, then it is advised to apply cytobrush from every angle, separately on its own glass.



Difficulties in posthysterectomic cuff colposcopy

- **KRAATZ GREEN LIGHT**

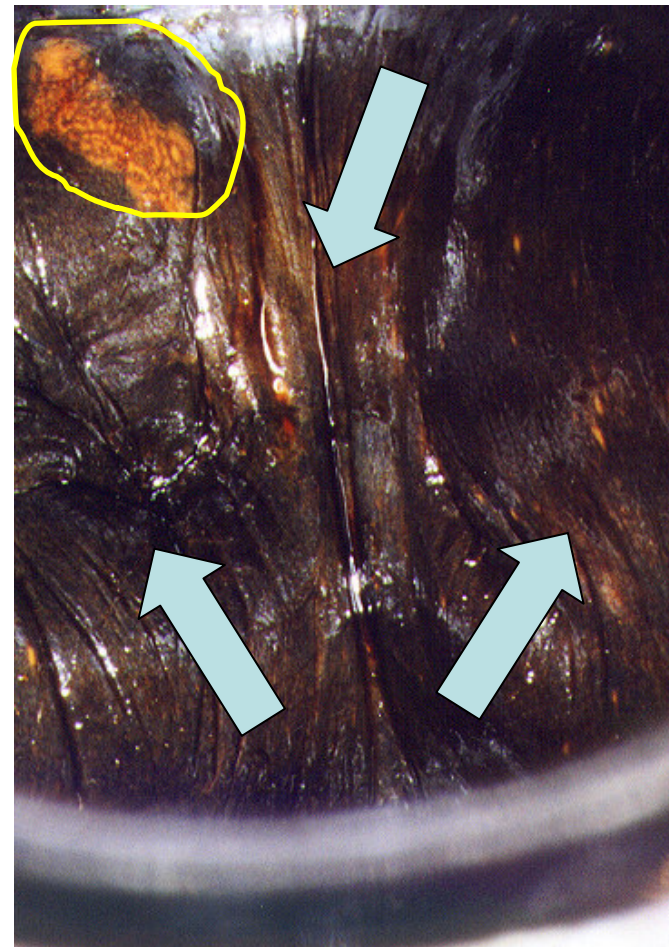
The difficulty in posthysterectomic vaginal cuff colposcopy lies in incomplete colposcopy. It is possible to perform colposcopy of the middle of the vaginal cuff (*down arrow*), but the lateral “angle” (the so-called “dog's ears”) (*up arrows*) must be visualised by Kogan's speculum insertion. If this is difficult to perform, then it is advised to apply cytobrush from every angle, separately on its own glass.



Difficulties in posthysterectomic cuff colposcopy

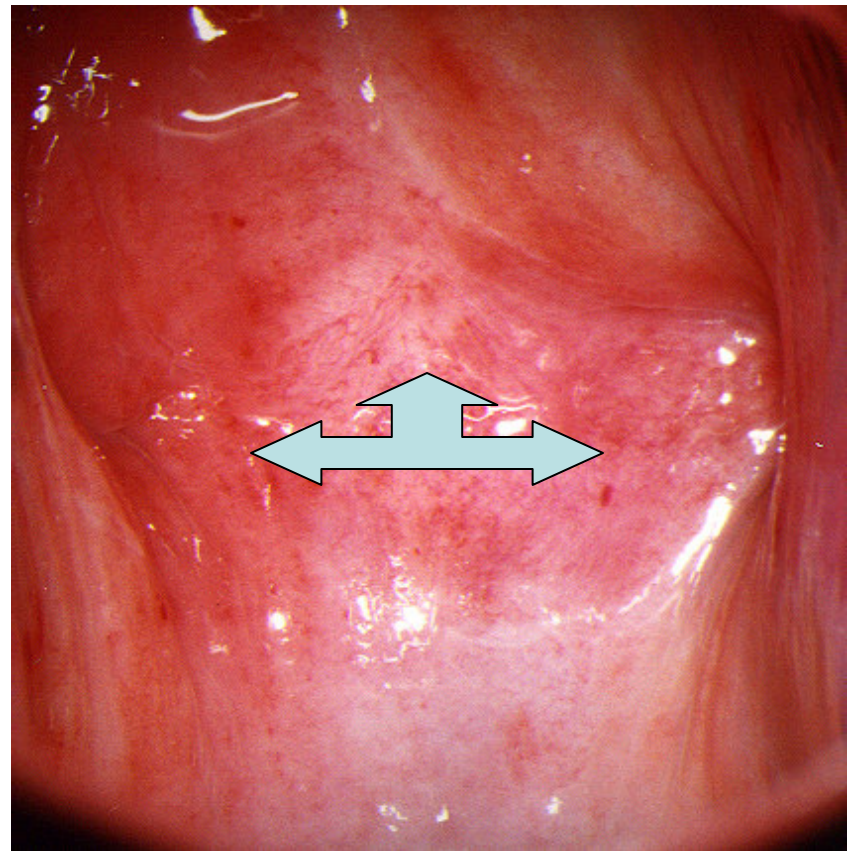
- **IODINE TEST (SCHILLER' S)**
Difficulty in posthysterectomic vaginal cuff colposcopy lies in incomplete colposcopy. It is possible to perform colposcopy of the middle of the vaginal cuff (*down arrow*), but the lateral “angle” (the so-called “dog's ears”) (*up arrows*) must be visualised by Kogan's speculum insertion. If this is difficult to perform, then it is advised to apply cytobrush from every angle, separately on its own glass.

Thanks to Schiller's test, iodine negative area near the right vaginal angle is visible, histology findings revealed VAIN I.



Difficulties in posthysterectomic cuff colposcopy (hypoestrinaemic state as the cause)

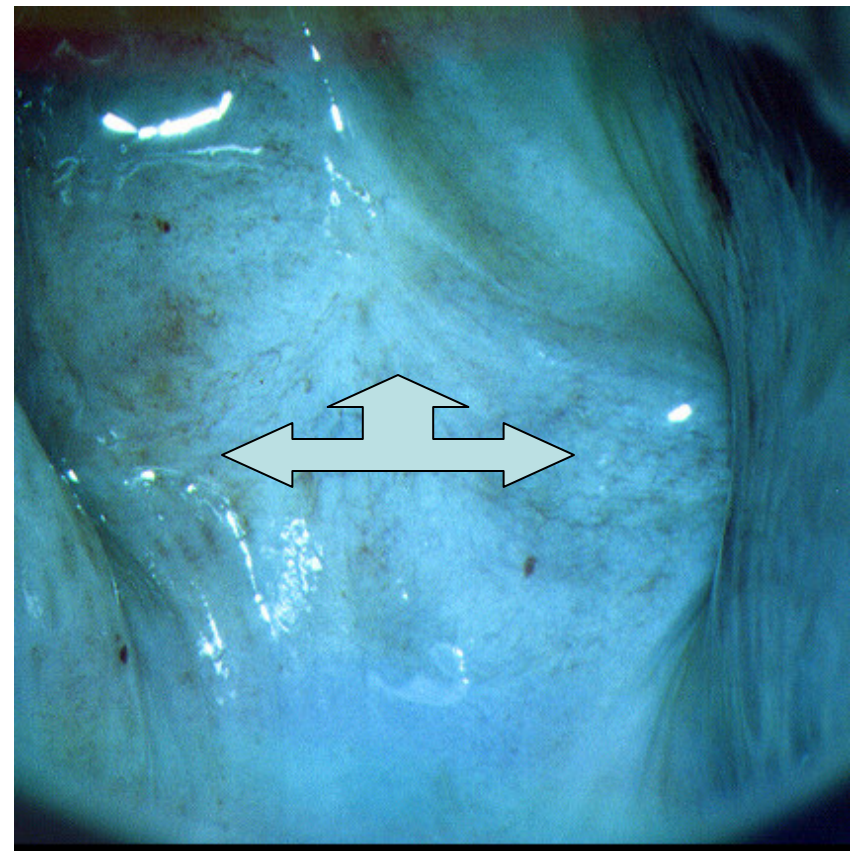
- *Hypoestrinaemic state results in thin vaginal mucous layer, as well as in posthysterectomic cuff (left right up arrow). It results in difficulties in interpretation of colposcopic investigation of posthysterectomic cuff, so it is necessary to introduce local epithelising therapy.*



Difficulties in posthysterectomic cuff colposcopy

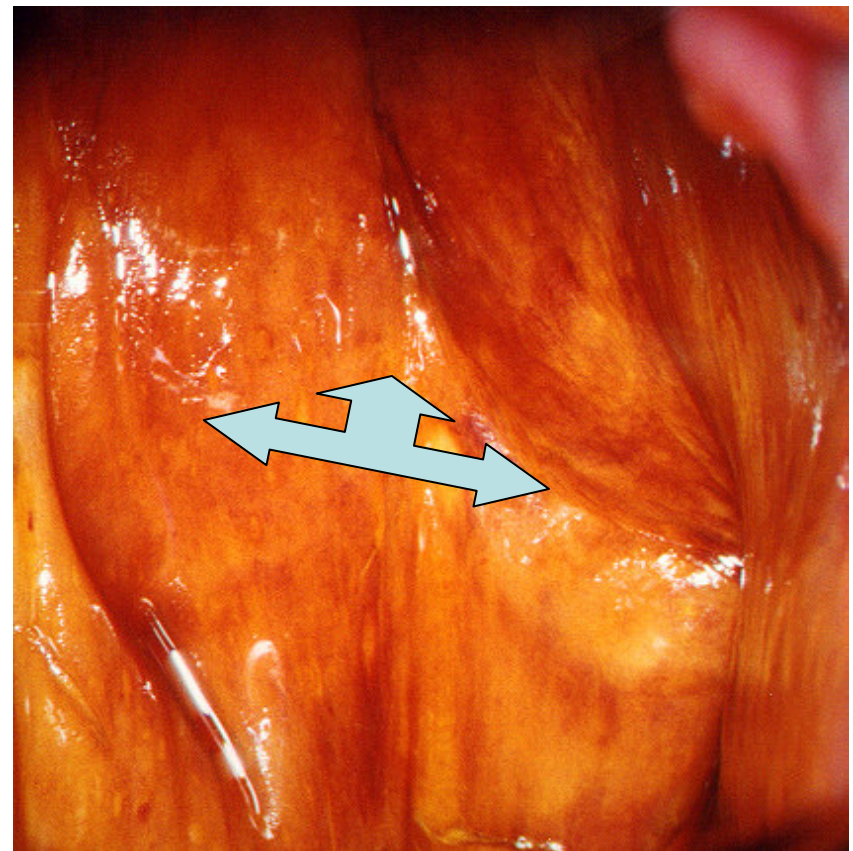
- **GREEN LIGHT** due to **KRAATZ**

*Vascular pattern shows thin rare capillaries.
Hypoestrinaemic state results in thin vaginal mucous layer, as well as in posthysterectomic cuff (left right up arrow). It results in difficulties in interpretation of colposcopic investigation of posthysterectomic cuff, so it is necessary to introduce local epithelising therapy.*



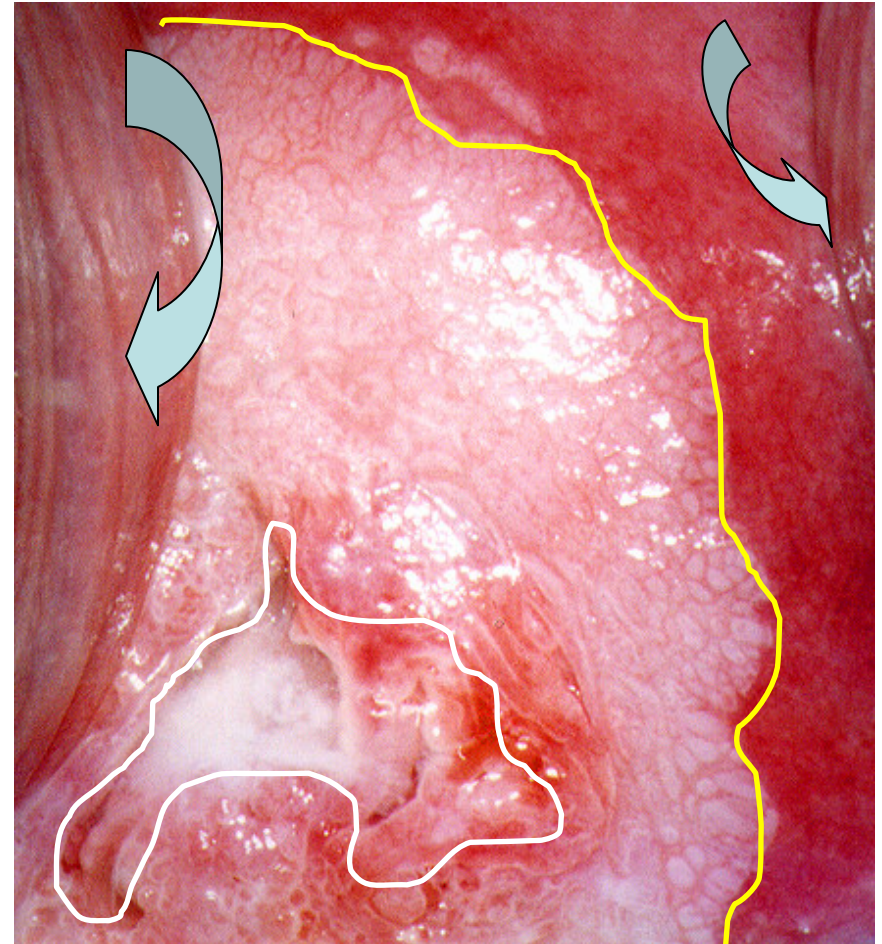
Difficulties in posthysterectomic cuff colposcopy

- **IODINE TEST (SCHILLER' S)**
Weak inhomogenous iodine capture. Hypoestrinaemic state results in thin vaginal mucous layer, as well as in posthysterectomic cuff (left right up arrow). It results in difficulties in interpretation of colposcopic investigation of posthysterectomic cuff, so it is necessary to introduce local epithelising therapy.



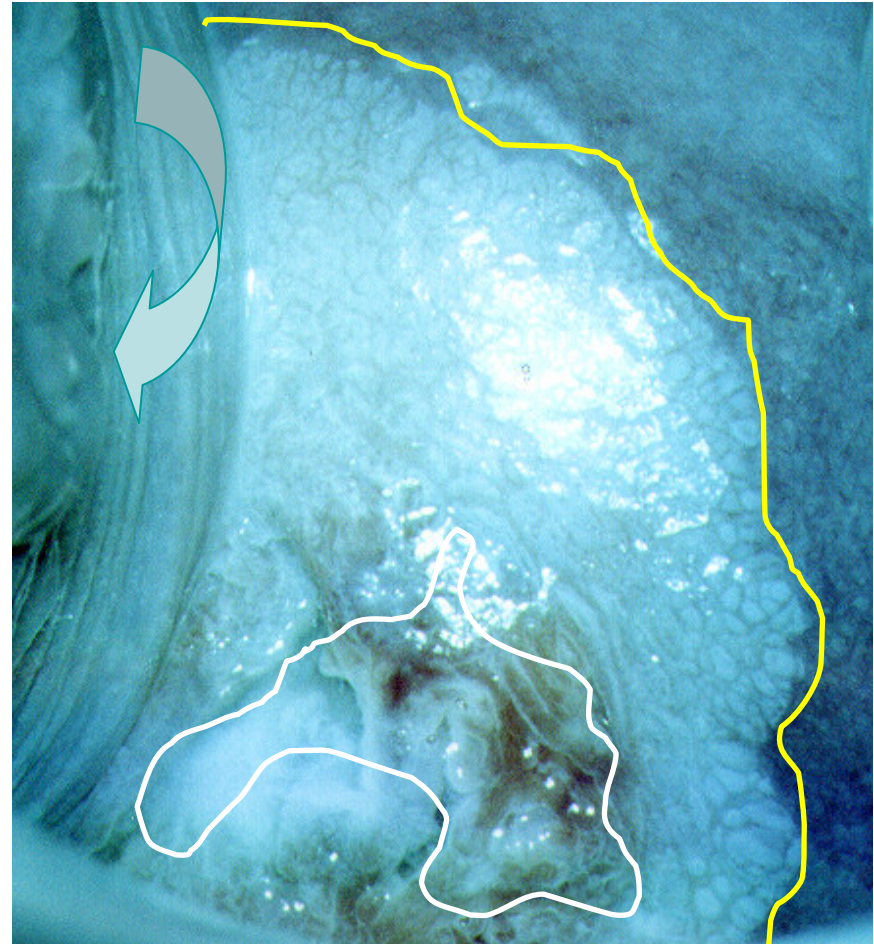
Colposcopy in pregnancy - normal light

- A 23-week pregnant woman, cytology showing CIN II, SCJ is fully visible (*white scribble*), there is a coarse mosaic in TZ (*area between white and yellow scribble*), and a characteristic protrusion of vaginal vaults (*curved right and left arrow*)



Colposcopy in pregnancy - Kraatz green filter

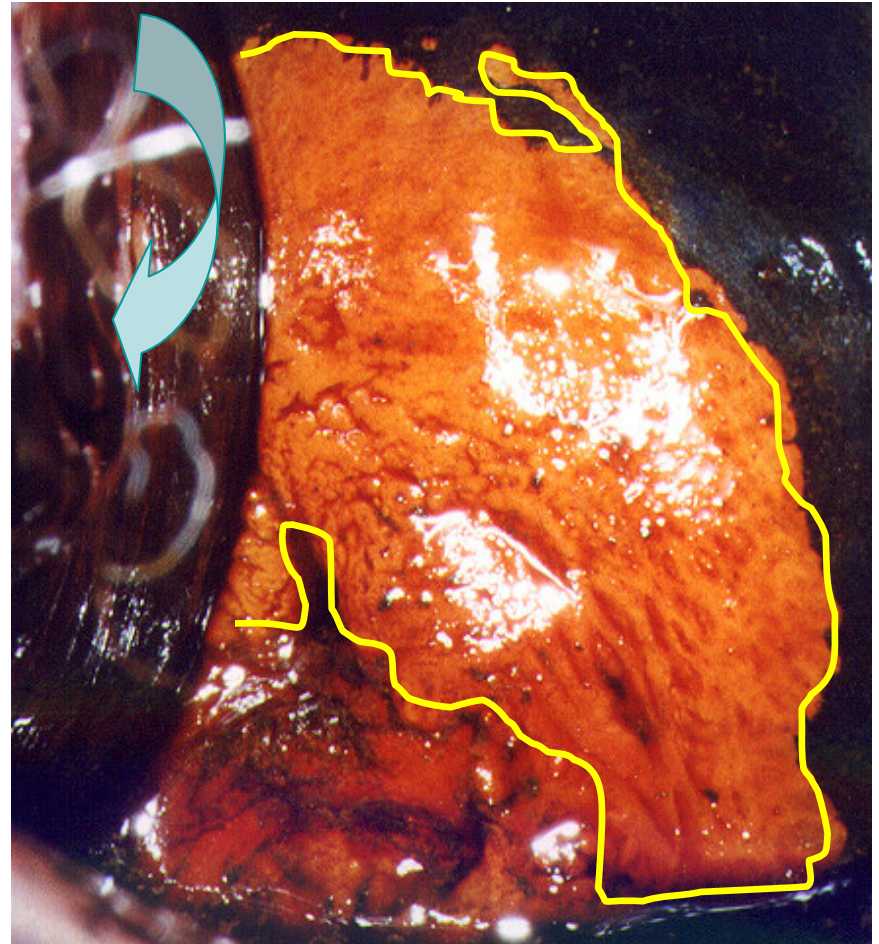
- A 23-week pregnant woman, cytology CIN II, HPV positive, SCJ (white scabrous), white scabrous, bare is TZ (cornea between white and yellow scabrous), and yellow scabrous, protrusion of vaginal vaults (curved left arrow) (curved left arrow)



Colposcopy in pregnancy - Schiller's iodine test

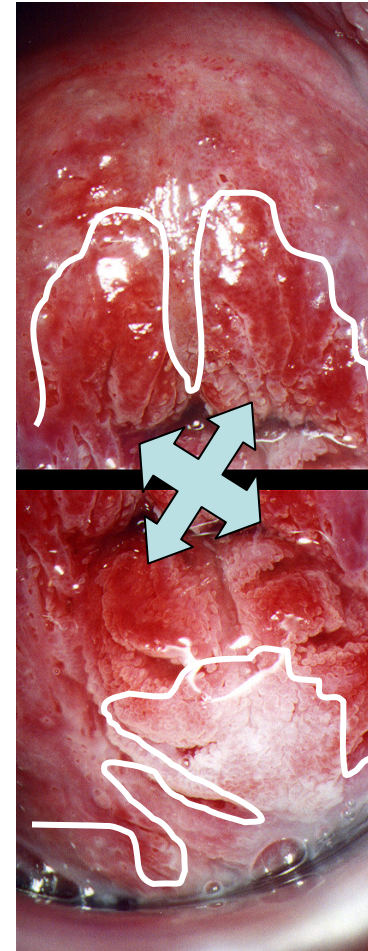
- A 23-week pregnant woman, cytology showing CIN II, with a coarse iodine negative, Schiller's positive area (*yellow scribble border*), and a characteristic protrusion of vaginal vaults

(curved left arrow)



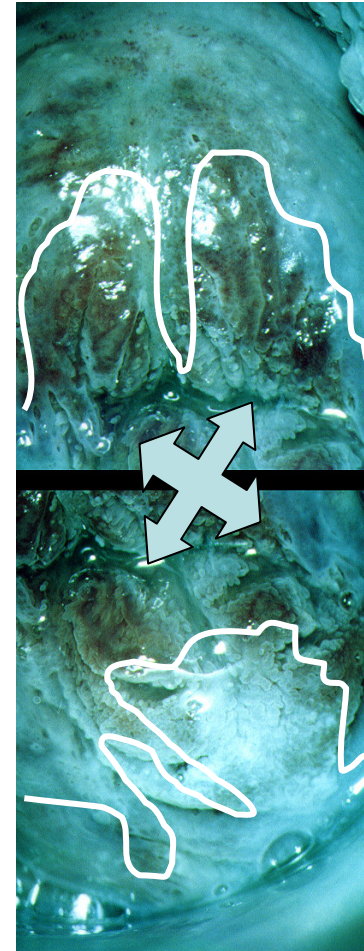
Colposcopy in pregnancy - normal light

- Another pregnant woman, cytology showing CIN II, speculoscopy revealed hypertrophic, polypoid portio (*quad arrow*), colposcopy coarse acetowhitening, both on the anterior and the posterior lip, SCJ is fully visible (*white scribble*)



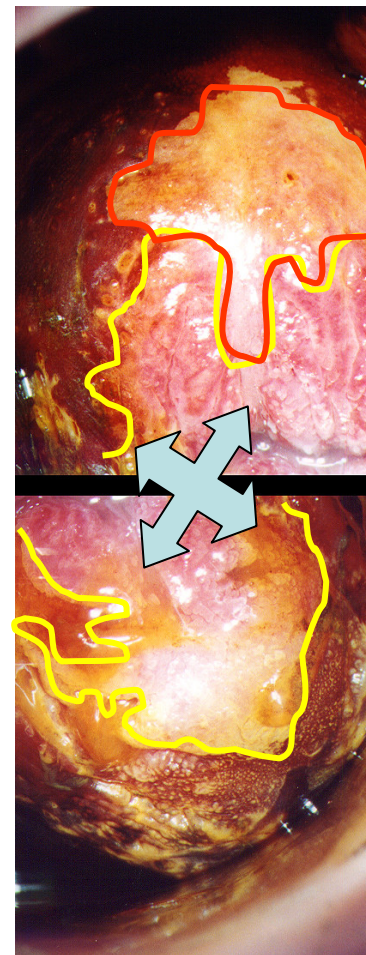
Colposcopy in pregnancy - Kraatz green filter

- Another pregnant woman, cytology showing CIN II, speculoscopy revealed hypertrophic, polypoid portio (*quad arrow*), colposcopy coarse acetowhitening, both on the anterior and the posterior lip, SCJ is fully visible (*white scribble*)



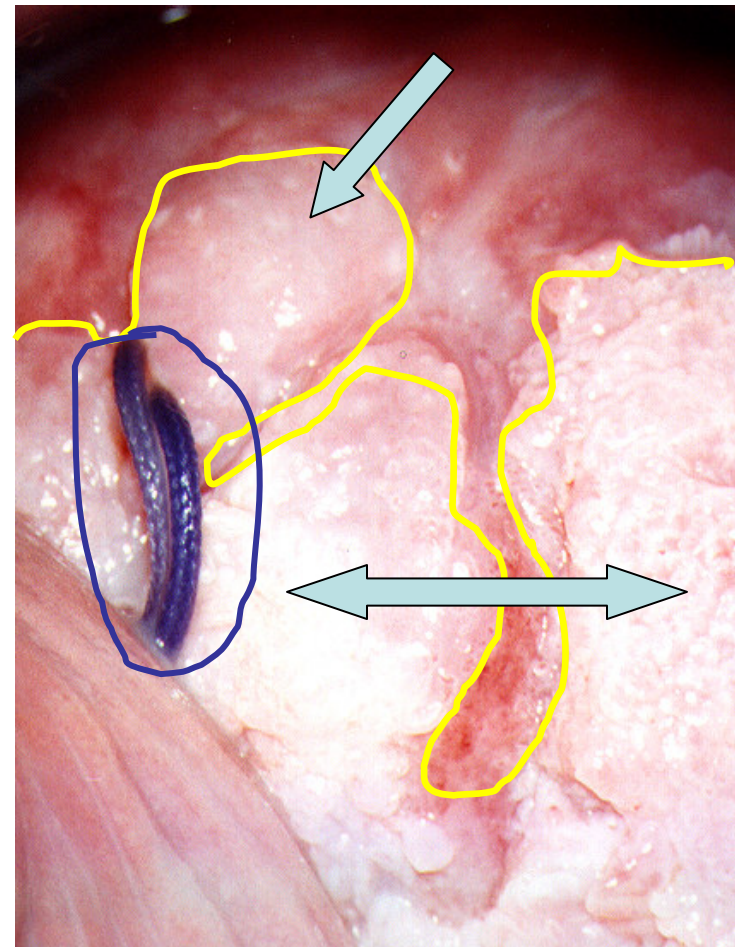
Colposcopy in pregnancy - Schiller's iodine test

- Another pregnant woman, cytology showing CIN II, speculoscopy revealed hypertrophic, polypoid portio (*quad arrow*), colposcopy coarse acetowhitening, both on the anterior and the posterior lip, SCJ is fully visible (*white scribble*), iodine negative areas well-demarkated on the anterior lip (*red scribble*)



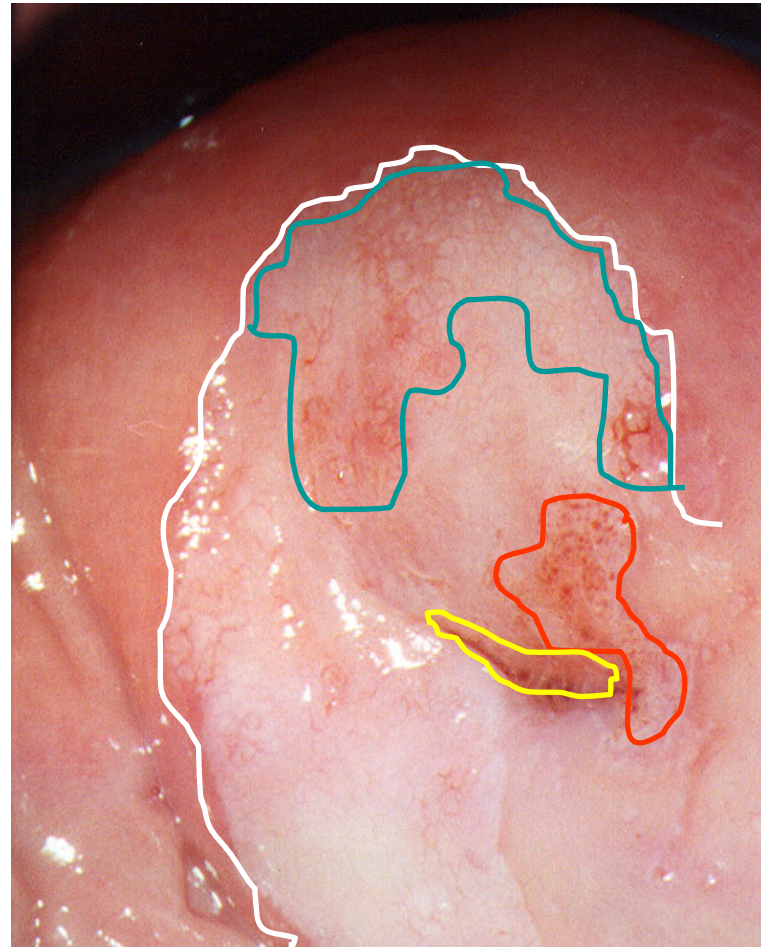
Colposcopy in pregnancy - normal light

- Hyperplastic keratotic oedematous area of the anterior lip of the uterine portio in a 24-week pregnant woman (*left right and down arrow*), cytology showed HGSIL, and motivated me to perform target biopsy, although I really rarely perform biopsies in pregnancy. Histology revealed CIN II, healing was satisfactory (*haemostatic Vicryl suture - blue scribble*), as well as the outcome of the pregnancy.



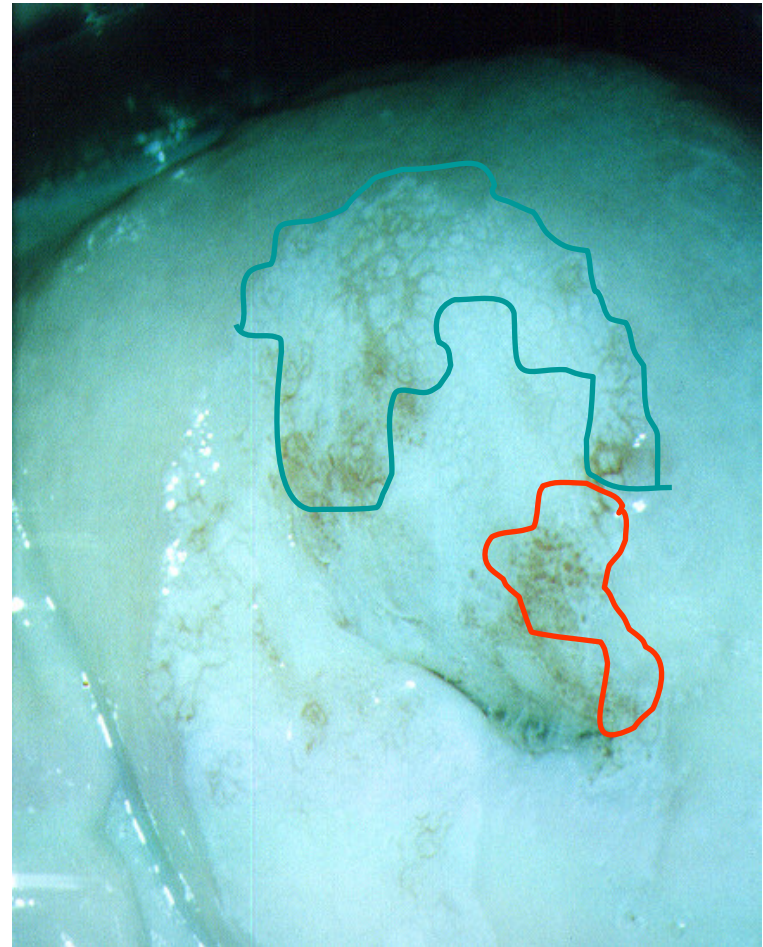
Slight acetowhitening of the uterine portio

- SCJ is fully visible (*yellow scribble*), a large area of slight acetowhitening (*white scribble*), a mosaic pattern (*blue scribble*) and punctation (*red scribble*)



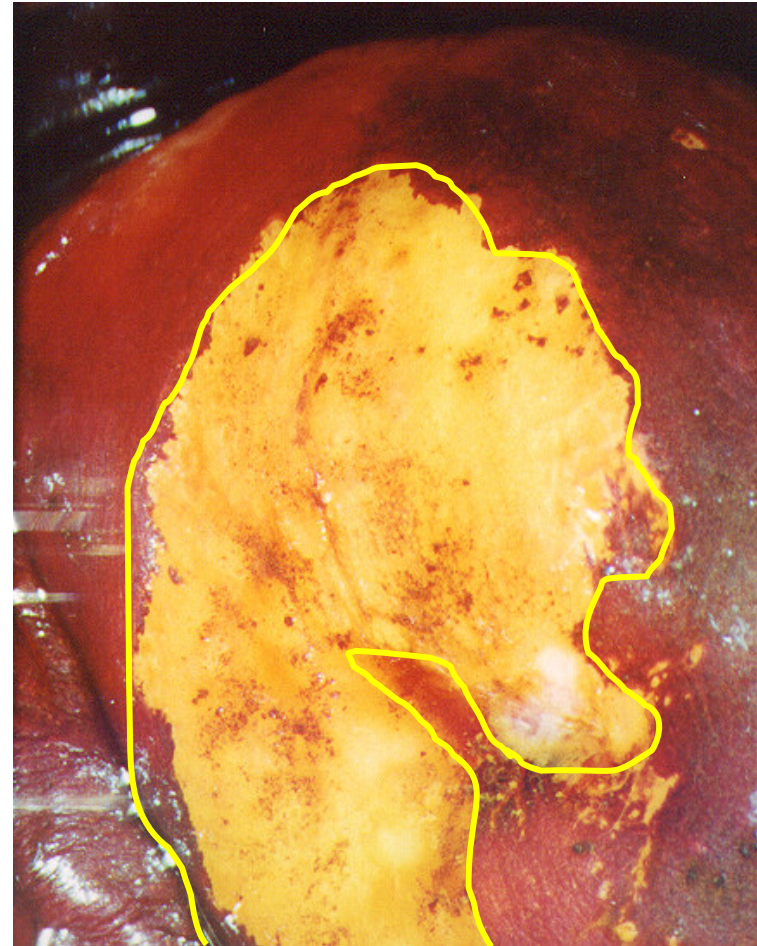
Slight acetowhitening of the uterine portio

- Kraatz green light enables a better visualisation of the mosaic (*blue scribble*) as well as punctation patterns (*red scribble*)



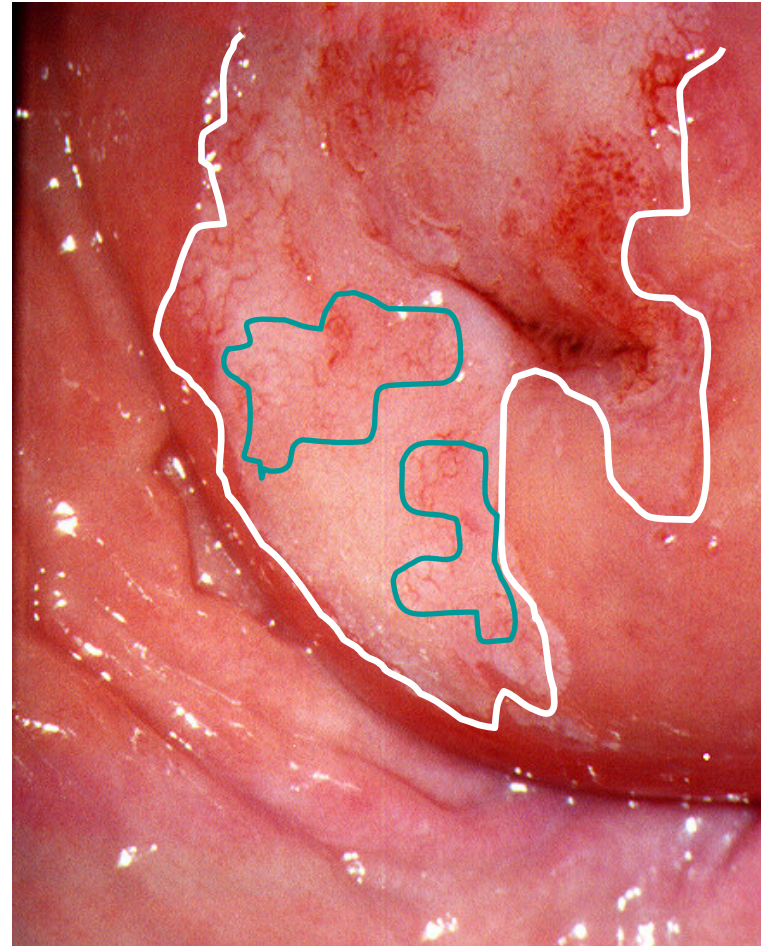
Schiller's test (the same patient)

- A well-demarcated iodine negative area contains both mosaic and punctation areas



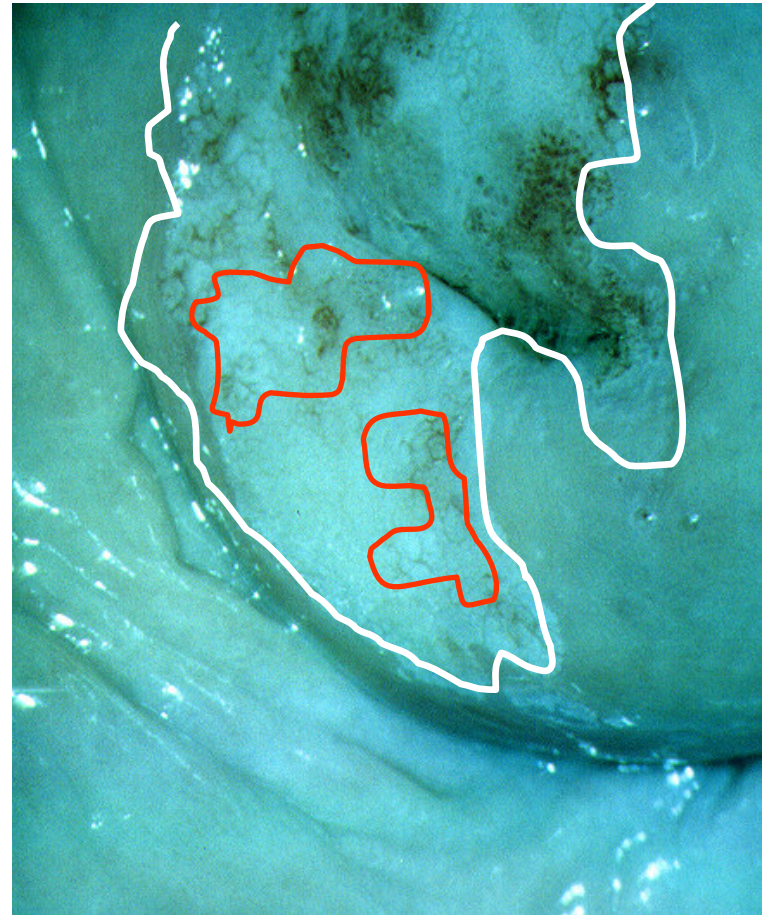Slight acetowhitening of the uterine portio

- The same patient, acetowhite area (*white scribble*) continues to extend onto the posterior lip, where slight mosaic patterns are visible (*blue scribble*)



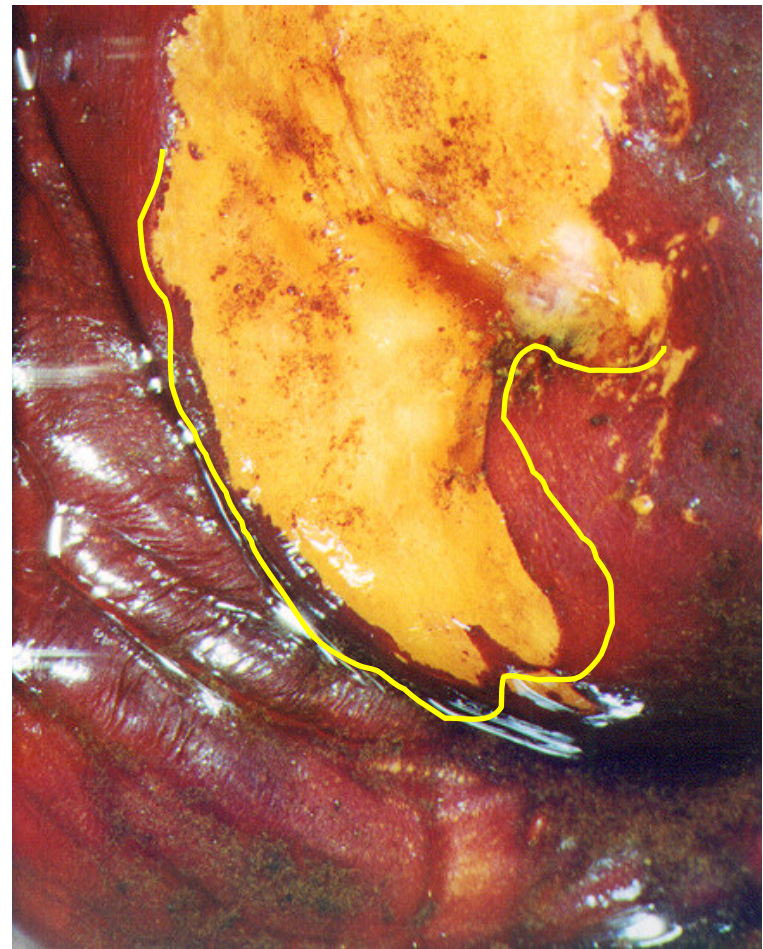
Slight acetowhitening of the uterine portio

- The same patient, acetowhite area (*white scribble*) continues to extend onto the posterior lip, where slight mosaic patterns are visible (*red scribble*)



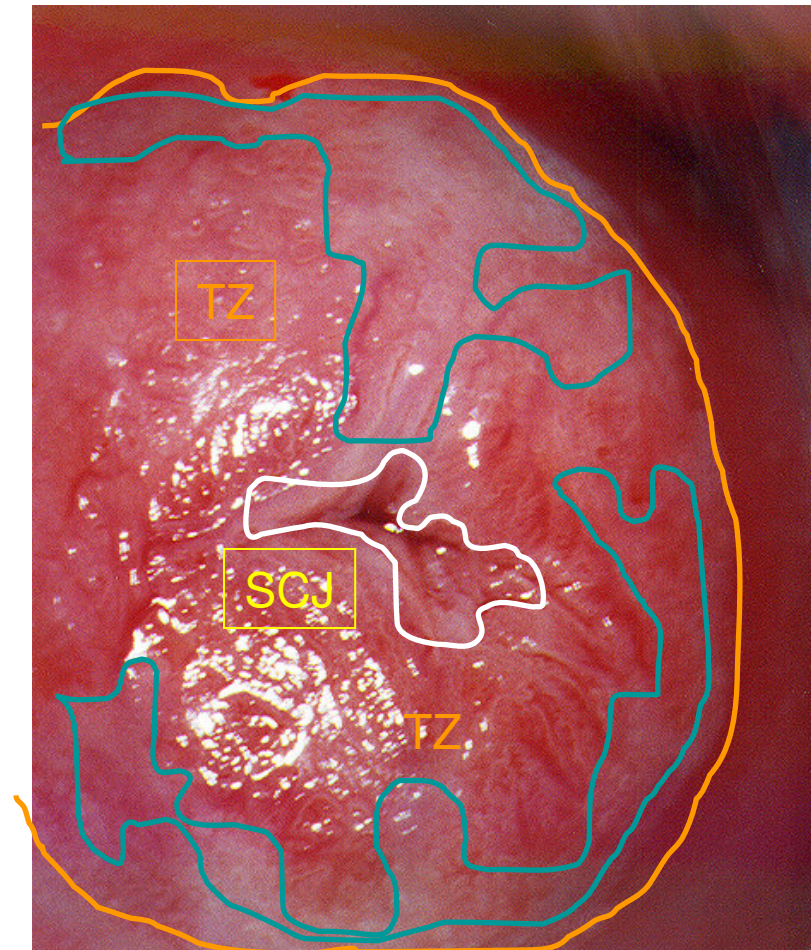
Schiller's test (the same patient)

- A well-demarcated iodine negative area of the posterior lip, containing the mosaic areas that have been previously mentioned



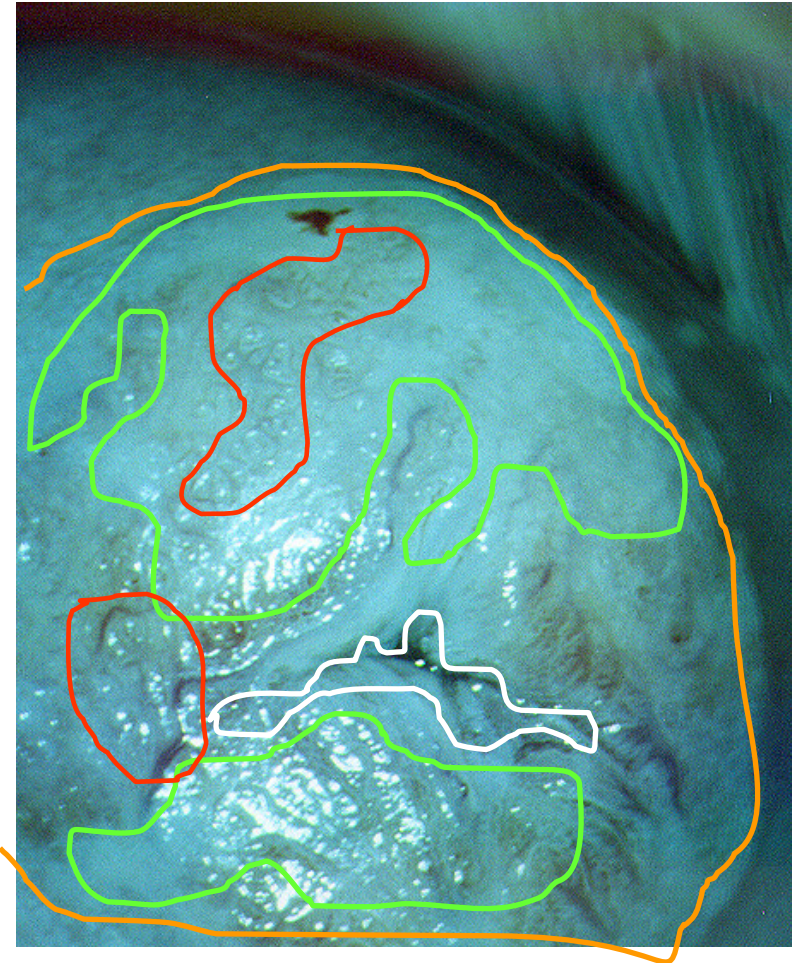
Uterine portio with huge eversion of the TZ (transformation zone)

- SCJ near the external orifice of the uterine cervix (*white scribble*) and in TZ (*between white and orange scribble*), multiple shaped acetowhite areas indicating HPV presence (*green-blue scribble*)



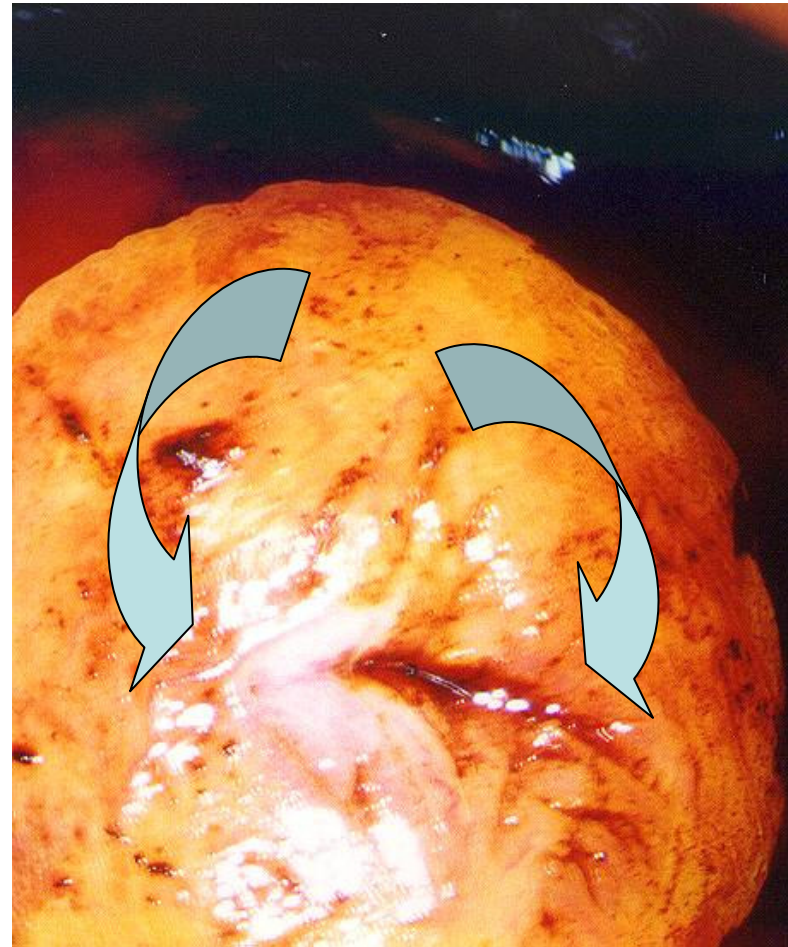Uterine portio with huge eversion of the TZ (transformation zone) - Kraatz green light

- Kraatz green light allows for better visibility of acetowhite areas (*light green scribble*) and abnormal vascular pattern (*red scribble*) of the pluristratified squamous epithelium of the uterine portio



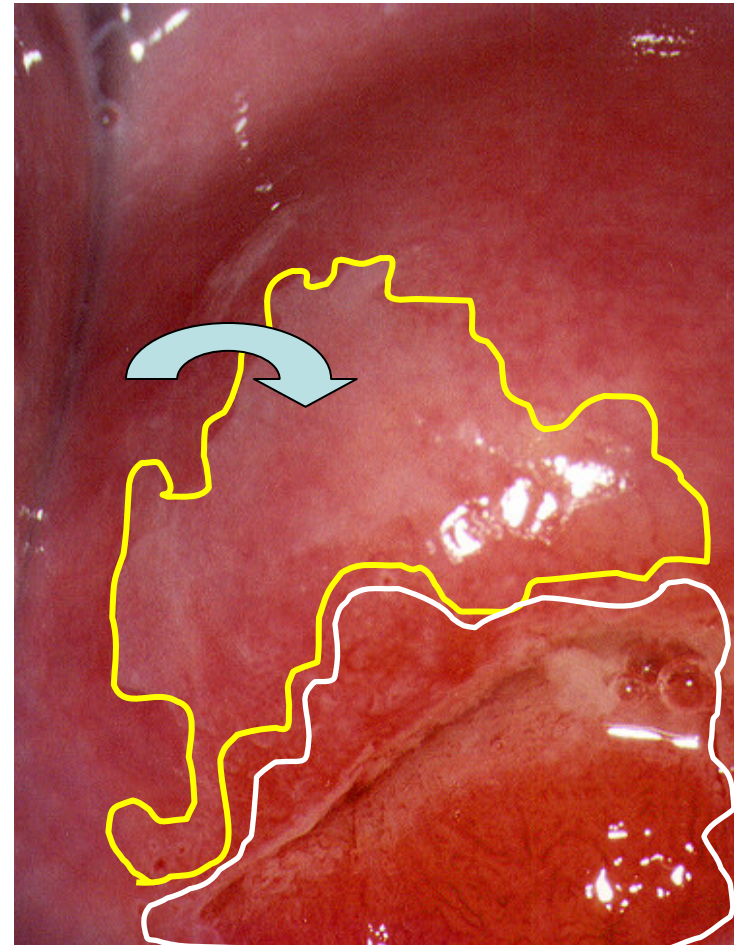
Uterine portio with huge eversion of the TZ (transformation zone) - Schiller's iodine test

- Both acetowhite areas as well as those with abnormal vascular pattern reveal a huge iodine negative area well-demarcated from the adjacent healthy pluristratified epithelium
(curved right and curved left arrow)



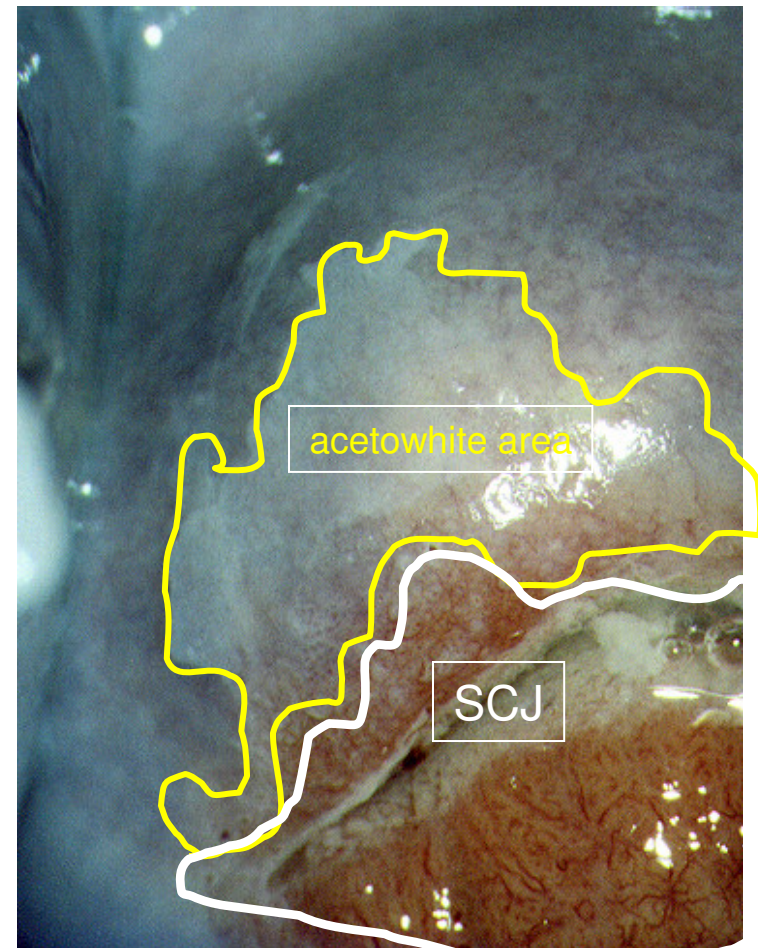
Slight acetowhitening of the anterior lip

- Slight acetowhitening of the anterior lip of the uterine portio (SCJ white scribble, acetowhitening margins yellow scribble, *circular arrow*)



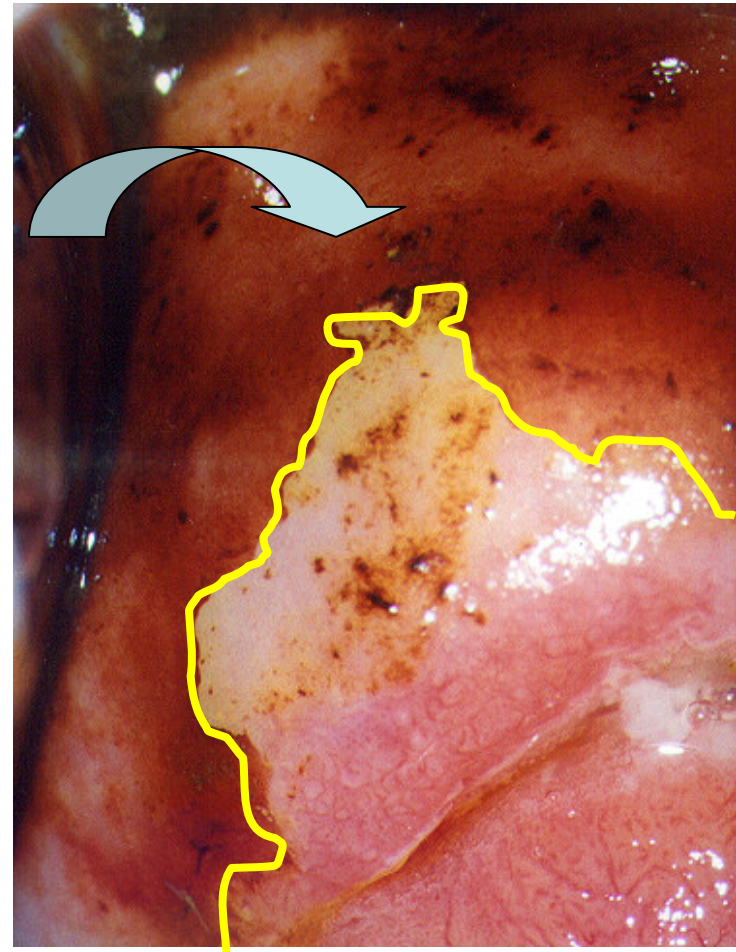
Slight acetowhitening of the anterior lip - Kraatz green filter

- Slight acetowhitening of the anterior lip (Kraatz green filter) demonstrates borders between the acetowhite area and SCJ (squamo-columnar junction)



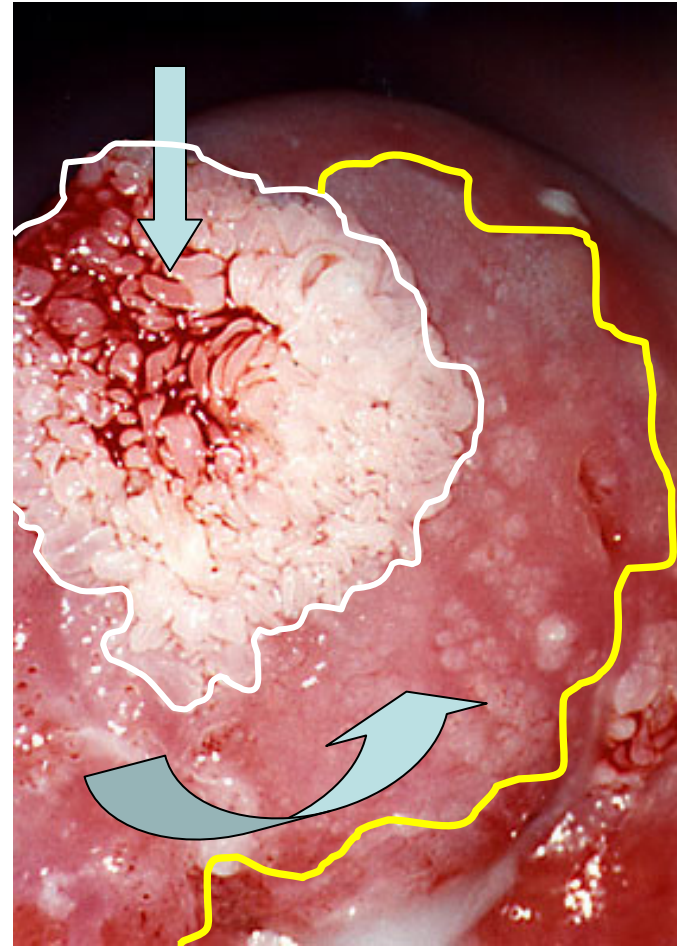
Slight acetowhitening of the anterior lip - Schiller's iodine test

- Schiller's iodine test of the slight acetowhite area on the anterior lip also demonstrates *(yellow scribble)* the demarcation from the adjacent healthy pluristratified epithelium of the uterine portio *(curved down arrow)*



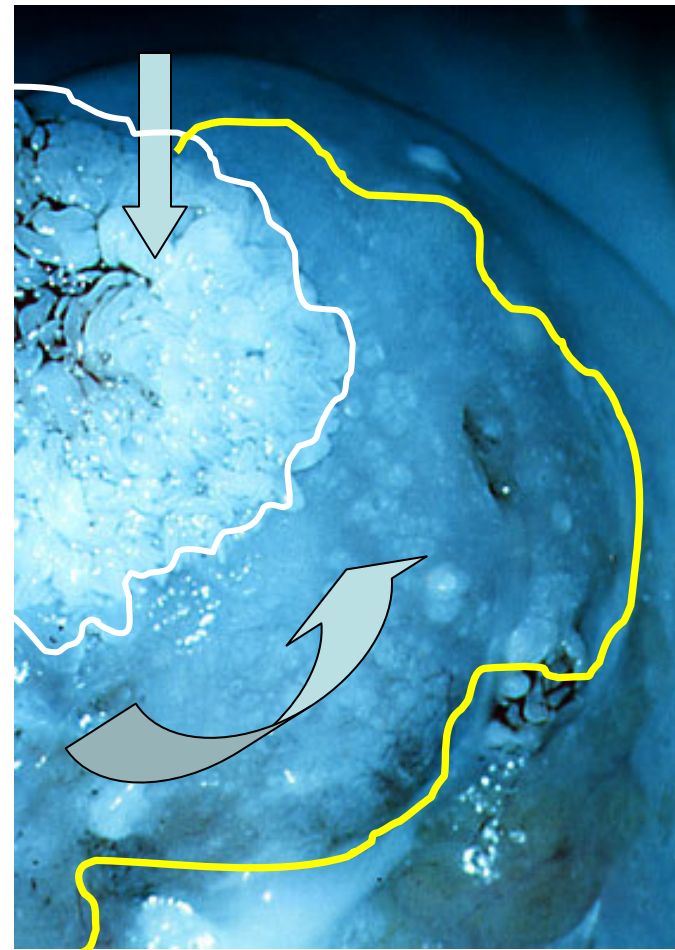Acetowhite papillary and hypertrophic pluristratified epithelium of the uterine portio

- Acetowhite papillary (*down arrow, white scribble*) and hypertrophic pluristratified epithelium of the anterior lip of the uterine portio (*curved up arrow, yellow scribble*), visible to the naked eye, HPV infection as a continuum. Pathohistology on LETZ verified papilloma exophyticum (*down arrow, white scribble*) and CIN III (*curved up arrow, yellow scribble*).



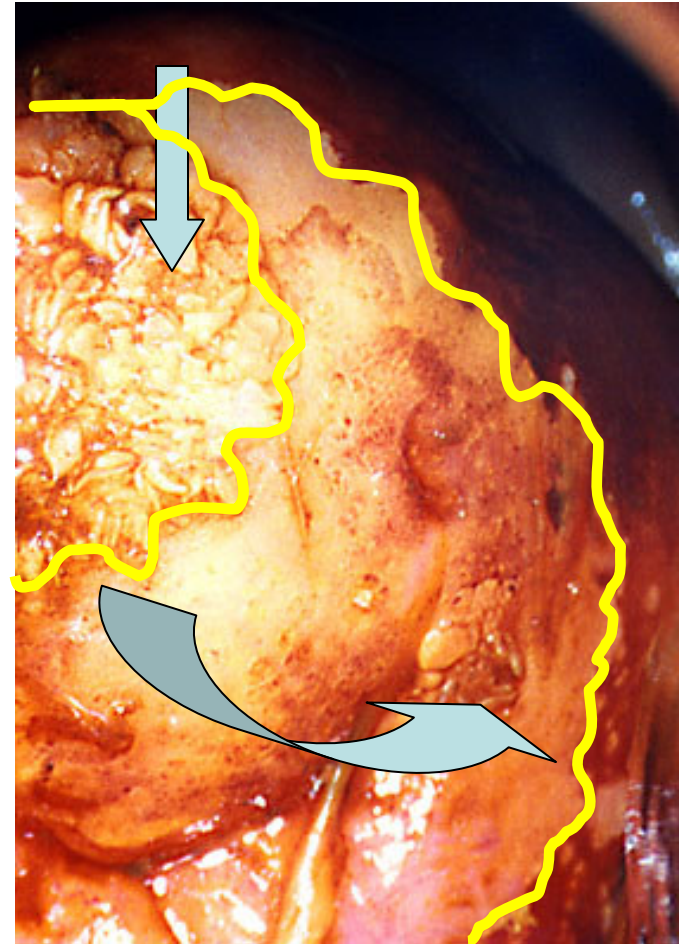
Acetowhite papillary and hypertrophic pluristratified epithelium of the uterine portio - Kraatz green light

- Acetowhite papillary (*down arrow, white scribble*) and hypertrophic pluristratified epithelium of the anterior lip of the uterine portio (*curved up arrow, yellow scribble*), visible to the naked eye, HPV infection as a continuum. Pathohistology on LETZ verified papilloma exophyticum (*down arrow, white scribble*) and CIN III (*curved up arrow, yellow scribble*).



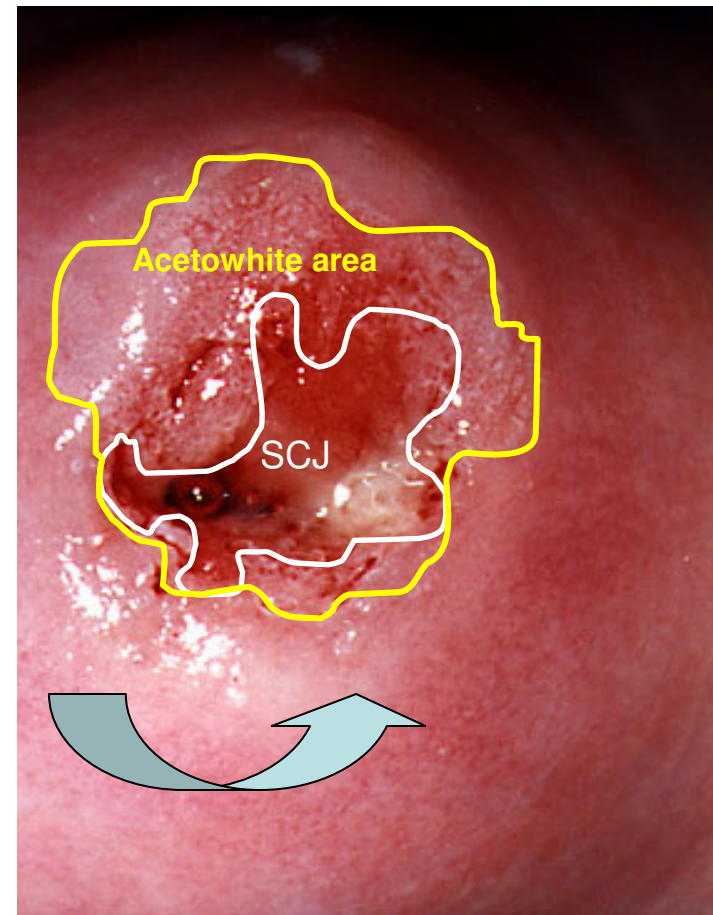
Acetowhite papillary and hypertrophic pluristratified epithelium of the uterine portio

- Both acetowhite papillary (*down arrow*,) and hypertrophic pluristratified epithelium of the anterior lip of the uterine portio (*yellow scribble*), as well as a part of posterior lip (*curved up arrow*, *yellow scribble*) demonstrate large iodine negative, Schiller's positive area. As already mentioned, pathohistology on LETZ verified papilloma exophyticum (*down arrow*) and CIN III (*curved up arrow*).



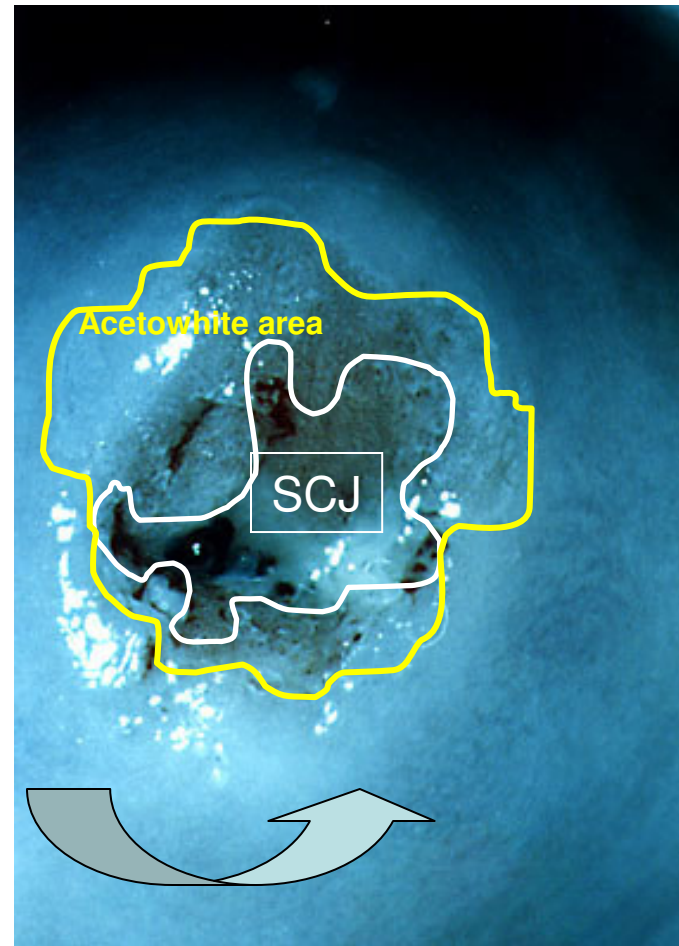
Smooth acetowhite epithelium of the uterine portio

- Smooth acetowhite epithelium on the uterine portio of a nulliparous woman
- SCJ - *white scribble*
- Margins of the acetowhite area - *yellow scribble*
- Healthy pluristratified epithelium - *curved up arrow*



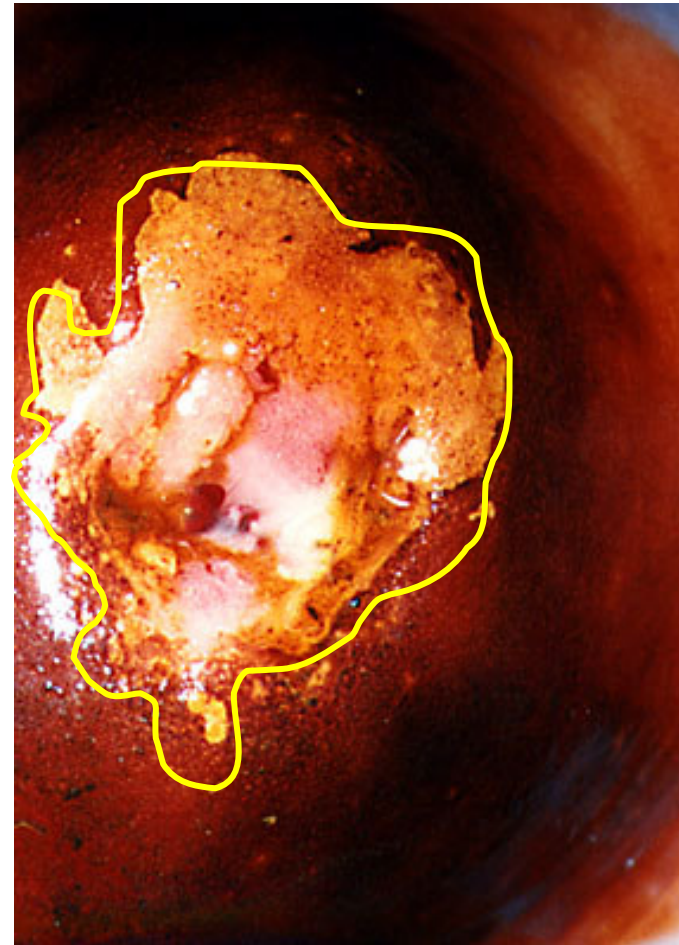
Smooth acetowhite epithelium of the uterine portio - Kraatz green filter

- Smooth acetowhite epithelium on the uterine portio of a nulliparous woman
- SCJ - *white scribble*
- Margins of the acetowhite area - *yellow scribble*
- Healthy pluristratified epithelium- *curved up arrow*



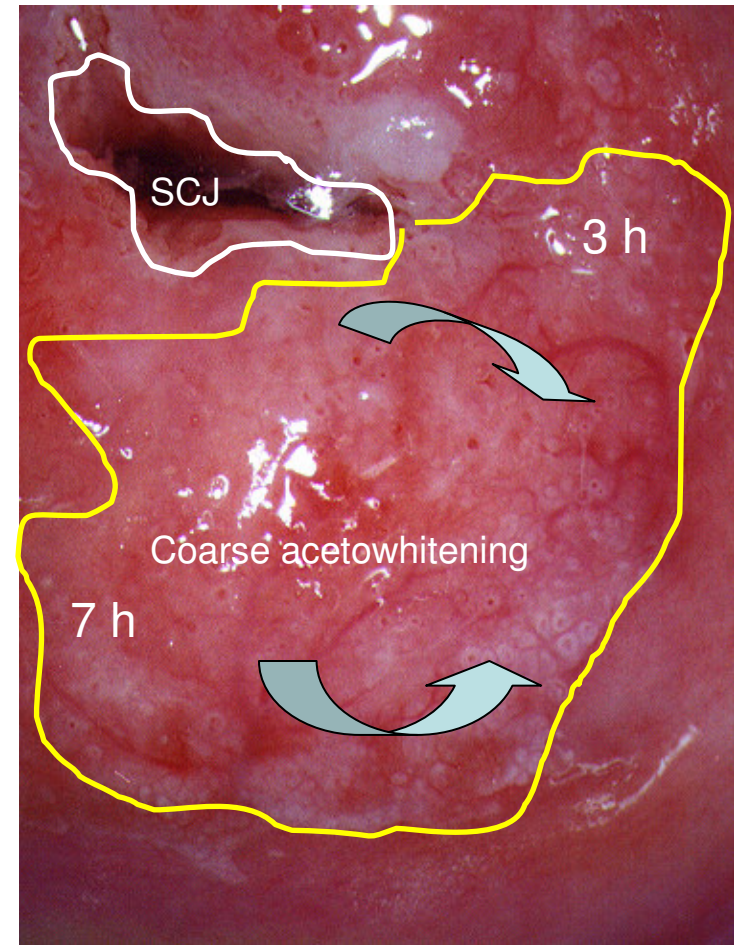
Smooth acetowhite epithelium of the uterine portio - Schiller's iodine test

- Smooth acetowhite epithelium on the uterine portio of a nulliparous woman
- Acetowhite area demonstrates iodine negative captation - *yellow scribble*



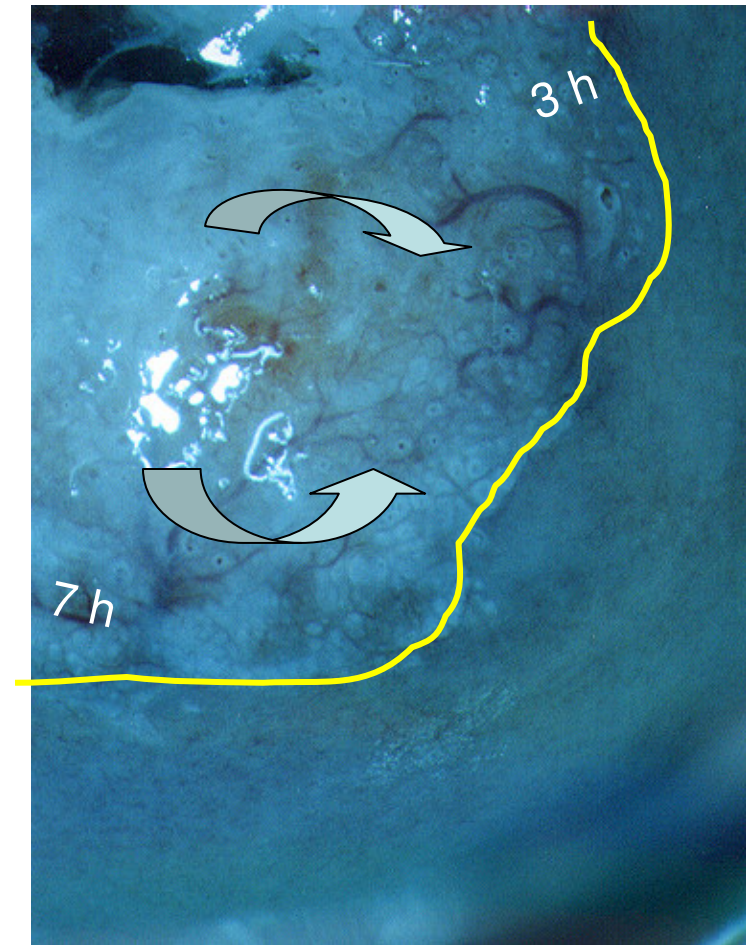
Vascular disarrangement in coarse acetowhite epithelium

- Vascular disarrangement in coarse acetowhite epithelium
- SCJ (*white scribble*) fully visible
- The area from 3 to 7 o'clock clockwise demonstrates coarse acetowhitening (*yellow scribble margins*), various intercapillary distances (*curved up arrow*), as well as horizontal abnormal blood vessels (*curved down arrow*), a sign of underlying intraepithelial neoplastic tissue



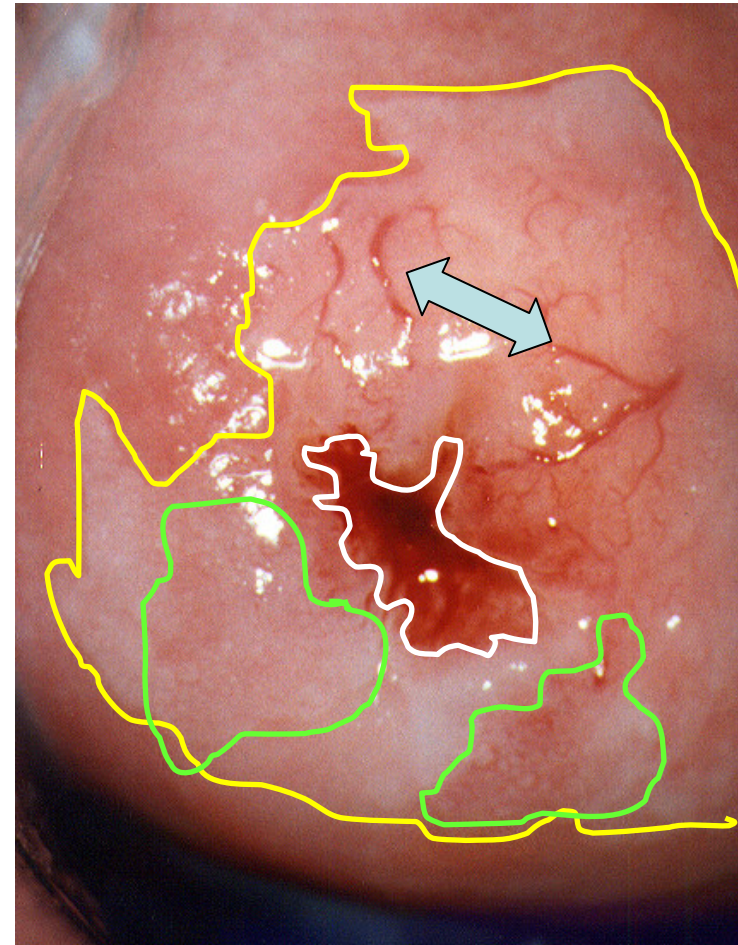
Vascular disarrangement in coarse acetowhite epithelium - Kraatz green filter

- The area from 3 to 7 o'clock clockwise demonstrates coarse acetowhitening (*yellow scribble margins*), various intercapillary distances (*curved up arrow*), as well as horizontal abnormal blood vessels (*curved down arrow*), a sign of underlying intraepithelial neoplastic tissue



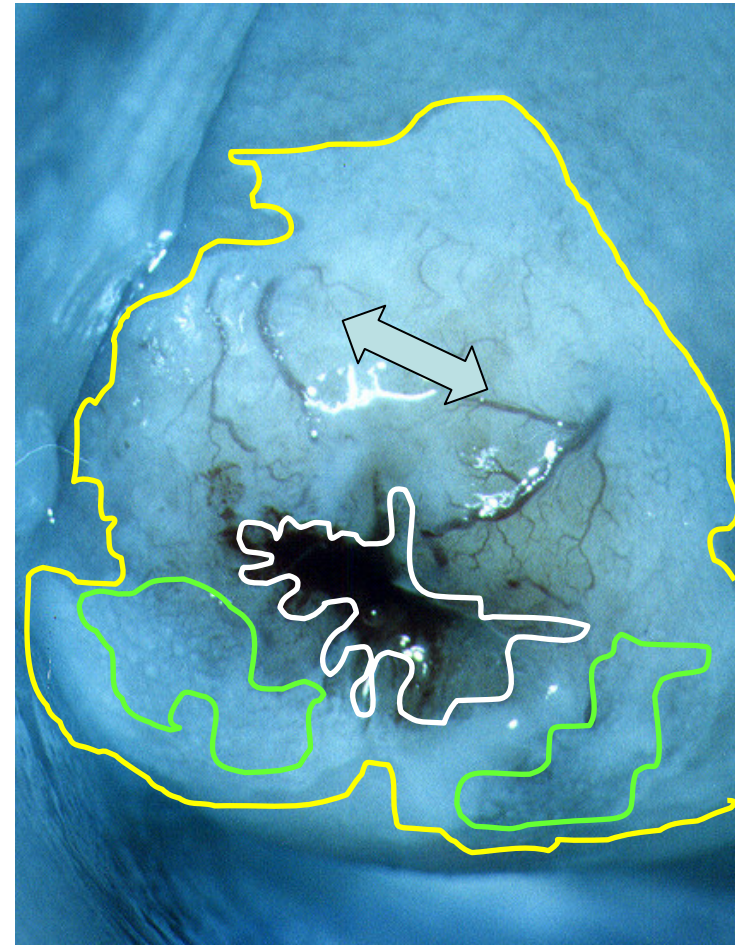
Vascular disarrangement in coarse acetowhite epithelium - another patient

- Vascular disarrangement in coarse acetowhite epithelium - another patient
- SCJ fully visible (*white scribble*), in TZ, (*between white and yellow scribble*), coarse acetowhitening, blood vessels hypertrophic (*left-right arrow*), some areas of moderate mosaic clearly visible (*light green scribble*)



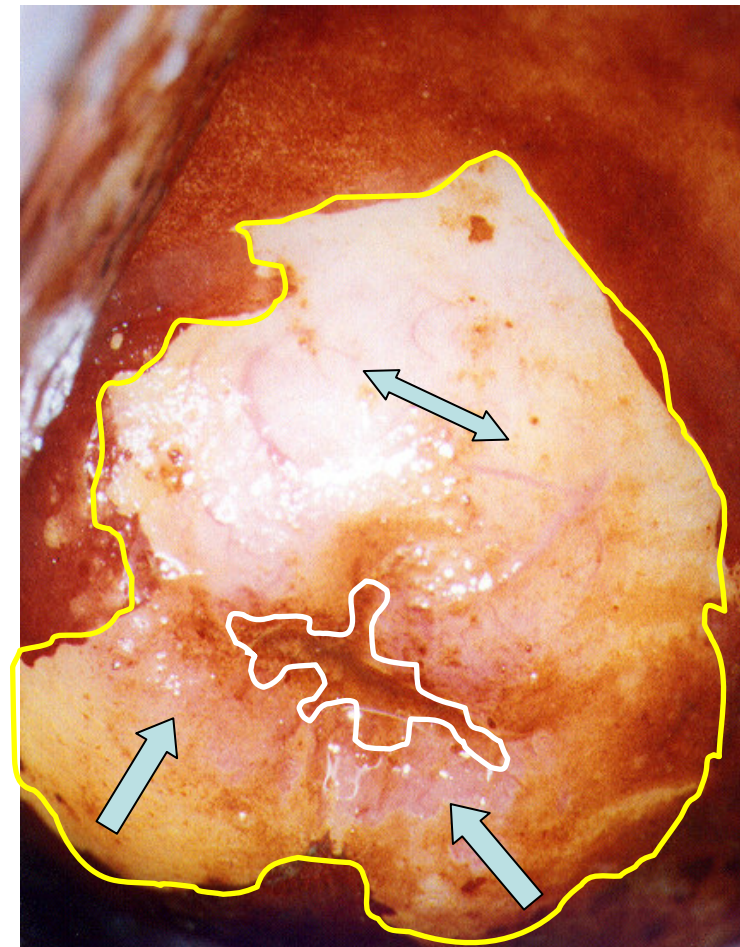
Kraatz green filter and vascular disarrangement in coarse acetowhite epithelium - another patient

- Kraatz green filter and vascular disarrangement in coarse acetowhite epithelium - another patient
- Vascular disarrangement in coarse acetowhite epithelium - another patient
- SCJ fully visible (*white scribble*), in TZ (*between white and yellow scribble*), coarse acetowhitening, blood vessels hypertrophic (*left-right arrow*), some areas of moderate mosaic clearly visible (*light green scribble*)



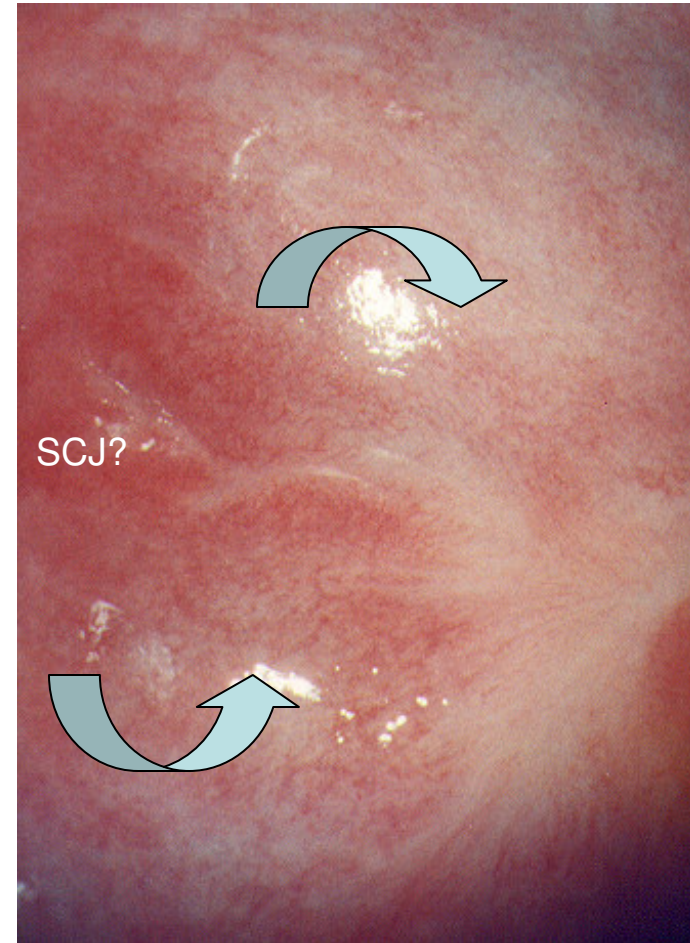
Vascular disarrangement in coarse acetowhite epithelium - another patient - Schiller's iodine test

- Vascular disarrangement in coarse acetowhite epithelium - another patient - Schiller's iodine test
- Vascular disarrangement in coarse acetowhite epithelium (*left-right arrow*), as well as some areas of moderate mosaic demonstrate huge iodine negative area (*up arrows*)



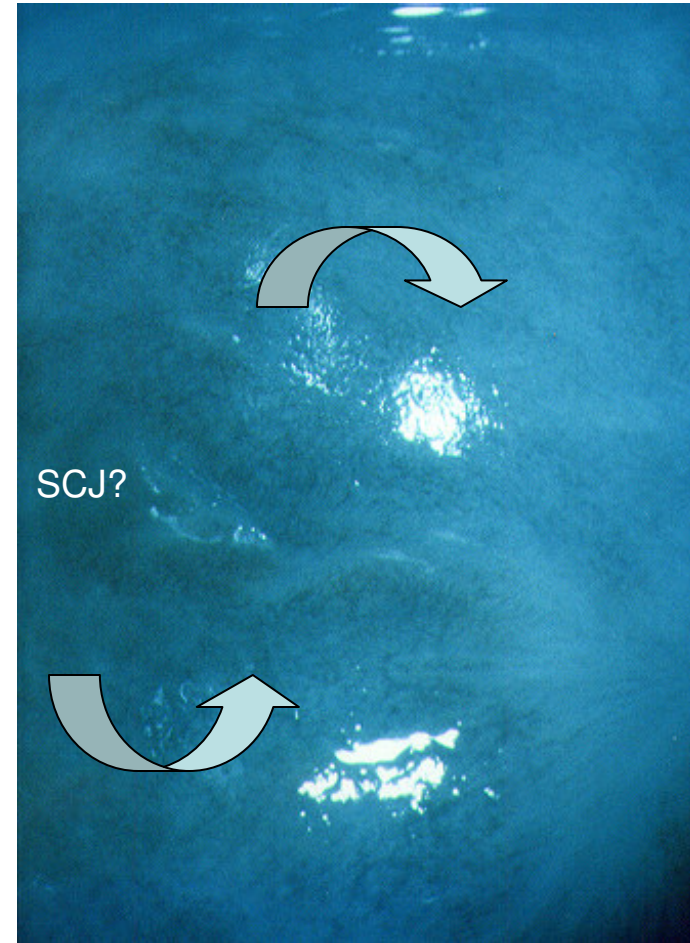
Hypoestrinemic surface of the uterine portio

- SCJ not visible, capillary arrangement well-visible because of the thickened epithelial layer (hypoestrinemic pattern in postmenopausal woman) (*curved down and curved up arrow*)



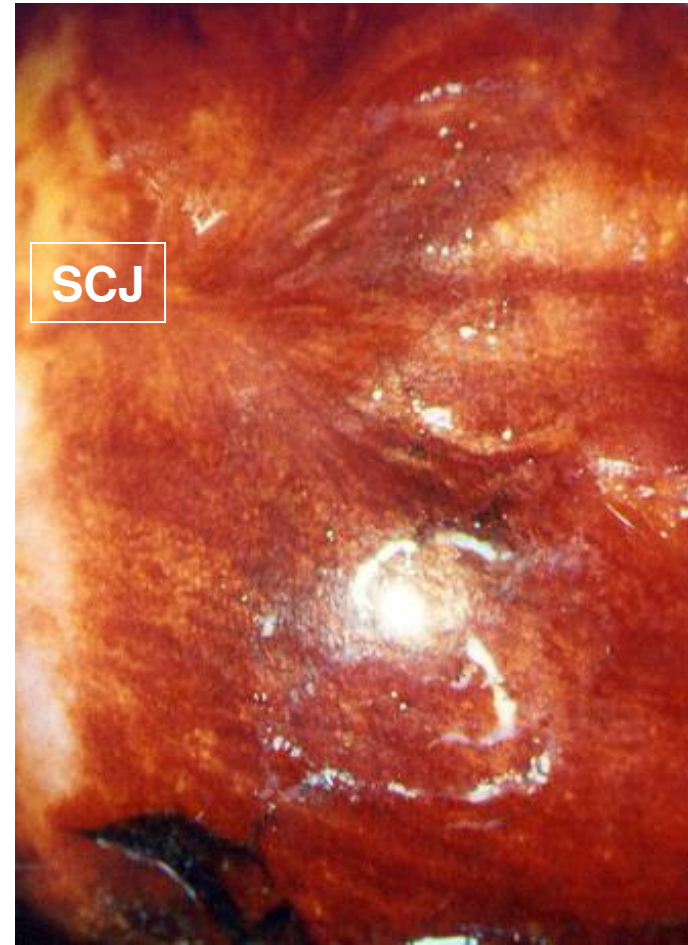
Hypoestrinemic surface of the uterine portio - Kraatz green filter

- SCJ not visible, capillary arrangement well-visible because of the thickened epithelial layer (hypoestrinemic pattern in postmenopausal woman) (*curved down and curved up arrow*)



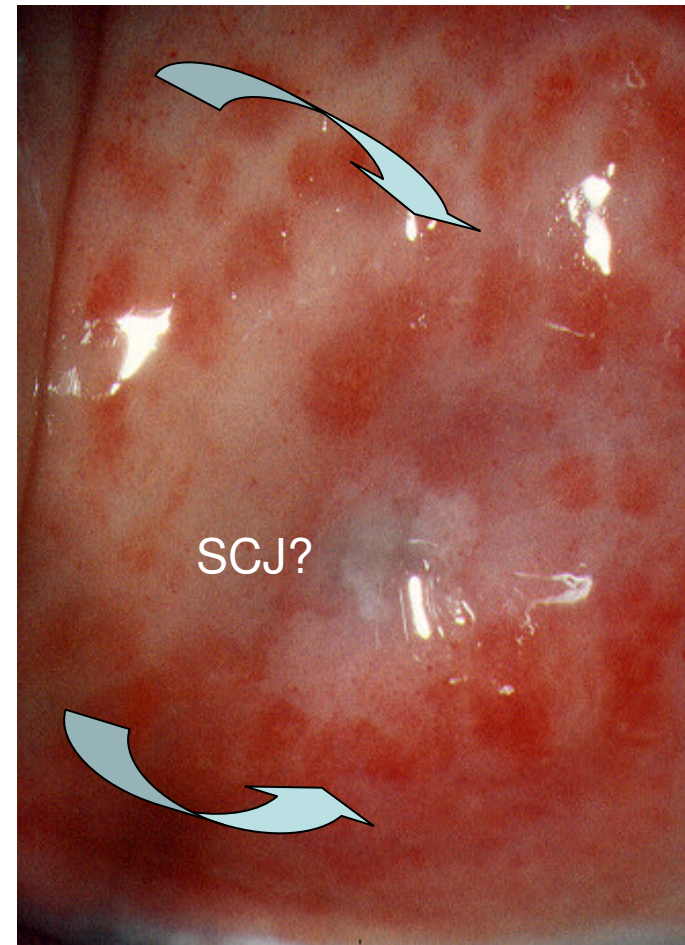Hypoestrinemic surface of the uterine portio - Schiller's iodine test

- SCJ not visible, iodine captation weakened because of the thickened epithelial layer (hypoestrinemic pattern in postmenopausal woman)



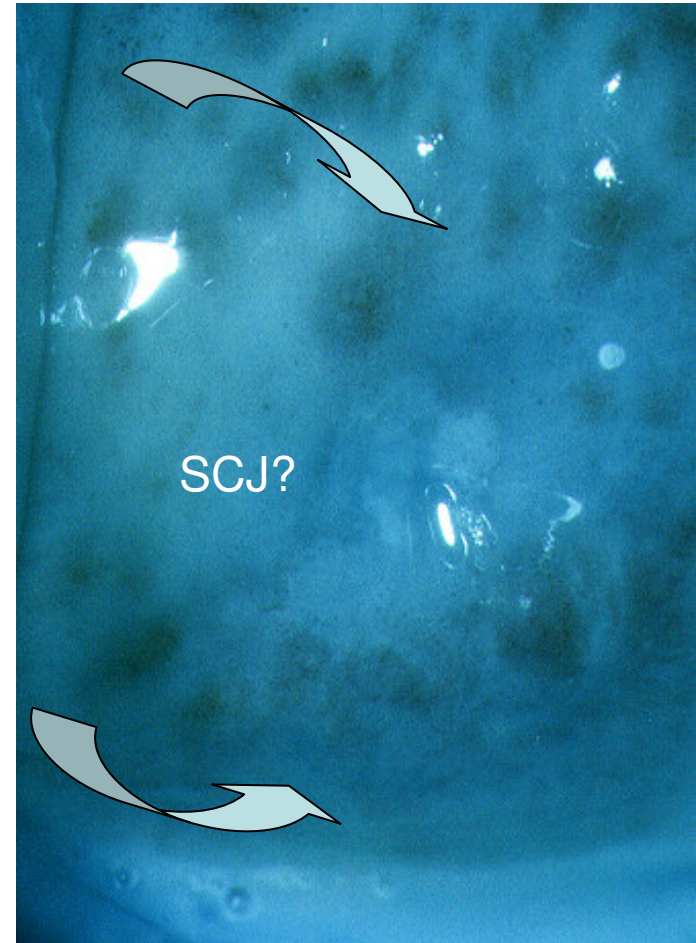
Cervicitis macularis (inflamed surface of the uterine cervix in postmenopausal women)

- Cervicitis macularis (inflamed surface of the uterine cervix in postmenopausal women) is sometimes misunderstood by beginners as “coarse punctation”
- SCJ not visible
- Cervical surface with multiple reddish mini-areas on the anterior lip (*curved down arrow*), as well as a confluent reddish large area on the posterior lip of the uterine cervix (*curved up arrow*)



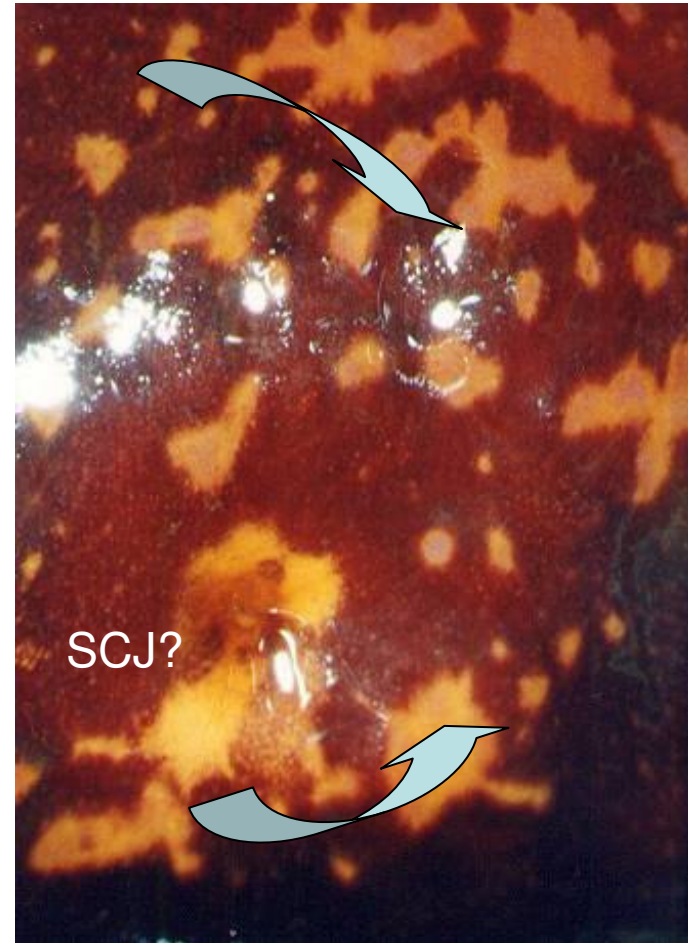
Cervicitis macularis (inflamed surface of the uterine cervix in postmenopausal women) - Kraatz green filter

- Cervicitis macularis (inflamed surface of the uterine cervix in postmenopausal women) is sometimes misunderstood by beginners as “coarse punctation”
- SCJ not visible
- Cervical surface with multiple reddish mini-areas on the anterior lip (*curved down arrow*), as well as a confluent reddish large area on the posterior lip of the uterine cervix (*curved up arrow*)



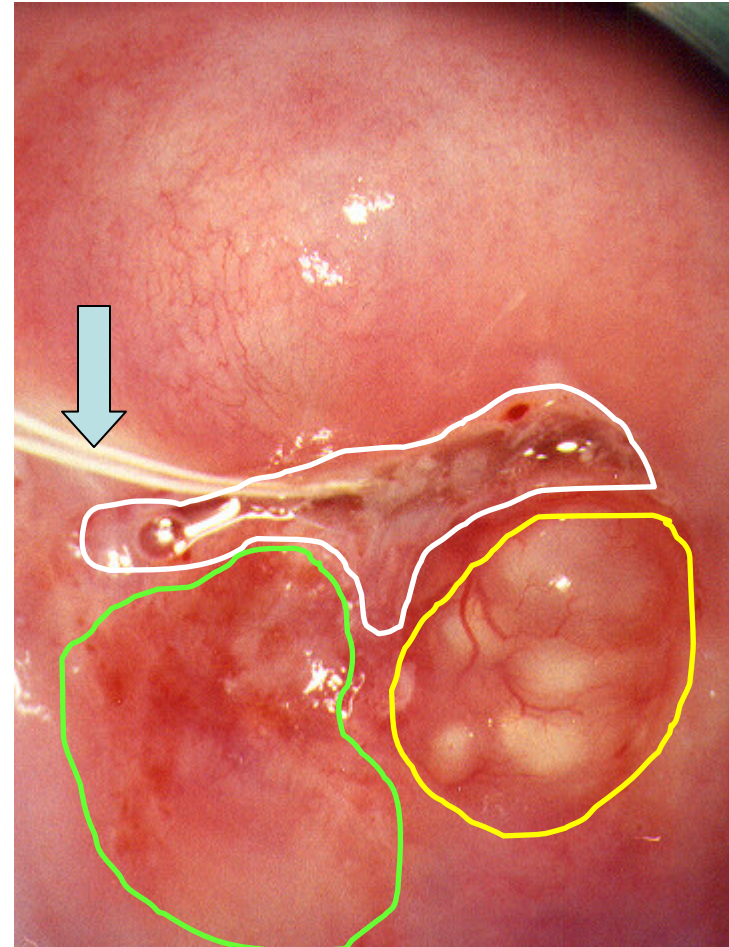
Cervicitis macularis (inflamed surface of the uterine cervix in postmenopausal women) - Schiller's iodine test

- Cervicitis macularis (inflamed surface of the uterine cervix in postmenopausal women) is sometimes misunderstood by beginners as “coarse punctation”
- **SCJ** not visible?
- Cervical surface with **multiple iodine negative mini-areas** both on the anterior (*curved down arrow*), as well as on the posterior lip of the uterine cervix (*curved up arrow*)



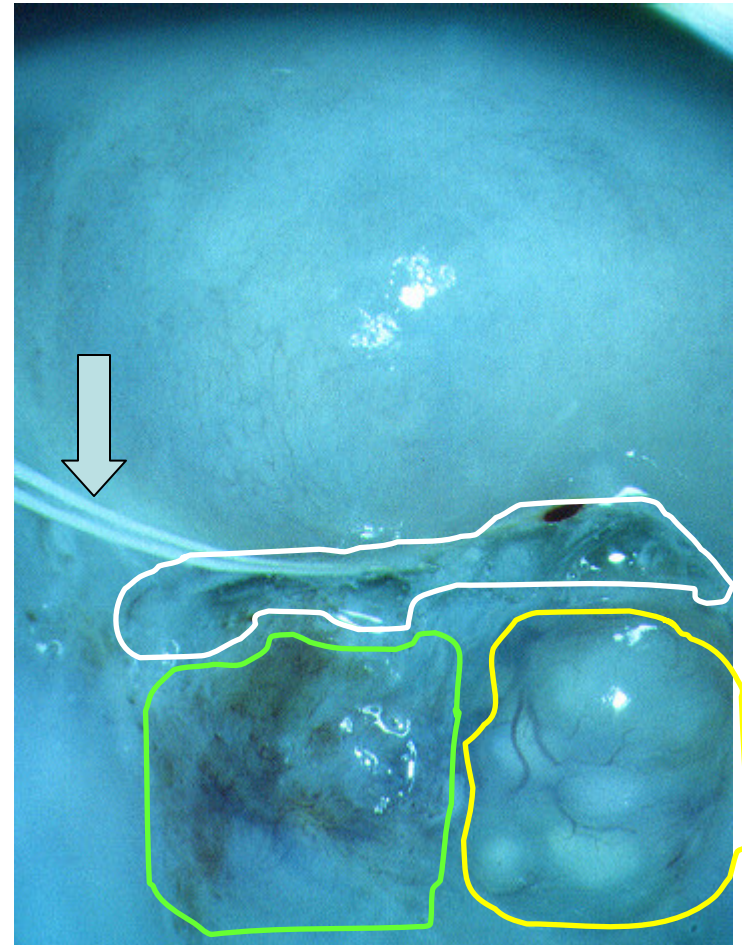
Abnormal colposcopic finding and IUD

- Filaments of IUD (*down arrow*)
- SCJ fully visible (*white scribble*)
- Confluent ovula Nabothii (*yellow scribble area*)
- Area of dysplastic tissue verified by pathohistology (*light green scribble*)



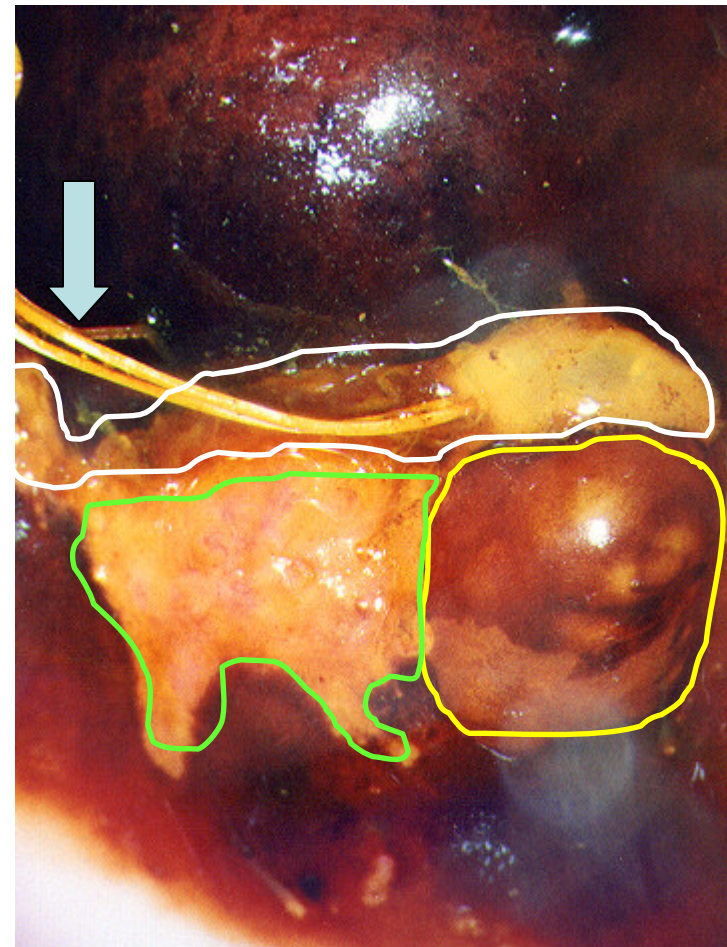
Abnormal colposcopic finding and IUD - Kraatz green filter

- Filaments of IUD (*down arrow*)
- SCJ fully visible (*white scribble*)
- Confluent ovula Nabothii (*yellow scribble area*)
- Area of dysplastic tissue verified by pathohistology (*light green scribble*)



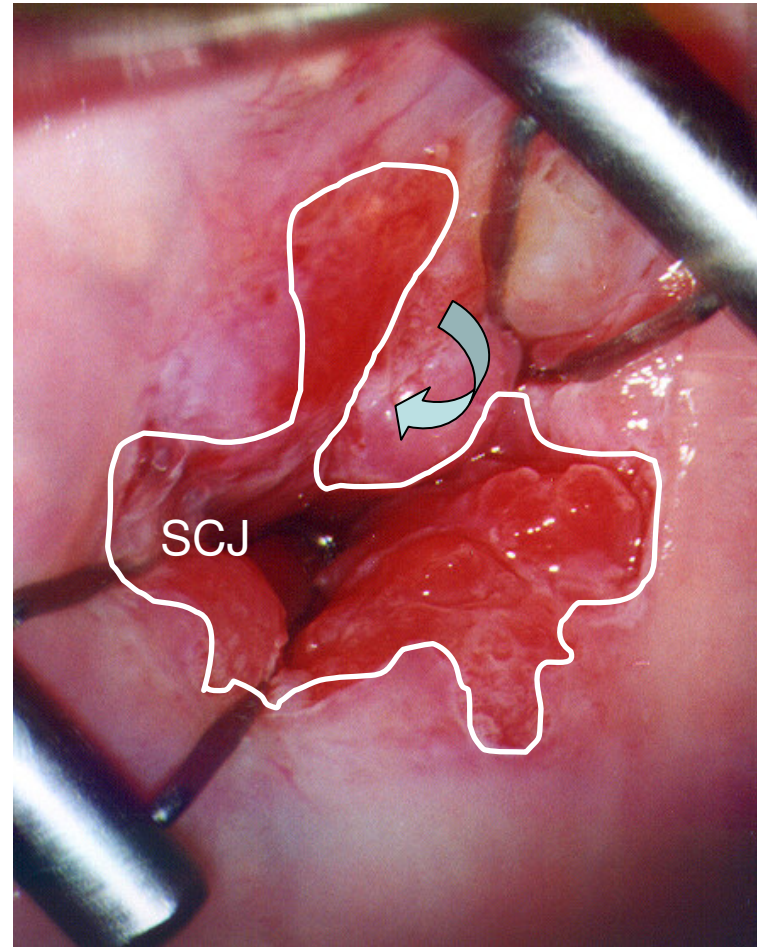
Abnormal colposcopic finding and IUD - Schiller's iodine probe

- Filaments of IUD (*down arrow*)
- SCJ fully visible (*white scribble*)
- Confluent ovula Nabothii (*yellow scribble area*)
- Area of dysplastic tissue verified by pathohistology (*light green scribble*)



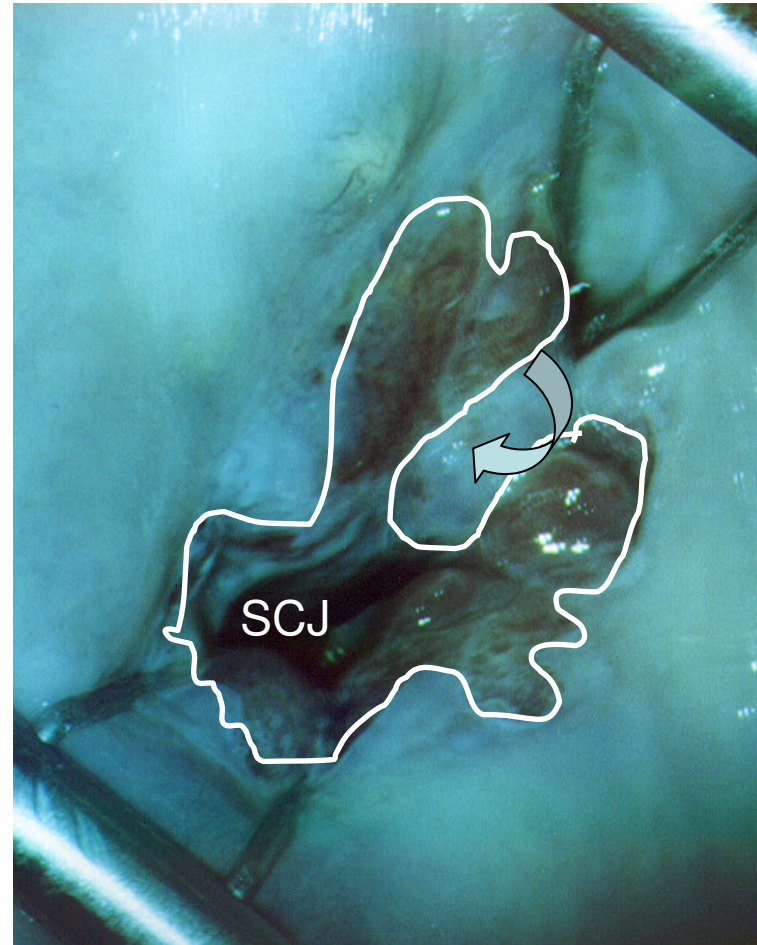
Endocervicoscopy – insertion of Kogan's speculum

- If SCJ is partially visible, it is advised to perform endocervicoscopy with Kogan's speculum, which enables to see how much colposcopically suspicious area enters the cervical channel
(curved left arrow)



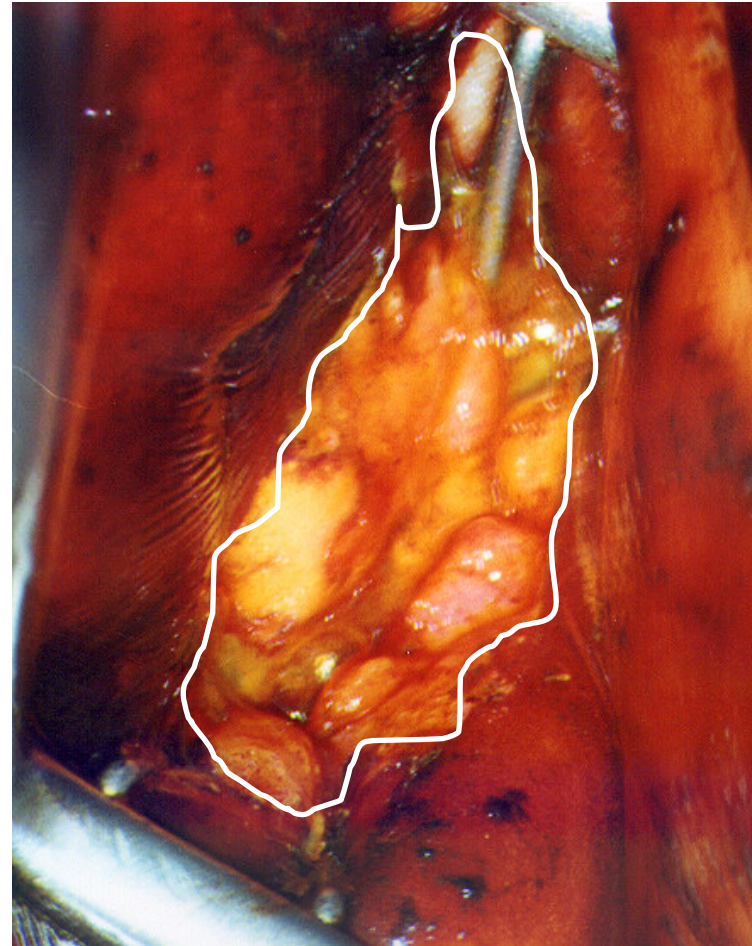Endocervicoscopy – insertion of Kogan's speculum

- If SCJ is partially visible, it is advised to perform endocervicoscopy with Kogan's speculum, which enables to see how much colposcopically suspicious area enters the cervical channel
(curved left arrow)



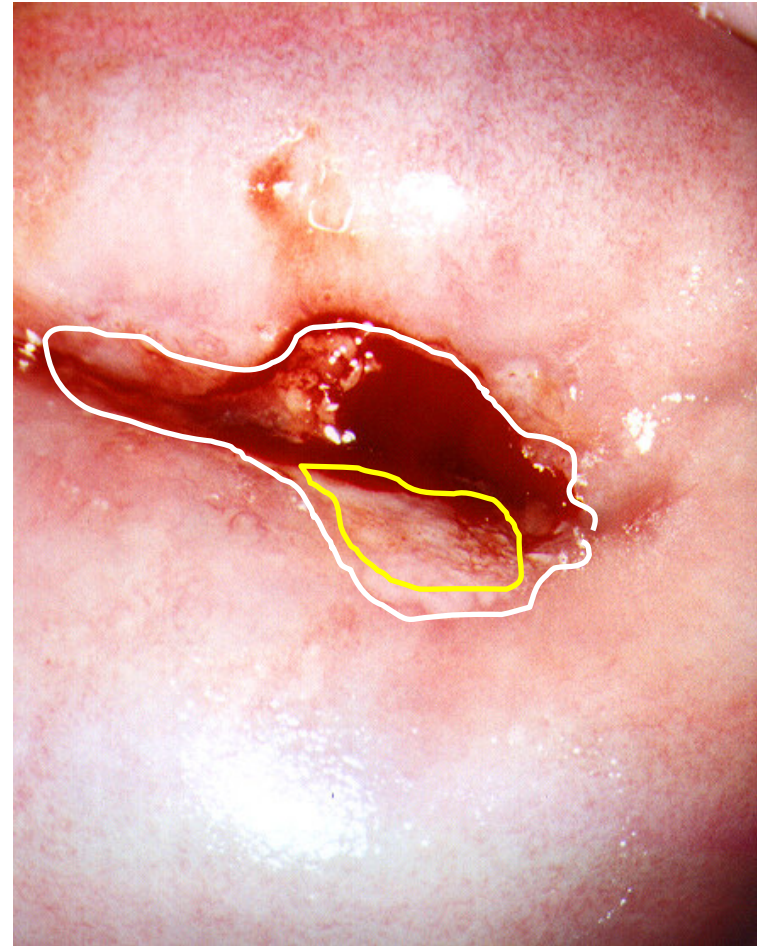
Endocervicoscopy – insertion of Kogan's speculum - Schiller's iodine test

- Endocervicoscopy – insertion of Kogan's speculum
- Iodine negative area represents hypertrophic endocervical papillary structure
- There was no disease

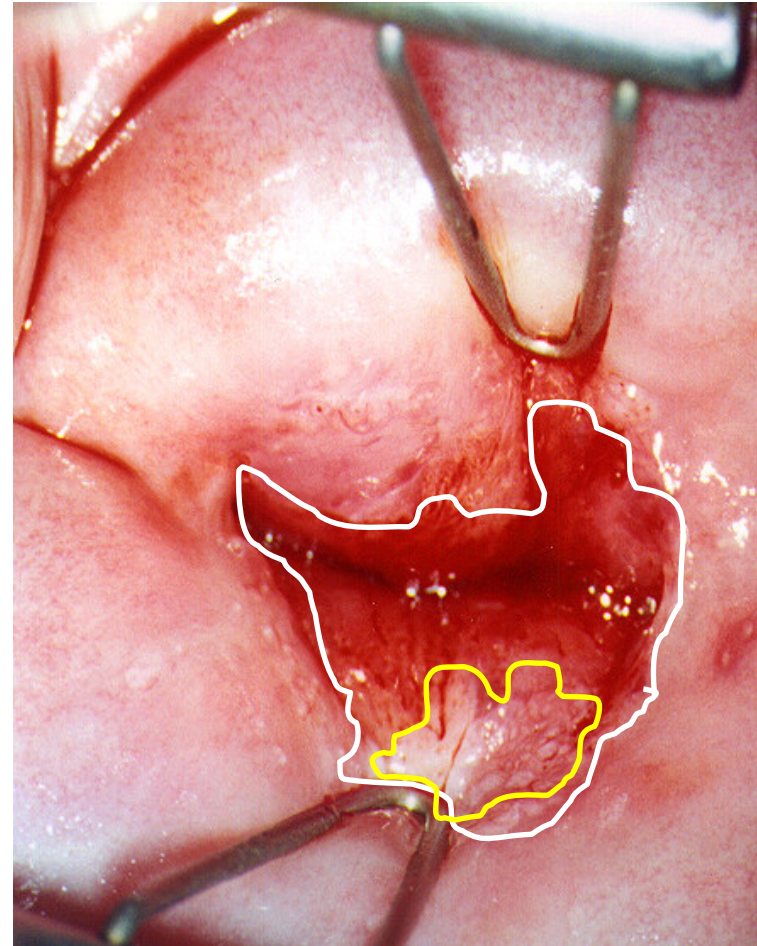


SCJ not fully visible - suitable for endocervicoscopy with Kogan's endocervical speculum

- SCJ not fully visible - suitable for endocervicoscopy by Kogan's endocervical speculum
- Vulnerable external orifice of the uterine cervix (*white scribble*)
- Partially visible SCJ (*yellow scribble*)

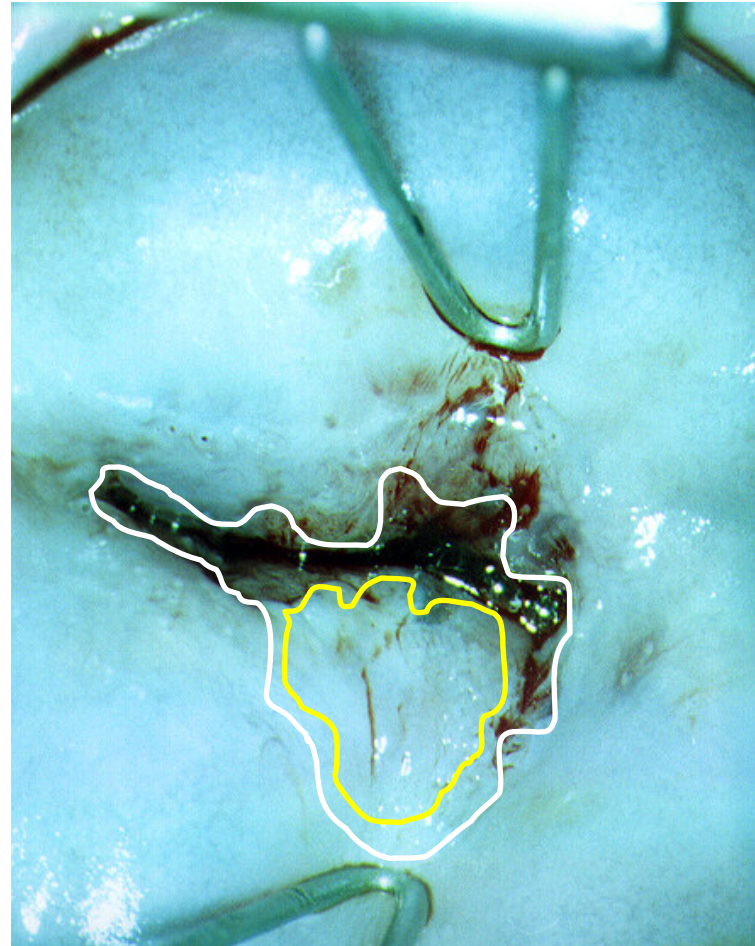

- Endocervicoscopy – insertion of Kogan's speculum enables to see complete SCJ (*white scribble*), as well as keratotic area on the posterior lip, suitable for punch biopsy (*yellow scribble*)

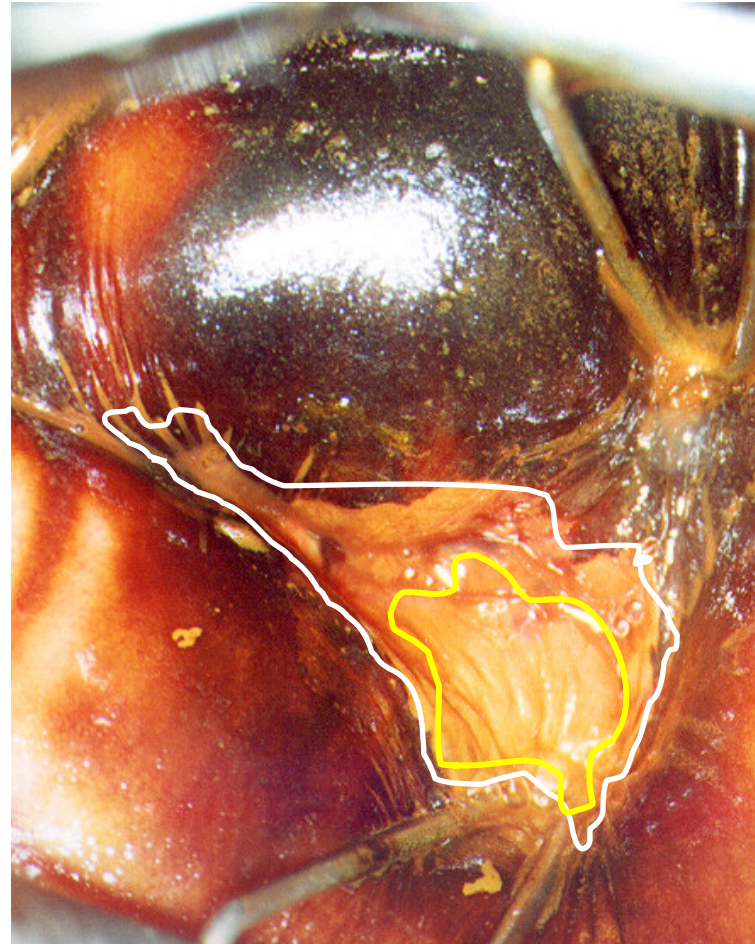


Endocervicoscopy – insertion of Kogan's speculum - Kraatz green filter

- Endocervicoscopy – insertion of Kogan's speculum enables to see complete SCJ (*white scribble*), as well as keratotic area on the posterior lip, suitable for punch biopsy (*yellow scribble*)

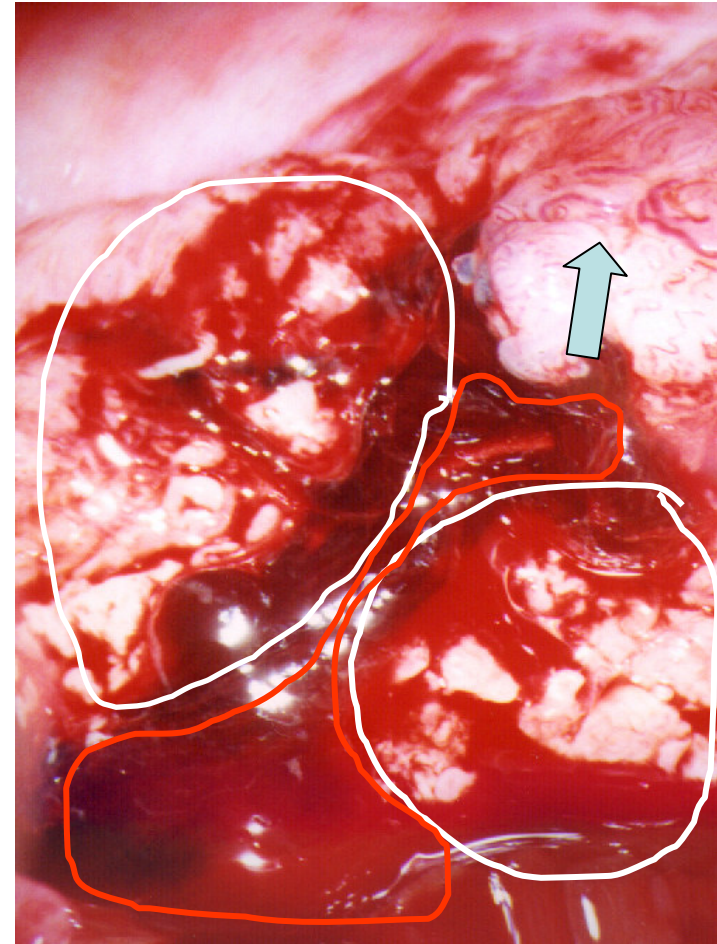


- Endocervicoscopy – insertion of Kogan's speculum enables to see iodine negative area of the posterior lip suitable for punch biopsy
- SCJ- *white scribble*
- Iodine negative area- *yellow scribble*



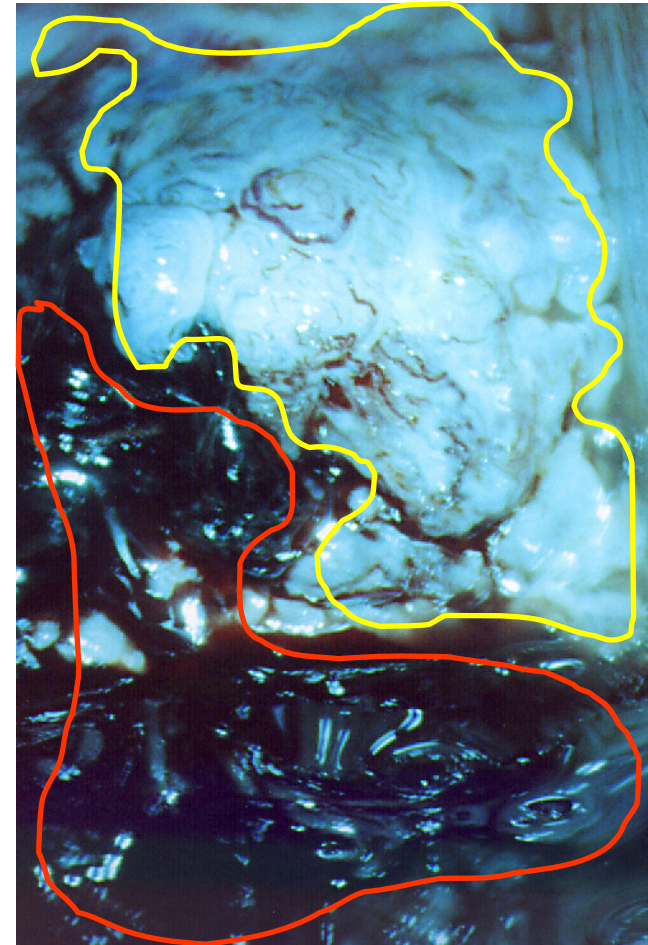
Invasive cancer of the uterine cervix- exophytic appearance

- Abnormal hyperplastic and vulnerable tissue (*white scribbles*)
- Abundant bloodish discharge (*red scribble*)
- Complete disarrangement of the vascular pattern (*up arrow*)



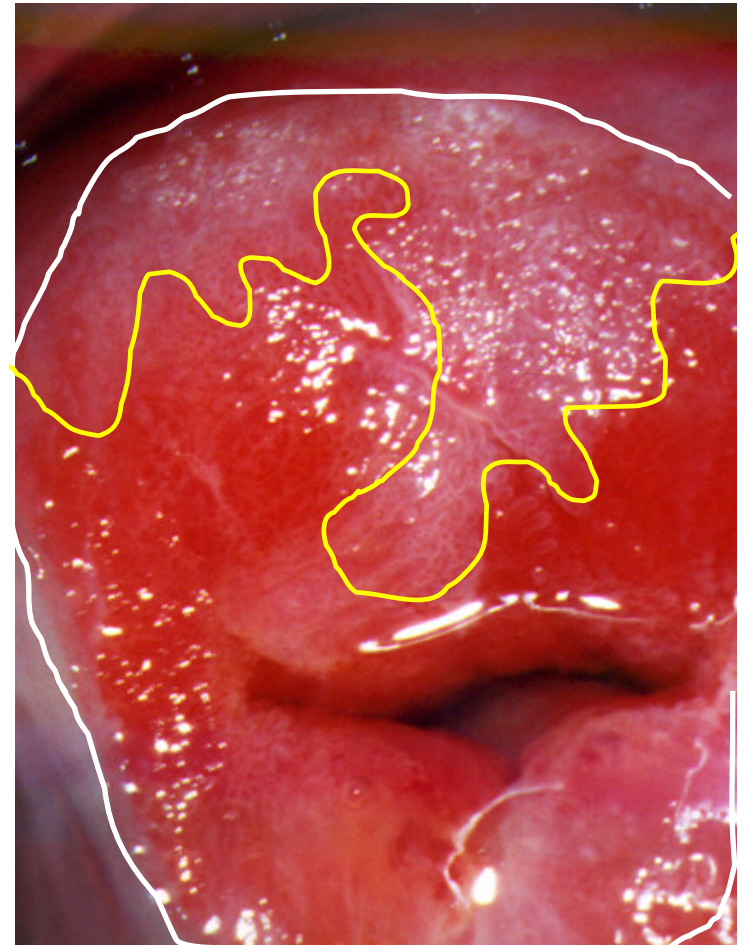Invasive cancer of the uterine cervix - exophytic appearance - Kraatz green filter

- Invasive cancer of the uterine cervix - exophytic appearance - the same portio, Kraatz green filter of the left part of the anterior lip demonstrating abundant vascular disarrangement (*yellow scribble margin*) as well as bloodish discharge (*red scribble margin*)



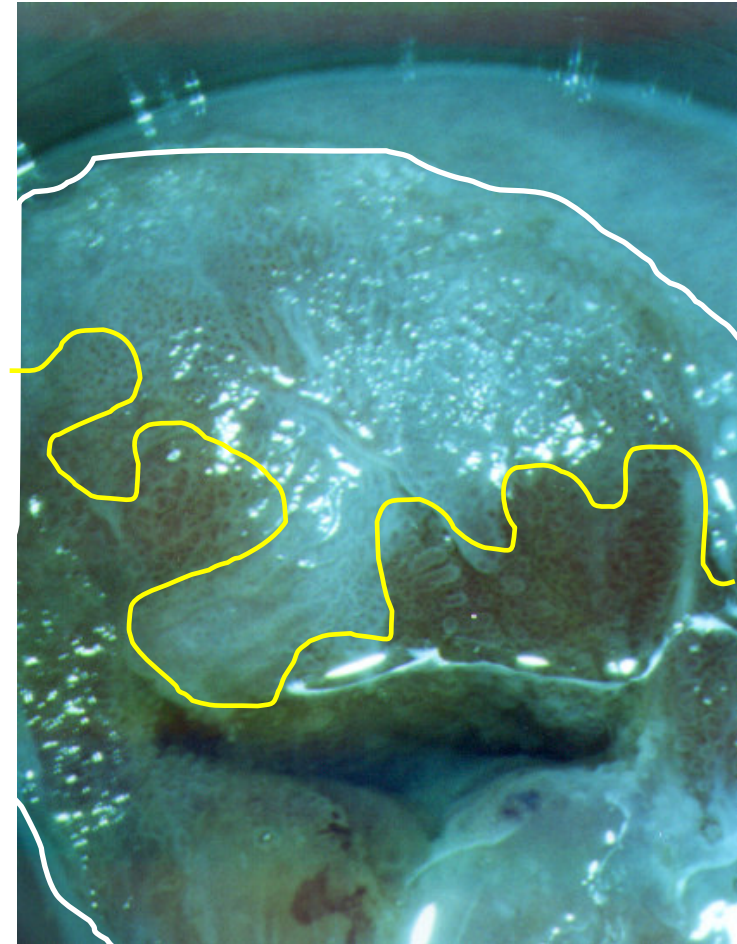
Large eversion of the cylindric epithelium at the middle of the menstrual cycle, periovulatory period.

- Large eversion of the cylindric epithelium at the periovulatory period (*white scribble*). Slight acetowhite areas covering the anterior lip of the uterine cervix (*yellow scribble*)



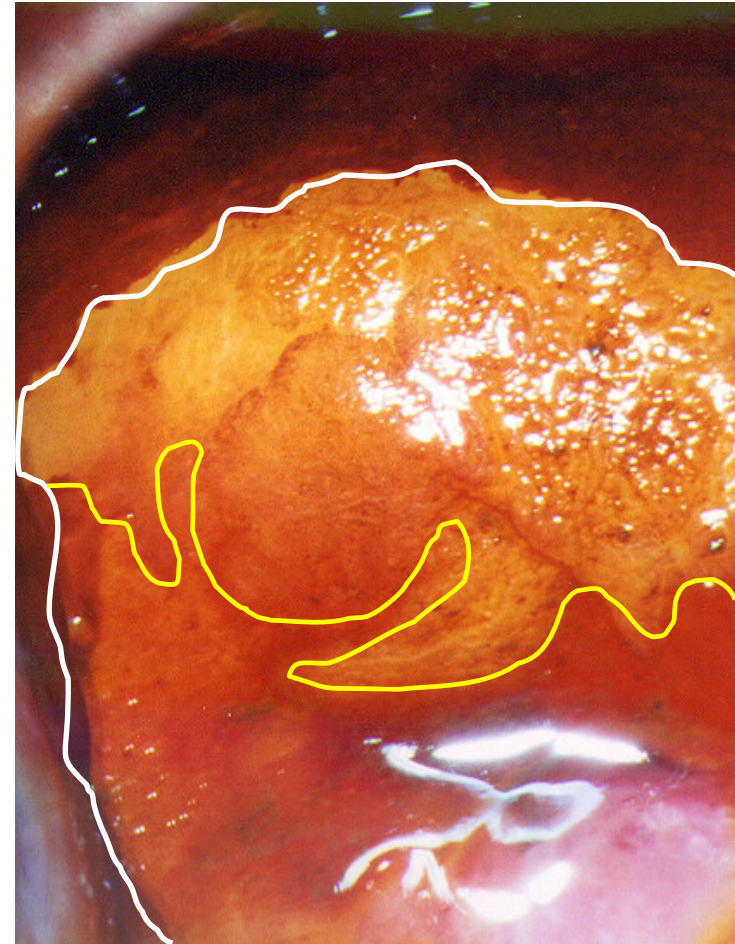
Large eversion of the cylindric epithelium at the middle of the menstrual cycle, periovulatory period
– Kraatz green filter

- Large eversion of the cylindric epithelium at the periovulatory period (*white scribble*). Slight acetowhite areas covering the anterior lip of the uterine cervix (*yellow scribble*)



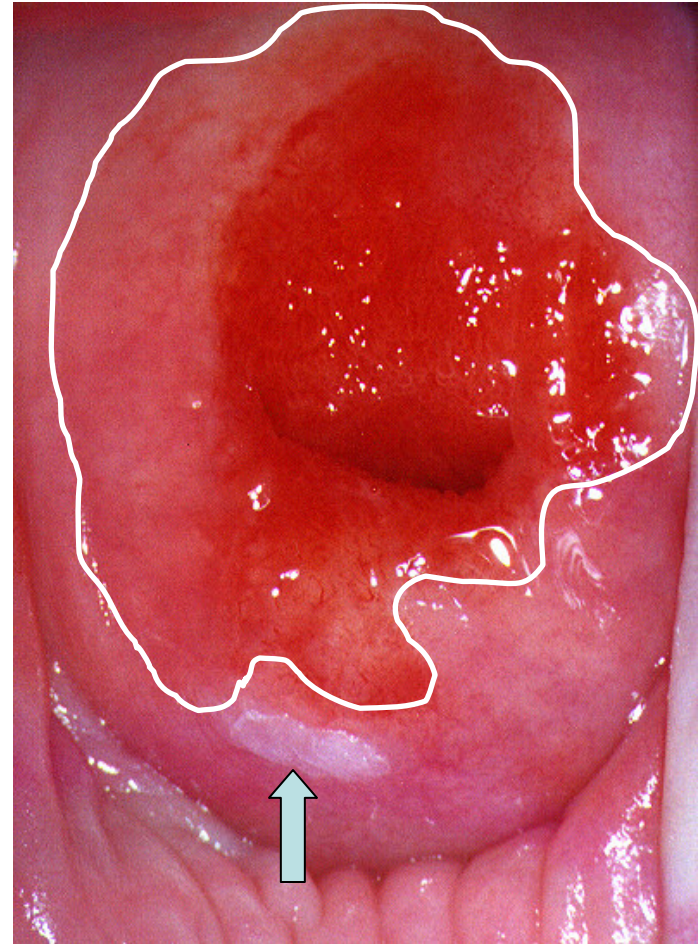
Large eversion of the cylindric epithelium at the middle of the menstrual cycle, periovulatory period
- Schiller's iodine test

- Large eversion of the cylindric epithelium at the periovulatory period (*white scribble*). Slight acetowhite areas covering the anterior lip of the uterine cervix (*yellow scribble*)



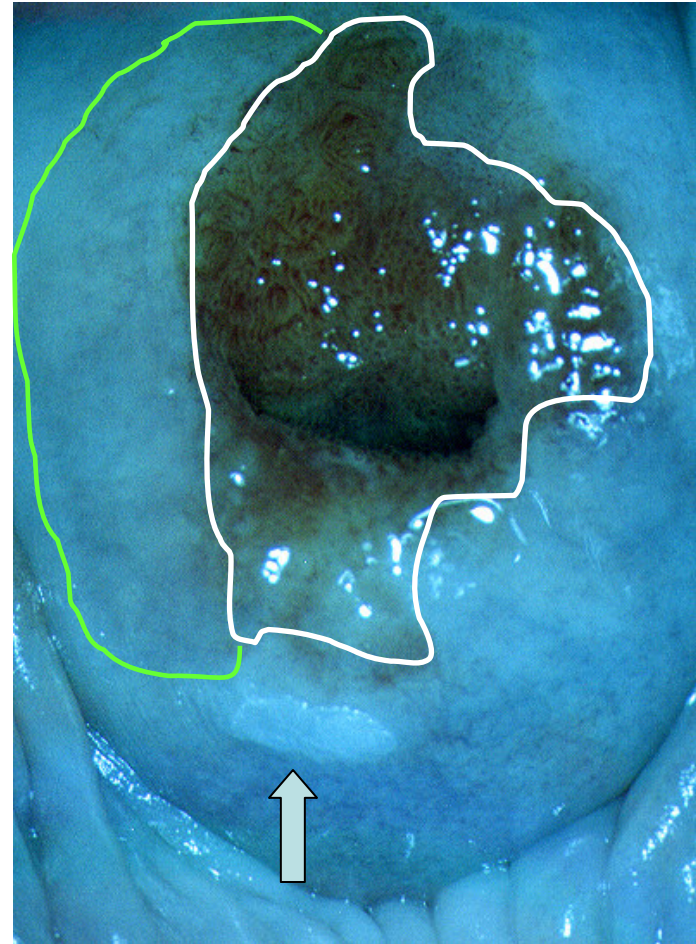
What is this?

- SCJ fully visible-
white scribble
- At first sight great
ectropion and
papilloma
exophyticum of the
posterior lip
(up arrow)
- But... See the
following pictures!



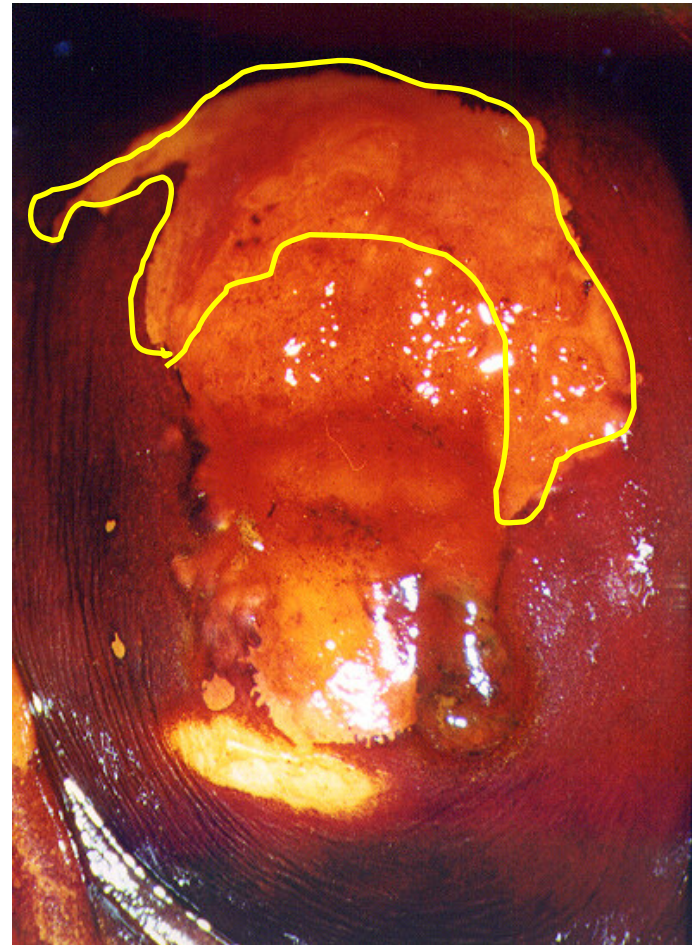
What is this?

- Green filter Kraatz:
- SCJ fully visible - *white scribble*
- Papilloma exophyticum of the posterior lip (*up arrow*)
- But what's up with the semilunar part of the uterine portio surface? (*light green scribble*)



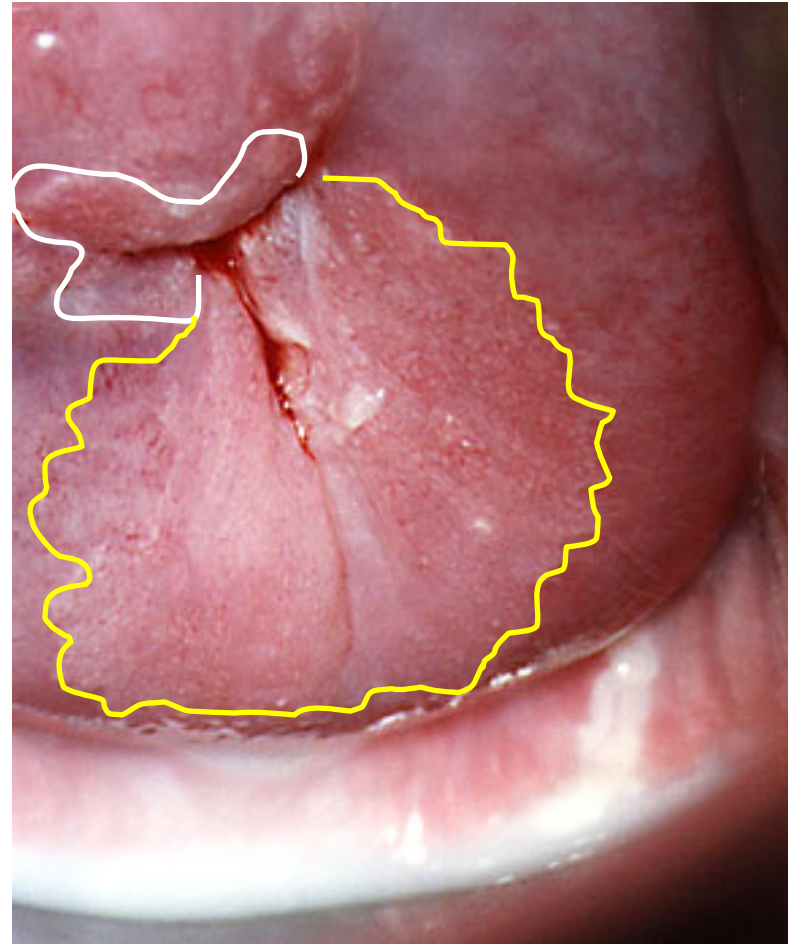
I found this surprising, there was quite a discordance between these three pictures of the same patient

- Schiller's iodine test demonstrated large iodine negative area out of SCJ on the anterior lip (*yellow scribble*), not suspected on the previous two pictures



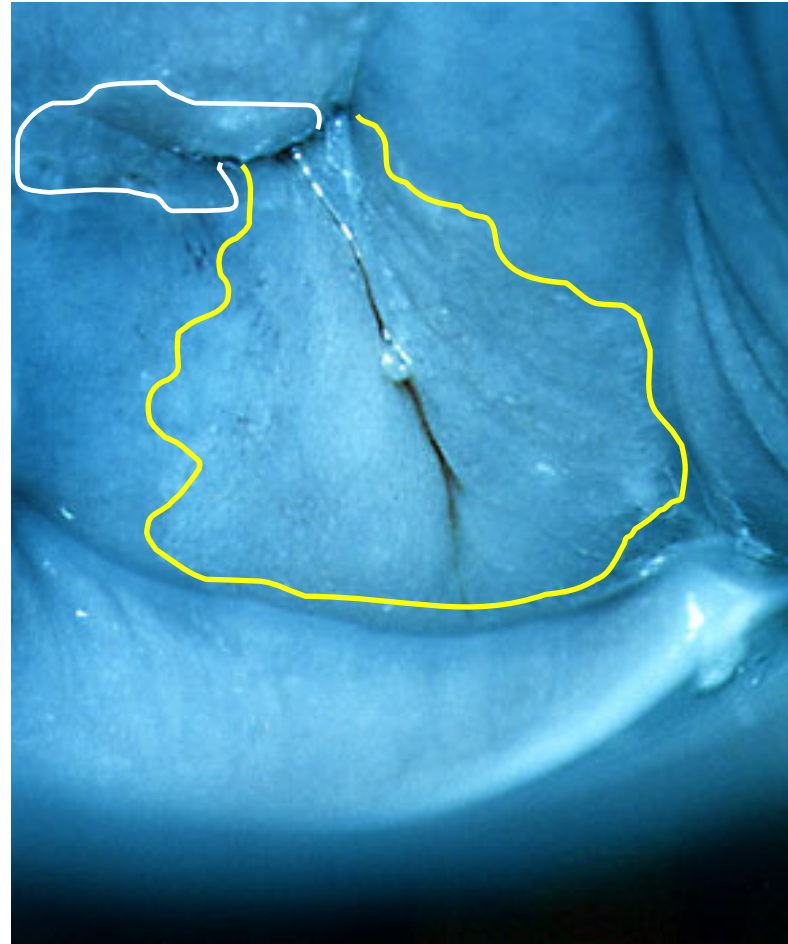
Large area of coarse acetowhitening in a 26-week pregnant woman

- SCJ not fully visible - *white scribble*
- Large area of coarse acetowhitening on the posterior lip of the uterine cervix - *yellow scribble*
- This area was present even after puerperal period, indicating pathohistological verification by punch biopsy
- The diagnosis was CIN III
- Cold knife conisation was performed, it also showed CIN III. Margins were free from disease, along with the top of the conus specimen.



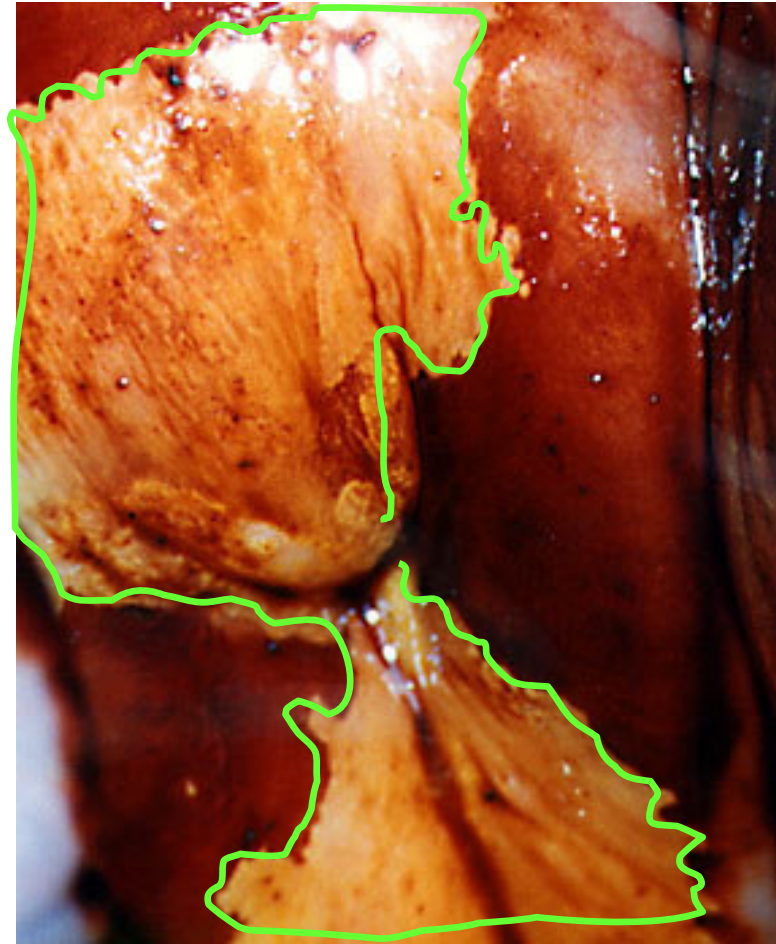
Large area of coarse acetowhitening in a 26-week pregnant woman - Kraatz green filter

- SCJ not fully visible - *white scribble*
- Large area of coarse acetowhitening on the posterior lip of the uterine cervix - *yellow scribble*
- This area was present even after puerperal period, indicating pathohistological verification by punch biopsy
- The diagnosis was CIN III
- Cold knife conisation was performed, it also showed CIN III. Margins were free from disease, along with the top of the conus specimen.



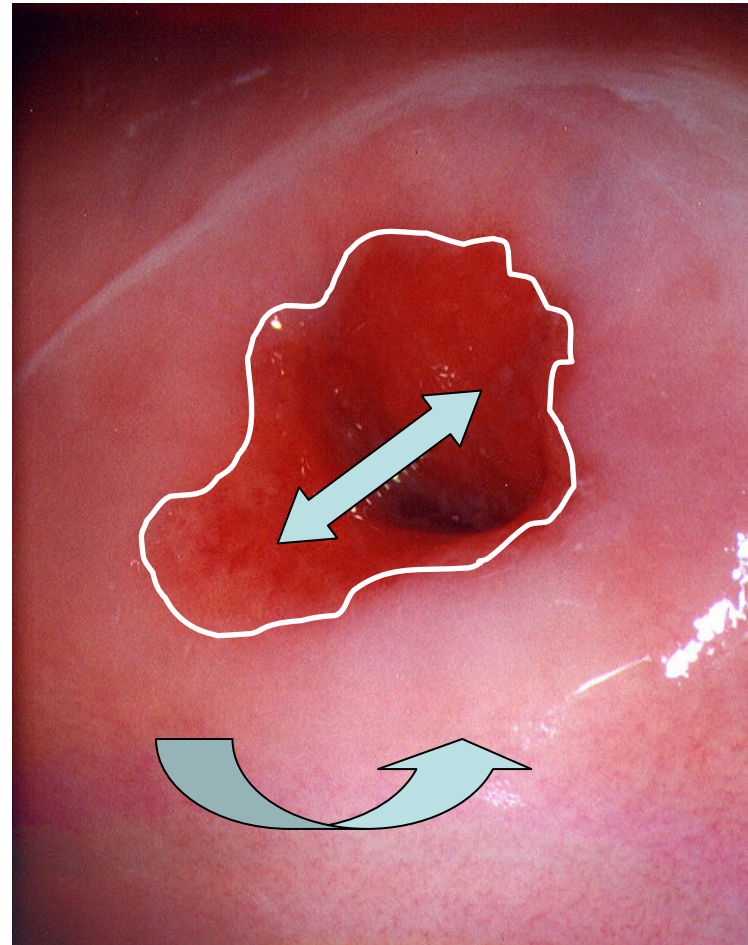
Large area of coarse acetowhitening in a 26-week pregnant woman - Schiller's iodine test

- After Schiller's iodine test, both on the anterior and the posterior lip, iodine negative areas well demarcated from the adjacent healthy tissue of the uterine cervix were visible (*light green scribble*)
- These areas were present even after puerperal period, indicating pathohistological verification by punch biopsy
- The diagnosis was CIN III
- Cold knife conisation was performed, it also showed CIN III. Margins were free from disease, along with the top of the conus specimen.



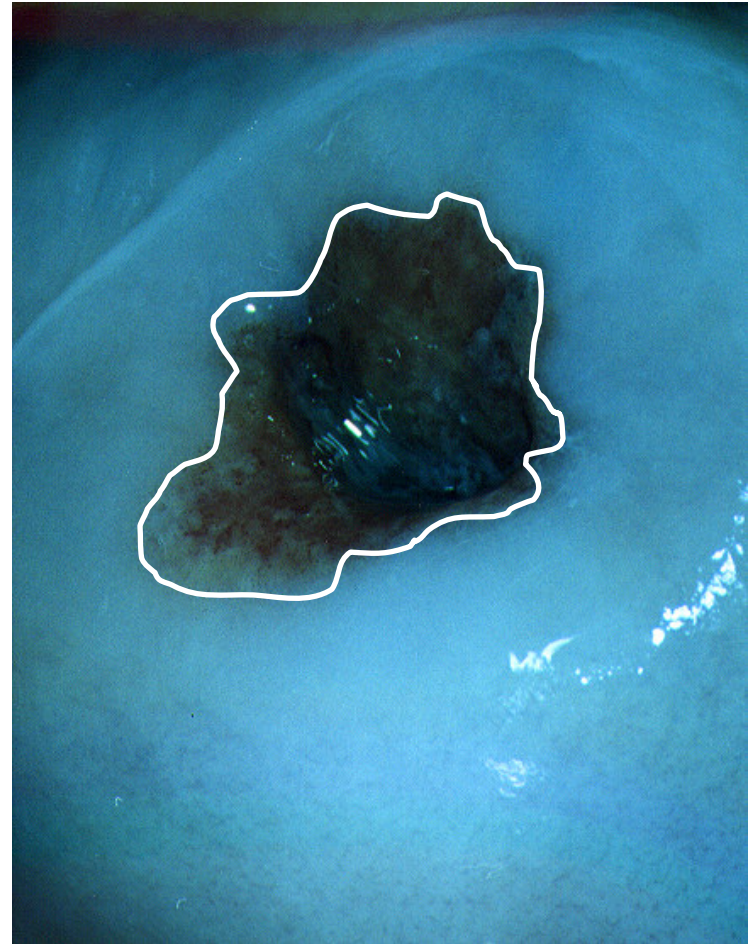
Normal colposcopic finding

- SCJ fully visible - *white scribble*
- Healthy pinkish pluristratified epithelium - *curved up arrow*
- Healthy cylindric epithelium (*reddish*), eversion in the middle of the menstrual cycle, *left-right arrow*



Normal colposcopic finding - Kraatz green filter

- A well-demarcated border (*white scribble*) between two epithelia as a sign of normal, healthy uterine cervix



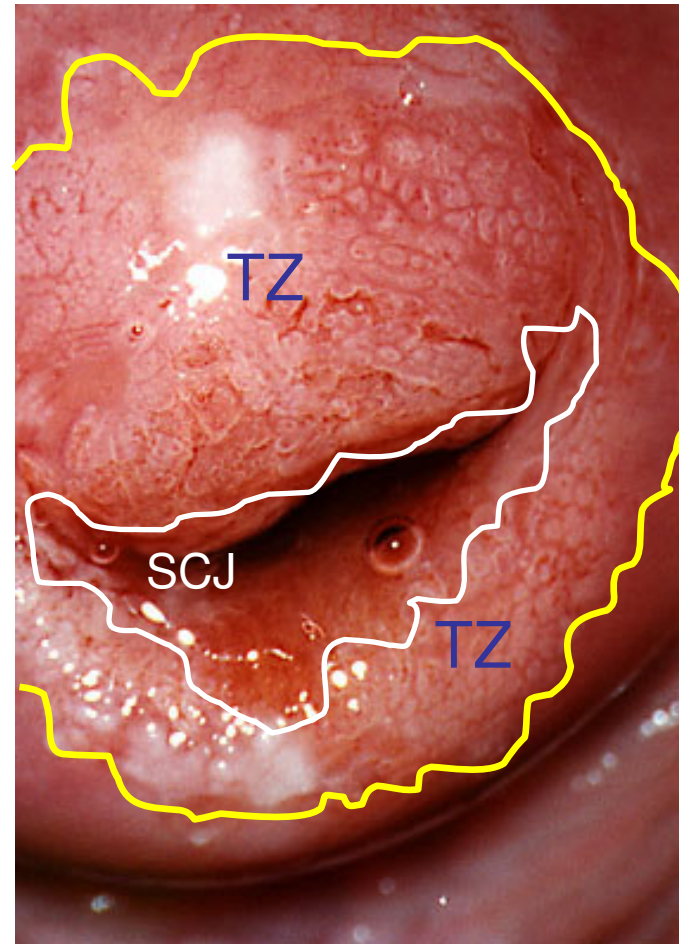
Normal colposcopic finding - Schiller's iodine test

- A well-demarcated border (*yellow scribble*) between two epithelia as a sign of normal, healthy uterine cervix
- Normal, fully expressed iodine captation in pluristratified epithelial layer as a sign of normal glycogenogenesis - *curved up arrow*
- Normal, iodine negative cylindrical epithelium, no glycogenogenesis present - *left-right arrow*




Abnormal colposcopic finding - mosaic (coarse pattern)

- SCJ visible - *white scribble*
- In TZ both the anterior and the posterior lip, large area of coarse mosaic, *between white and yellow scribble*



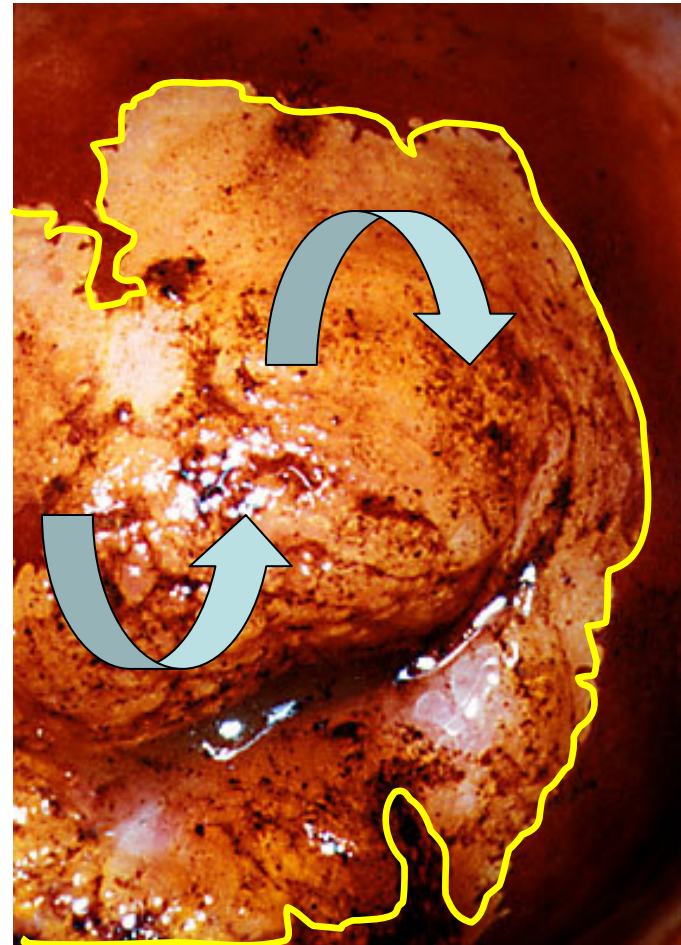
Abnormal colposcopic finding - mosaic (coarse pattern), Kraatz green filter

- SCJ visible - *white scribble*
- In TZ, both the anterior and the posterior lip, large area of coarse mosaic, *between white and yellow scribble*



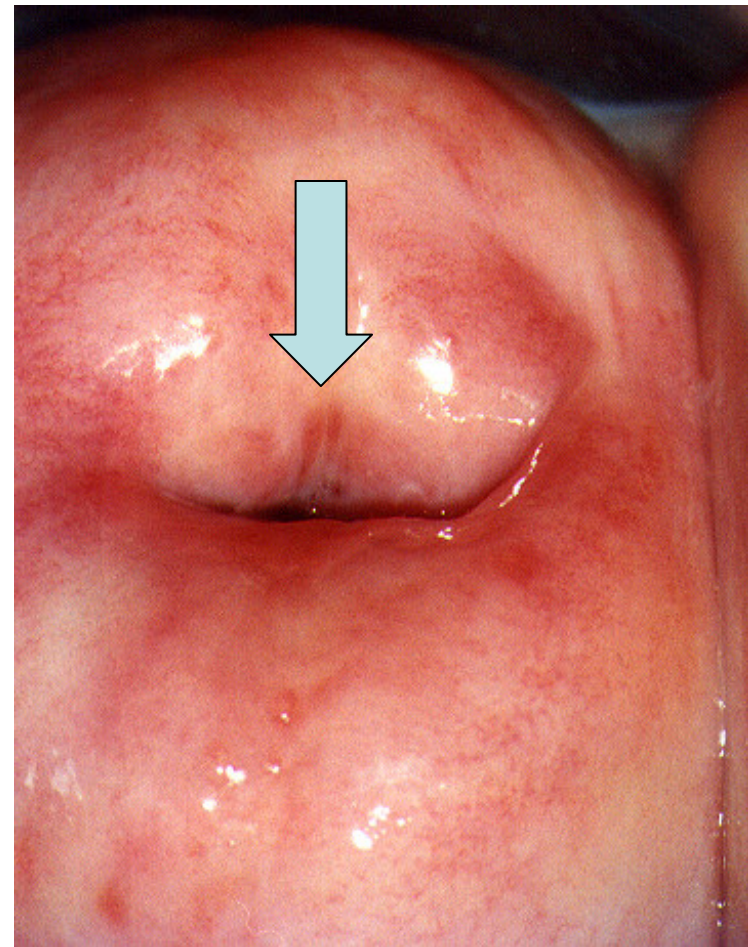
Abnormal colposcopic finding - mosaic (coarse pattern), Schiller's iodine test

- Schiller's iodine test demonstrates a large iodine area suitable for punch biopsies (*yellow scribble*), (*curved down and curved up arrows*), as well as for endocervical curettage
- Pathohistology revealed CIN III on punch biopsy specimen.
- Cold knife conisation was performed after control cytology (CIN III) and colposcopy (coarse mosaic), it also showed CIN III. Margins were free from disease, along with the top of the conus specimen.



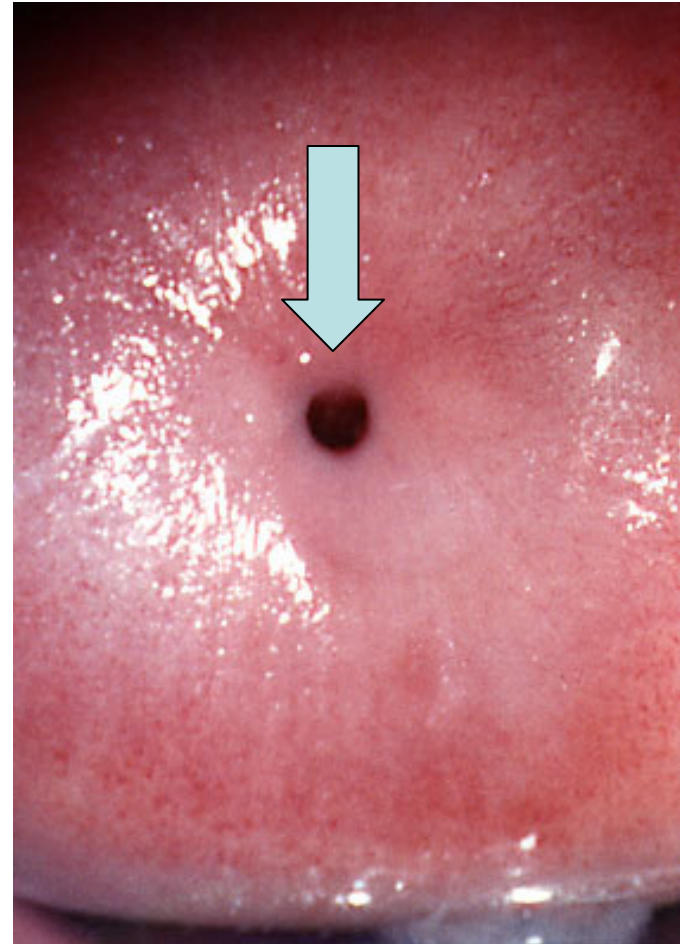
Unsatisfactory colposcopic finding - SCJ not visible

- Unsatisfactory colposcopic finding - SCJ not visible - *down arrow*



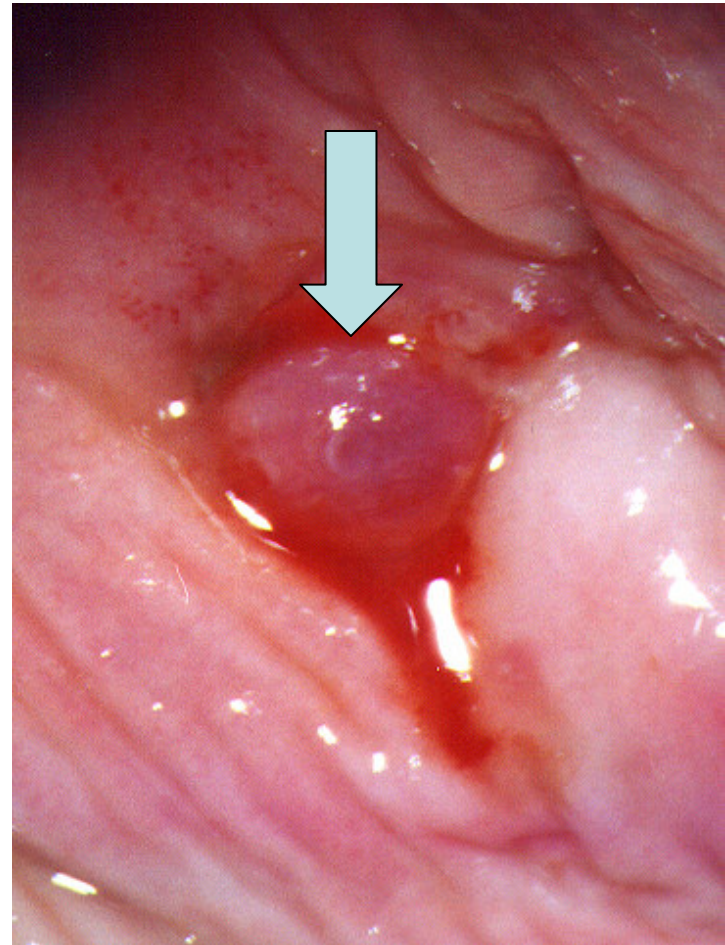
Unsatisfactory colposcopic finding - SCJ not visible

- Unsatisfactory colposcopic finding - SCJ not visible - *down arrow*



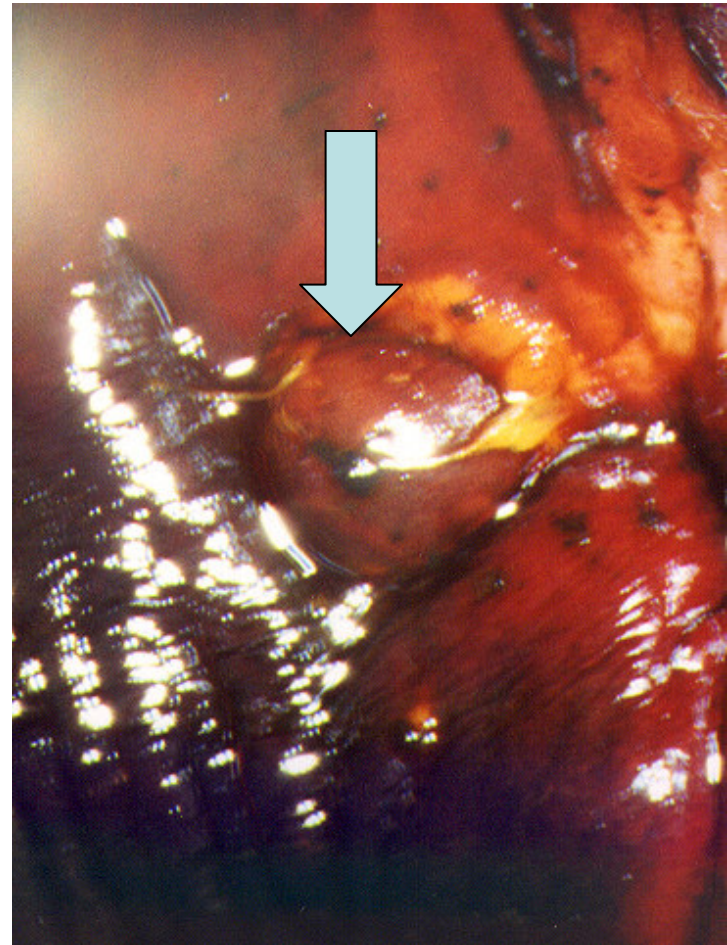
Unsatisfactory colposcopic finding - SCJ not visible

- Unsatisfactory colposcopic finding - SCJ not visible
- Polypoid, vulnerable tumor in the external cervical orifice - *down arrow*



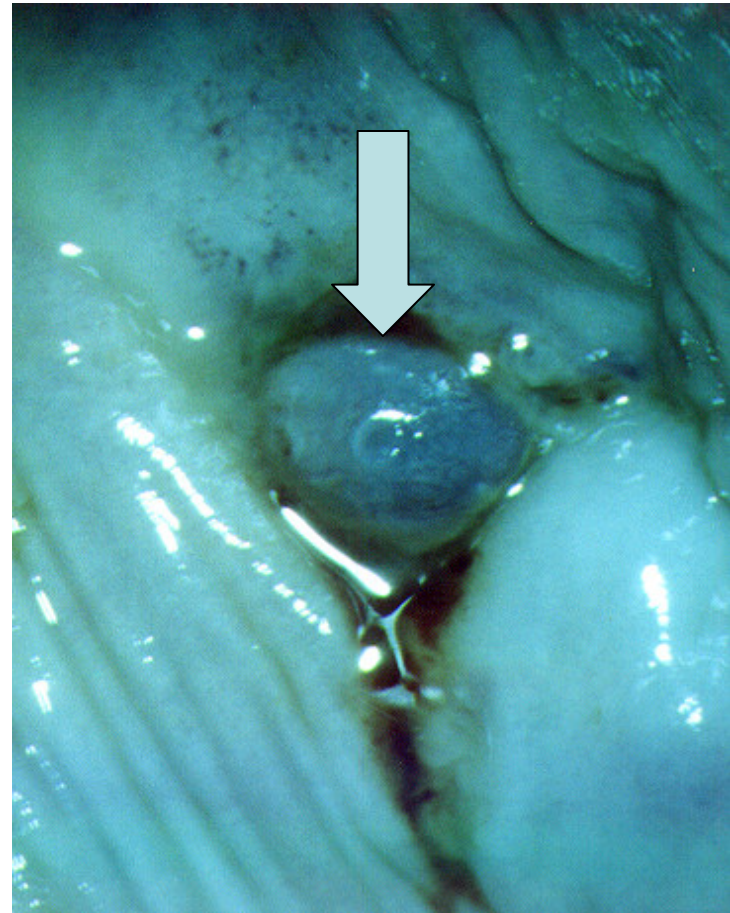
Unsatisfactory colposcopic finding - SCJ not visible

- Unsatisfactory colposcopic finding - SCJ not visible
- Polypoid, vulnerable tumor in the external cervical orifice - *down arrow*



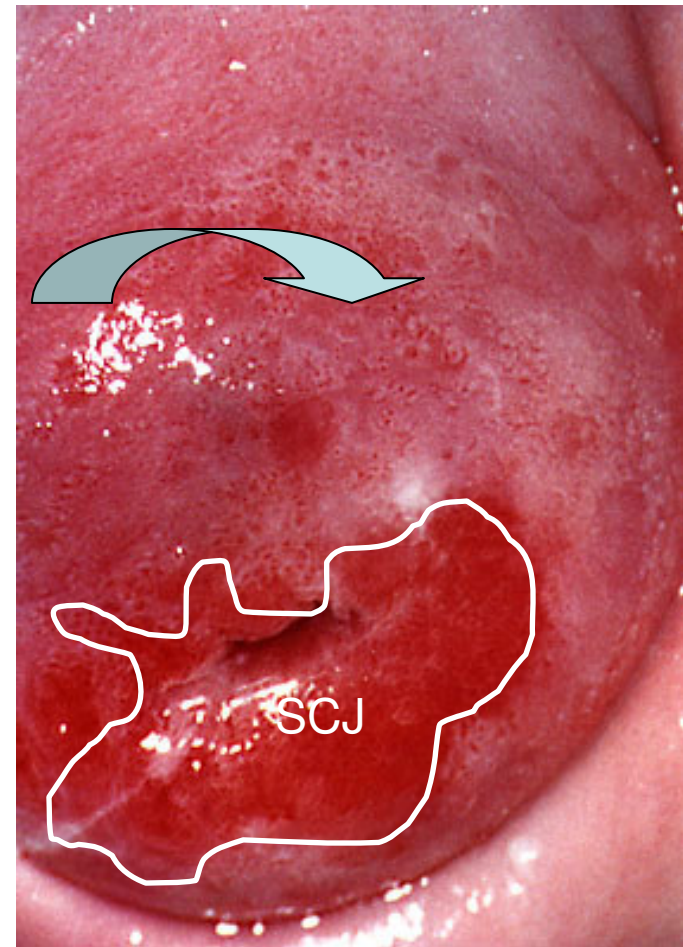
Unsatisfactory colposcopic finding - SCJ not visible

- Unsatisfactory colposcopic finding - SCJ not visible
- Polypoid, vulnerable tumor in the external cervical orifice - *down arrow*



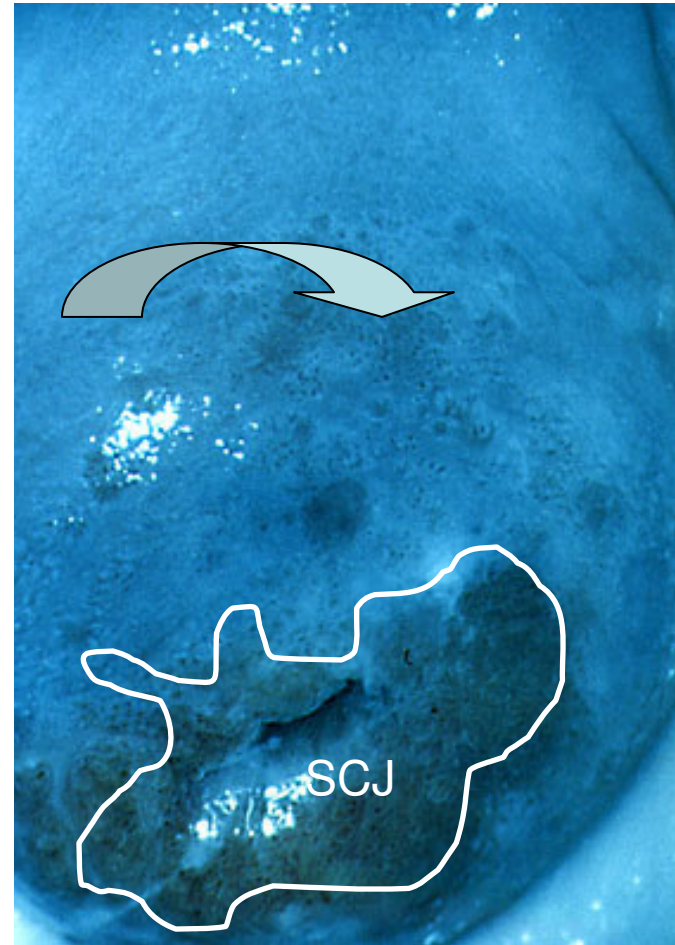
What is this?

- At the beginning of my education I presumed this was coarse punctation – *curved down arrow*
- But...



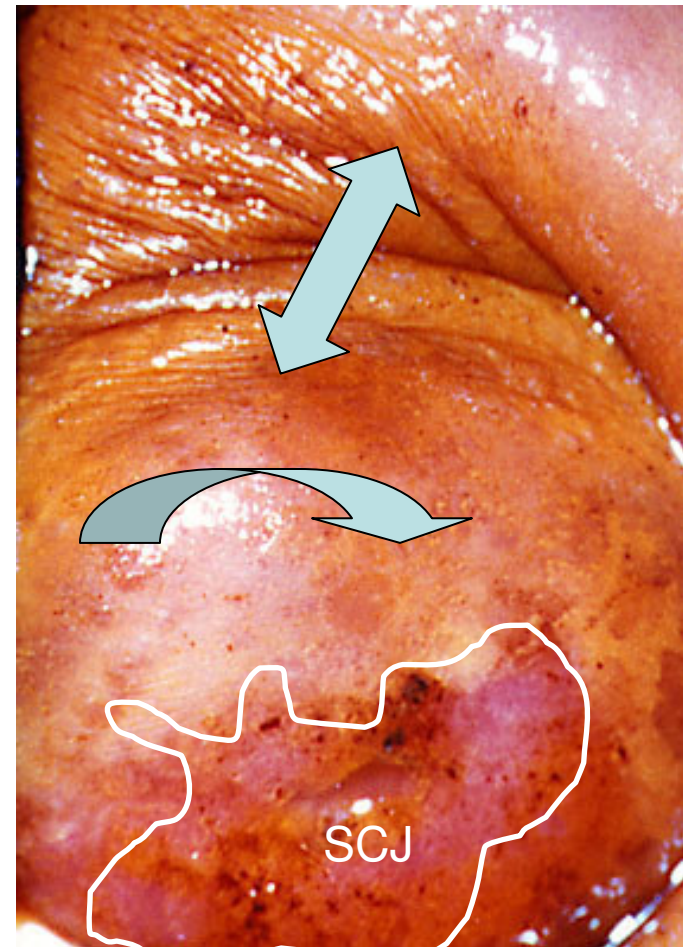
What is this?

- At the beginning of my education I presumed this was coarse punctuation – *curved down arrow*
- But...



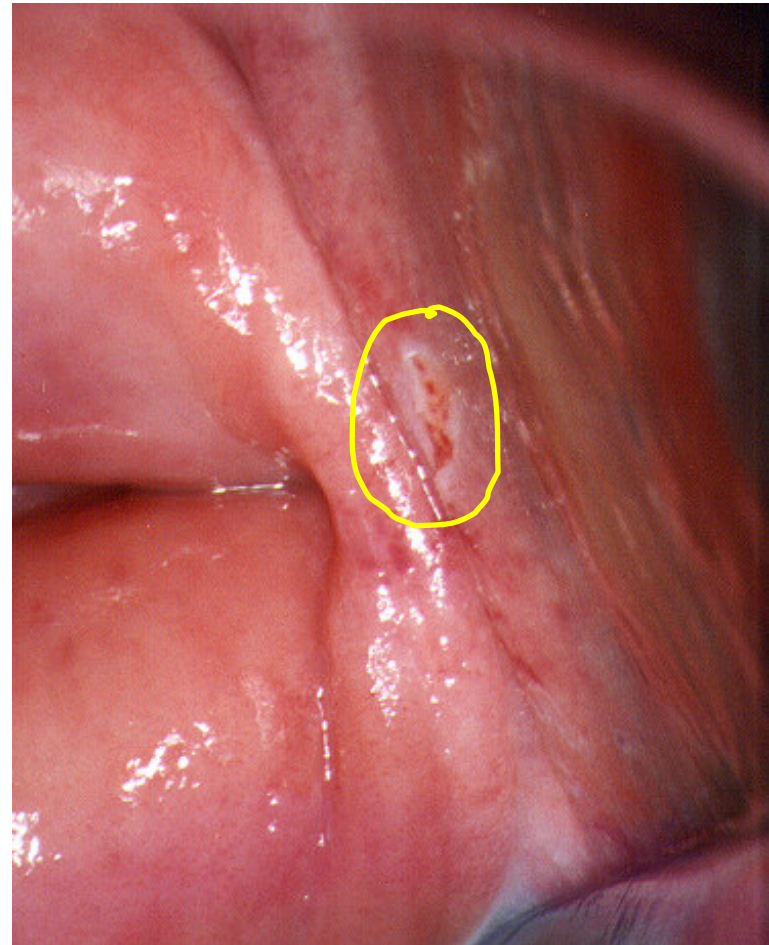
What is this?

- At the beginning of my education I presumed this was coarse punctation – *curved down arrow*
- But... after iodine test there were large iodine negative areas (*curved down and up down arrow*) both on the uterine portio, as well as in the anterior vaginal vault,
- punch biopsy showed acanthosis and inflammation



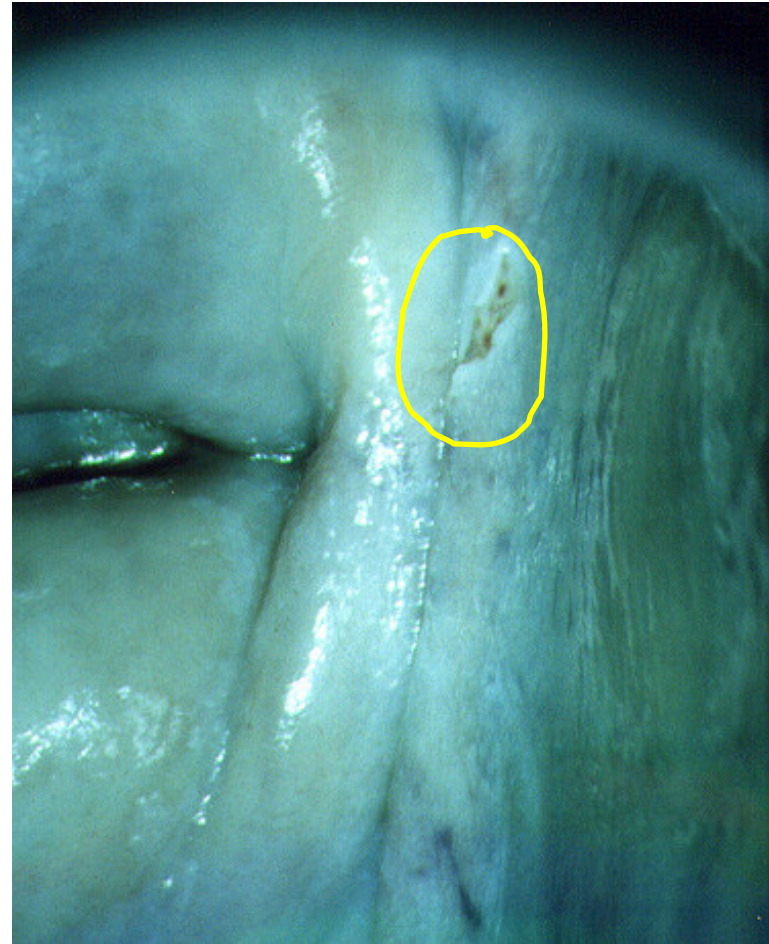
Ulcus laquearis sinistri

- Ulcerous change in the lateral upper third vaginal vault - *yellow scribble area*



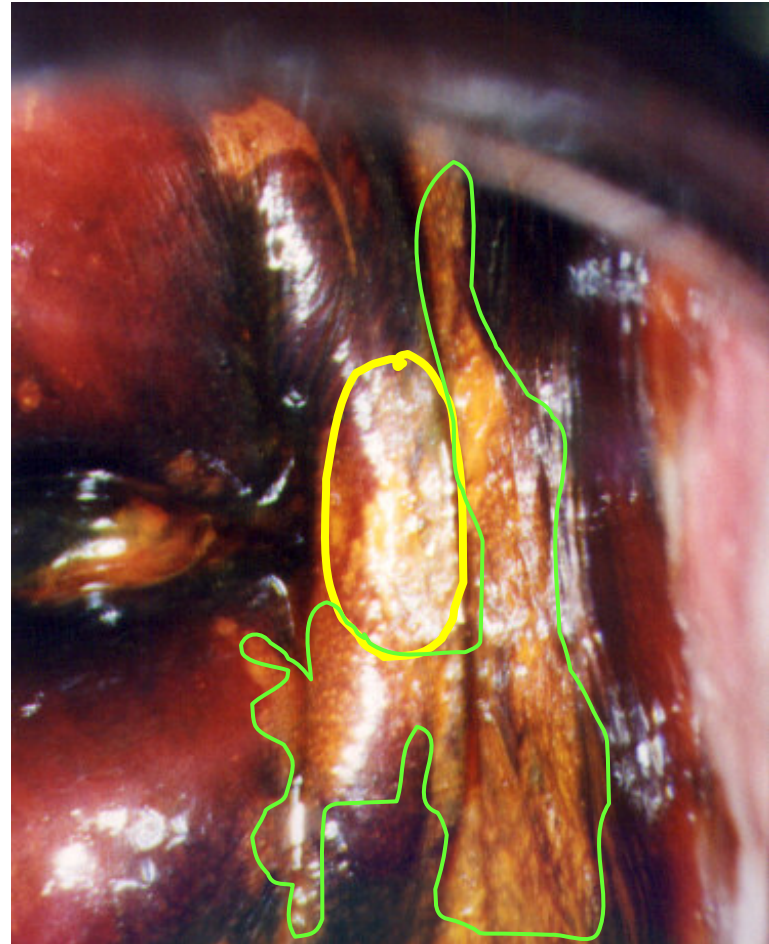
Ulcus laquearis sinistri

- Ulcerous change in the lateral upper third vaginal vault - *yellow scribble area*



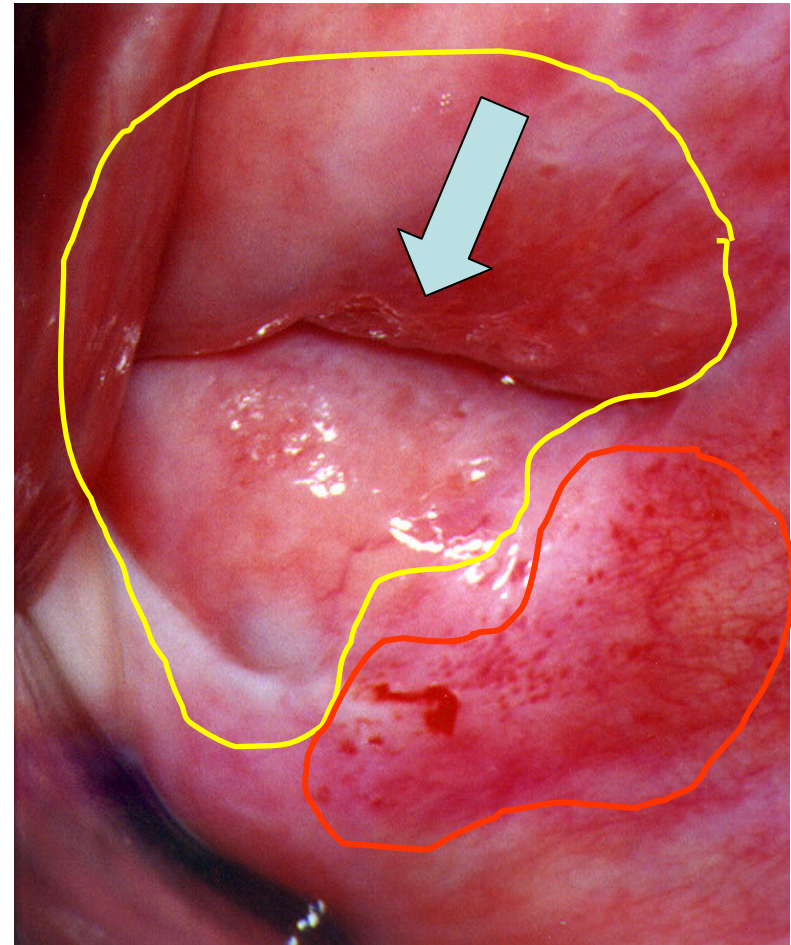
Ulcerus laquearis sinistri

- Ulcerous change in the lateral upper third vaginal vault - *yellow scribble area*
- Iodine test also showed adjacent iodine negative areas, mild VAIN - *light green scribble*



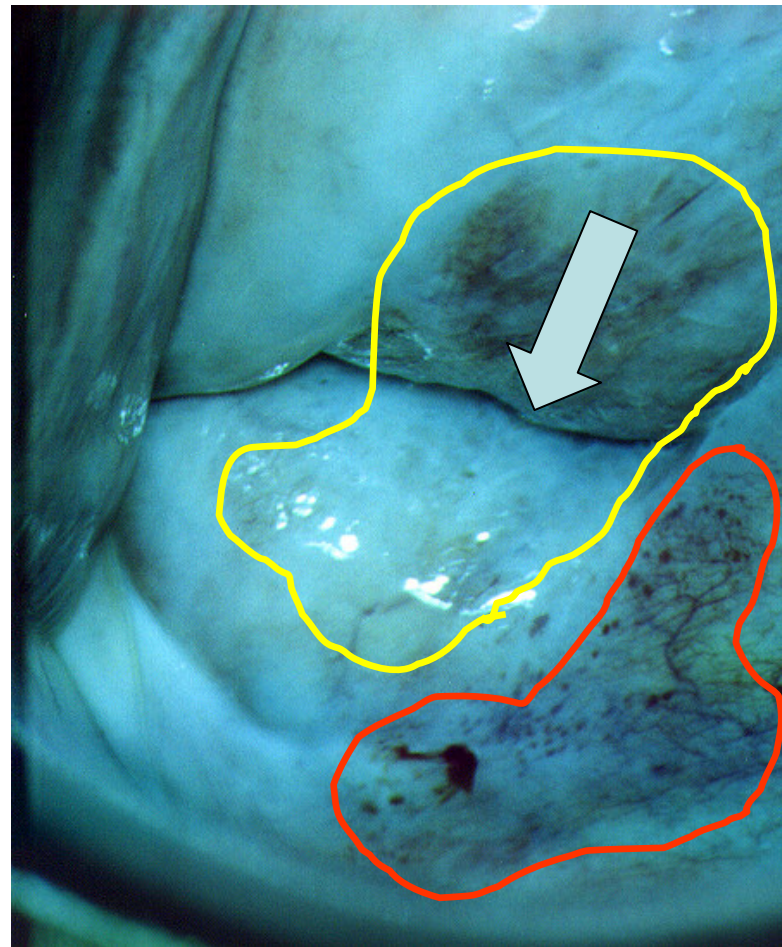
Inflammatory pattern of the uterine cervix coat

- SCJ not visible - *down arrow*
- The whole cervical surface as well as the adjacent vaginal vault demonstrate inflammatory change (*yellow scribble area*), reddish and vulnerable tissue - *red scribble area*



Inflammatory pattern of the uterine cervix coat - Kraatz green filter

- SCJ not visible - *down arrow*
- The cervical surface demonstrates inflammatory change (*yellow scribble area*), reddish and vulnerable tissue and better visible vascular inflammatory hypertrophy - *red scribble area*



Inflammatory pattern of the uterine cervix coat - Schiller's iodine test

- Non-homogenous slight iodine captation (*quad arrow*) as a sign of disturbed glycogenogenesis in inflammation-affected epithelium

