


Clinical utility of vinblastine therapeutic drug monitoring for the treatment of infantile myofibroma patients: A case series

Vickyane Carruthers^{1,2} | Shelby Barnett¹ | Rebecca Rees¹ | Tasnim Arif² |
Olga Slater³ | Ramya Ramanujachar⁴ | Katie Johnson⁴ | Sarah Brown⁴ |
Catherine Graham⁵ | G.A. Amos Burke⁶ | Gareth J. Veal¹ 

¹Newcastle University Centre for Cancer, Newcastle University, Newcastle upon Tyne, UK

²Great North Children's Hospital, Newcastle upon Tyne, UK

³Great Ormond Street Hospital, London, UK

⁴Southampton General Hospital, Southampton, UK

⁵Clinical School, University of Cambridge, Cambridge, UK

⁶Cambridge University Hospitals NHS Foundation Trust, Addenbrooke's Hospital, Cambridge, UK

Correspondence

Gareth J. Veal, Newcastle University Centre for Cancer, Medical School, Newcastle University, Paul O'Gorman Building, Newcastle upon Tyne NE2 4HH, UK.
Email: G.J.Veal@ncl.ac.uk

Abstract

Infantile myofibroma is a rare, benign tumour of infancy typically managed surgically. In a minority of cases, more aggressive disease is seen and chemotherapy with vinblastine and methotrexate may be used, although evidence for this is limited. Chemotherapy dosing in infants is challenging, and vinblastine disposition in infants is unknown. We describe the use of vinblastine therapeutic drug monitoring in four cases of infantile myofibroma. Marked inter- and inpatient variability was observed, highlighting the poorly understood pharmacokinetics of vinblastine in children, the challenges inherent in treating neonates, and the role of adaptive dosing in optimising drug exposure in challenging situations.

KEYWORDS

infantile myofibroma, neonate, pharmacokinetics, therapeutic drug monitoring, vinblastine

1 | INTRODUCTION

Infantile myofibroma (IM) is the commonest fibrous tumour of childhood, typically occurring in the first 2 years of life.^{1,2} It is a benign lesion and spontaneous regression occurs frequently.^{2,3} Where the lesion is amenable to surgical resection, the prognosis is excellent, even with incomplete resection.^{3,4} However, in multifocal lesions, those with visceral involvement, or inoperable solitary lesions, together comprising 15%–20% of cases, morbidity and mortality have been described.^{1,2,5} Chemotherapeutic management of such cases is not standardised, with varying approaches described in case studies, including vinblastine and methotrexate, vincristine, dactinomycin and cyclophosphamide,

and tyrosine kinase inhibitors.^{2,4–7} Vinblastine and methotrexate are used widely in other fibrous tumours, with minimal long-term toxicity reported.^{8,9}

While vincristine pharmacokinetics are relatively well characterised in children, including neonates,¹⁰ vinblastine is less well understood.¹⁴ Vinblastine exhibits high inter- and inpatient pharmacokinetic variability in adult populations but there is currently no published data on drug disposition in children.^{11,12} Dosing of all chemotherapeutics in neonates is challenging, due to marked physiological changes impacting drug clearance, which can lead to variable drug exposures.^{13–15} Empiric dose reductions are therefore commonly advised, without strong clinical pharmacologic data to support dosing decisions made.^{13–15}

We investigated the potential for therapeutic drug monitoring (TDM) to guide treatment in this challenging clinical situation, while

Abbreviations: AUC, Area under the plasma concentration-time curve; CL, Clearance; IM, Infantile myofibroma; TDM, Therapeutic drug monitoring; MRI, Magnetic resonance imaging.

This is an open access article under the terms of the [Creative Commons Attribution](https://creativecommons.org/licenses/by/4.0/) License, which permits use, distribution and reproduction in any medium, provided the original work is properly cited.

© 2022 The Authors. *Pediatric Blood & Cancer* published by Wiley Periodicals LLC

generating novel data on vinblastine pharmacokinetics, in four infants receiving vinblastine for IM at different clinical centres.

2 | METHODS

2.1 | Patients

Four infants are reported with an average age at first dose of vinblastine of 3.6 weeks (range 3–5.5). All had normal renal and liver function for age. Concomitant medications had no reported interactions with either vinblastine or methotrexate in any case.

2.1.1 | Case 1

In the first days of life, a term infant was found to have disseminated IM, including subcutaneous, pulmonary and abdominal deposits (Figure 1A). The abdominal disease caused small bowel obstruction and gut failure requiring parenteral nutrition. Weekly vinblastine (initial dose 3 mg/m²) was commenced with methotrexate withheld due to fluid collections in the gut.

2.1.2 | Case 2

A term infant was found to have disseminated IM with nodules involving the stomach, small bowel, bilateral ovaries, mesenteric lymph nodes, lungs, pleura, cerebellum, cardiac muscle, renal parenchyma, bones and multifocal intramuscular soft tissue masses in the thorax, abdomen, pelvis and thighs (Figure 1B). Chemotherapy was initiated with vinblastine (initial dose 0.1 mg/kg) and methotrexate (0.5 mg/kg).

2.1.3 | Case 3

A large tumour of the left upper arm was identified antenatally and confirmed to be IM following premature birth of a child at 36+2 weeks. Nonmutilating surgery was not possible due to replacement of the soft tissues of the entire upper arm and extension to the chest wall (Figure 1C). The infant was clinically unstable due to arteriovenous shunting through the tumour and therefore chemotherapy with vinblastine (initial dose 0.1 mg/kg) and methotrexate (0.7 mg/kg) was commenced.

2.1.4 | Case 4

An infant was diagnosed with multicentric IM at 3 days of age, with subcutaneous, intramuscular, bony, liver and lung disease (Figure 1D and E). They were treated with vinblastine (initial dose 3 mg/m²) and methotrexate (15 mg/m²).

2.2 | Sample analysis

Samples for pharmacokinetic analysis were collected at 0.5, 2 and 6 h post-bolus administration of vinblastine. Plasma was separated from whole blood samples by centrifugation (1200 g, 4°C, 10 min), and samples were stored at –20°C prior to analysis. Quantification of vinblastine levels in plasma samples was carried out using a validated liquid chromatography-mass spectrometry (LC/MS) assay, with a lower limit of quantification (LLOQ) of 0.5 ng/ml. A non-compartmental pharmacokinetic analysis of the data was performed using WinNonlin version 8.1 (Certara, Princeton, NJ, USA) to determine the maximum vinblastine plasma concentration (C_{max}), area under the plasma concentration-time curve (AUC) and clearance (CL). Inter- and inpatient variability was assessed using the coefficient of variation (CV%). Methotrexate levels were not measured at the discretion of treating clinicians.

3 | RESULTS

Table 1 shows the pharmacokinetic parameters observed for the four case subjects, with summary vinblastine plasma concentration–time data provided in Figure S1. Intra-patient variability was high for all parameters, ranging between 7% and 84% (CV), with C_{max} showing the greatest intra-patient variability. Inter-patient variability was difficult to assess due to changes in dose between cycles. However, an eightfold range in vinblastine CL was observed between patients across multiple cycles (2.3–18.7 L/h). This is reflected in the wide range of AUC values observed (19.4–232.6 µg/L·h). No clear relationship between toxicity and exposure was observed. Case subject 1 experienced hyperbilirubinaemia at concentrations of 57.4–128.7 µg/L·h, exposures well tolerated by other patients. Consequently, their dose was decreased by 50%, resulting in a decrease in exposure (19.4–25.2 µg/L·h), however the patient continued to experience excessive toxicity. This infant experienced good partial response in pulmonary and subcutaneous lesions with stable abdominal disease.

Case subject 2 had a dose increase due to good tolerability and obtained a partial response, with drug exposures toward the high end of the range observed across all patients. Case subject 3 had a dose increase based on low drug exposure, with the increase well tolerated. They completed eight cycles of therapy with stable disease before registering for a clinical trial. Case subject 4 required dose reductions of both vinblastine and methotrexate throughout 18 treatment cycles, despite experiencing exposures lower than those tolerated by others (47.1–59.7 µg/L·h). They had good clinical and radiological responses. Treatment is ongoing in three cases.

4 | DISCUSSION

Marked intra- and inter-patient variabilities in vinblastine clearance and exposure observed in this series highlight the challenges in treating

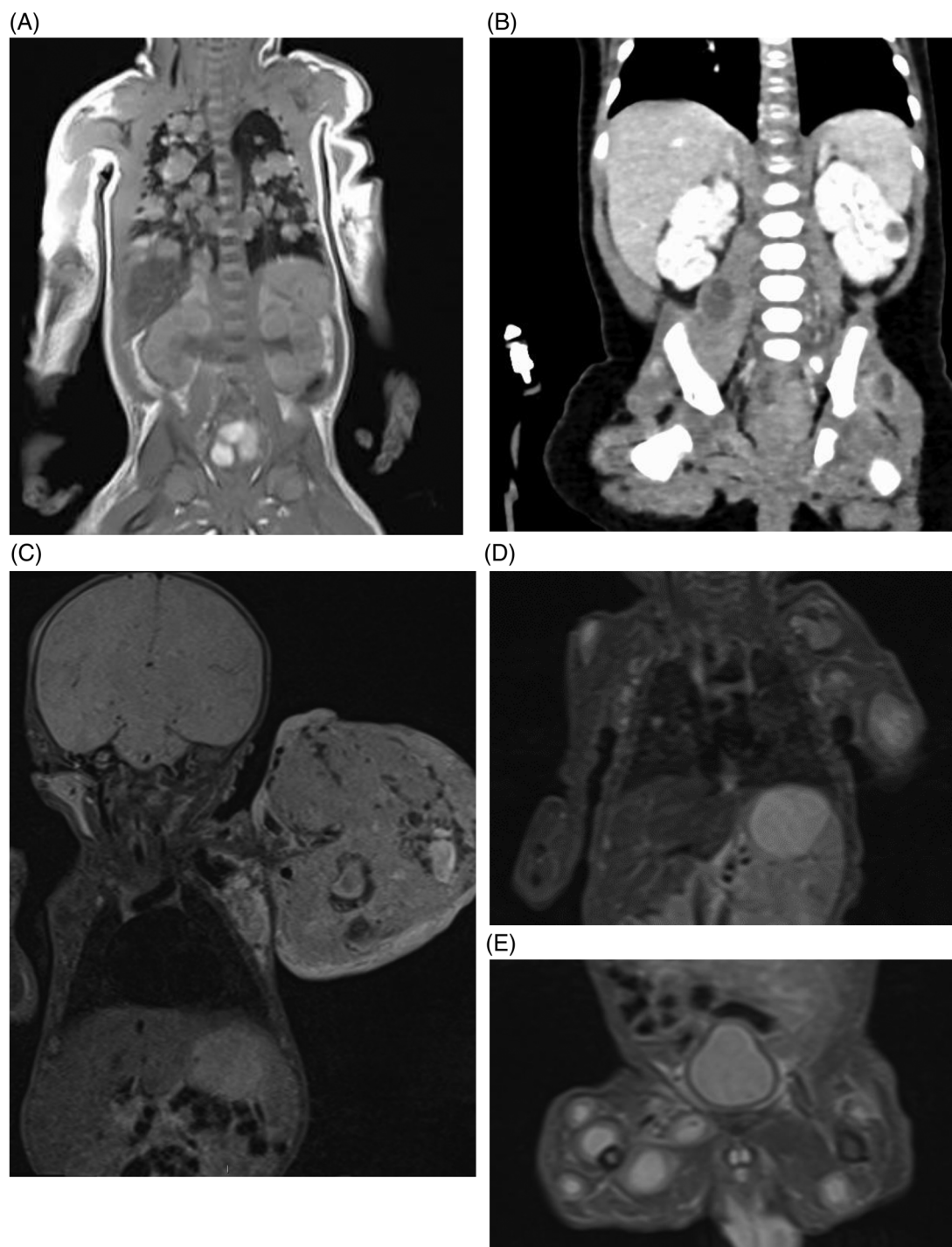

FIGURE 1 MRI images demonstrating extent of disease in each case. (A) Extensive pulmonary disease in case 1, abdominal disease not appreciable by MRI. (B) Renal, retroperitoneal nodal, and intramuscular disease deposits in case 2, following surgical resection of ovarian disease. (C) Large unifocal myofibroma in case 3. (D and E) Extensive subcutaneous disease with pulmonary and liver nodules in case 4

neonates with drugs whose pharmacokinetics are not well established. Infant physiology changes significantly during the first weeks of life, with marked variability in drug exposure previously reported in neonates treated with several chemotherapeutics.^{13–16} It is likely that variability in vinblastine pharmacokinetics observed in adults is amplified in infants due to these physiological changes. While limited published data exist concerning the metabolism of vinblastine in patients,

with desacetylvinblastine the only metabolite identified,¹² the isoenzyme cytochrome P450 3A4 (CYP3A4) has been shown to contribute to its metabolism in human liver microsomes.¹⁷ In addition, vinblastine is known to be transported by P-glycoprotein, encoded by ABCB1.¹⁸ It is therefore possible that changes in the ontogeny of these enzymes affecting expression and activity may impact on drug disposition in the first weeks of life.^{19,20} However, more detailed and expansive clinical

TABLE 1 Vinblastine pharmacokinetic parameters observed in four case subjects

Case	Parameter Dose	PK cycles monitored	Age (weeks)	C_{max} ($\mu\text{g/L}$)	CL (L/h)	AUC_{0-inf} ($\mu\text{g/L}\cdot\text{h}$)	Vz (L)
1	1.5 mg/m ²	2	9–12	7.8–9.5 (14)	16.5–18.7 (9)	19.4–25.2 (18)	43.3–49.5 (9)
	3 mg/m ²	3	3–5	12–51.2 (84)	4.9–11 (38)	57.4–128.7 (47)	10.2–41.5 (57)
2	0.1 mg/kg	6	3–11	28.8–53 (20)	2.3–5.2 (32)	69–174.3 (26)	6.9–15.2 (38)
	0.15–0.2 mg/kg	3	12–32	17.2–60 (61)	7.5–16.2 (45)	70.2–232.6 (62)	21.7–55.9 (52)
3	0.1 mg/kg	1	3	6.48	11.1	26.1	36.9
	0.2 mg/kg	7	4–10	20.9–53.3 (53)	3–9 (43)	70.8–212.7 (55)	11.1–28.5 (35)
4	2.5 mg/m ²	2	8–27	13.9–23.4 (36)	15.9–17.9 (7)	47.1–59.7 (17)	32.6–51.1 (31)

Note: Numbers in parenthesis represent the coefficient of variation (CV %).

Abbreviations: AUC_{0-inf} , area under the plasma concentration-time curve; C_{max} , maximum plasma concentration; CL, clearance, PK, pharmacokinetic; Vz, volume of distribution.

pharmacology studies are required to better understand the pharmacokinetics of vinblastine in infants and children.

With an improved knowledge of the clinical pharmacology of vinblastine, TDM approaches can potentially have a role in optimising drug exposure for rare conditions without established treatment guidelines. In this series, vinblastine starting doses varied from 0.1 mg/kg to 3 mg/m², reflecting the lack of a standardised treatment protocol. Toxicity developed in both patients treated at 3 mg/m², improving with reduced doses, although there was no association with drug exposure. Utilisation of a TDM approach to treatment for the patient exhibiting a low vinblastine exposure, incorporating a dose increase to 0.2 mg/kg, was clinically well tolerated.

The current case series highlights the challenges of diagnosing and treating IM. Indeed, in this respect the diagnosis of IM in case 3 was subsequently modified based on advanced molecular results. The case has been included here based on similar phenotypic features and a clinical decision-making process based on the diagnosis of IM.

5 | CONCLUSIONS

Chemotherapy dosing in infants and neonates is challenging, particularly for drugs such as vinblastine, where no age-specific pharmacokinetic data exist. Adaptive dosing can potentially have a role to play in optimising drug exposure in rare conditions without established treatment guidelines, even in the absence of a defined therapeutic window, but relationships between exposure and clinical response and/or toxicity need to be determined. Marked intra- and inter-patient variabilities in vinblastine exposure were observed in the current study, providing novel clinical pharmacology data in a rare patient population. More expansive, prospective clinical pharmacology studies are required to better understand the disposition of this drug in infants and children. Such an approach will help to support the development of evidence-based vinblastine dosing guidelines in this challenging population.

ACKNOWLEDGEMENTS

The authors thank the clinical centres and the patient's families for allowing presentation of these cases for publication. This work was supported in part by Cancer Research UK, the Experimental Cancer Medicine Centre Network, the Little Princess Trust and the Sir Bobby Robson Foundation.

CONFLICT OF INTEREST

The authors declare that there is no conflict of interest.

ORCID

Gareth J. Veal  <https://orcid.org/0000-0002-1897-8678>

REFERENCES

- Zhao G, Zhu M, Qin C, Liu X, Zhao X. Infantile myofibromatosis: 32 patients and review of literature. *J Pediatr Hematol Oncol*. 2020;42:495-498.
- Sparber-Sauer M, Vokuhl C, Seitz G, et al. Infantile myofibromatosis: excellent prognosis but also rare fatal progressive disease. Treatment results of five Cooperative Weichteilsarkom Studiengruppe (CWS) trials and one registry. *Pediatr Blood Cancer*. 2021;69:e29403.
- Mahajan P, Hicks J, Chintagumpala M, Venkatramani R. Myofibroma in infancy and childhood. *J Pediatr Hematol Oncol*. 2017;39:e136-e139.
- Levine E, Fréneau P, Schleiermacher G, et al. Risk-adapted therapy for infantile myofibromatosis in children. *Pediatr Blood Cancer*. 2012;59(1):115-120.
- Bidadi B, Watson A, Weigel B, Oliveira A, Kirkham J, Arndt C. Treatment of generalized infantile myofibromatosis with sorafenib and imatinib: a case report. *Pediatr Blood Cancer*. 2020;67(6):e28288.
- Weaver MS, Navid F, Huppmann A, Meany H, Angiolillo A. Vincristine and dactinomycin in infantile myofibromatosis with a review of treatment options. *J Pediatr Hematol Oncol*. 2015;37:237-241.
- Proust S, Benchimol G, Freitag S, et al. Major response to imatinib and chemotherapy in a newborn patient prenatally diagnosed with generalized infantile myofibromatosis. *Pediatr Blood Cancer*. 2021;68(1):e28576.
- Skapek SX, Ferguson WS, Granowetter L, et al. Vinblastine and methotrexate for desmoid fibromatosis in children: results of a Pediatric Oncology Group phase II trial. *J Clin Oncol*. 2007;25(5):501-506.

9. Nishida Y, Hamada S, Urakawa H, et al. Desmoid with biweekly methotrexate and vinblastine shows similar effects to weekly administration: a phase II clinical trial. *Cancer Sci.* 2020;111(11):4187-4194.
10. Barnett S, Hellmann F, Parke E, et al. Vincristine dosing, drug exposure and therapeutic drug monitoring in neonate and infant cancer patients. *Eur J Cancer.* 2022;164:127-136.
11. Ratain MJ, Vogelzang NJ, Sinkule JA, Chicago P. Interpatient and inpatient variability in vinblastine pharmacokinetics. *Clin Pharmacol Ther.* 1987;41:61-67.
12. Owellen R, Hartke C, Hains F. Pharmacokinetics and metabolism of vinblastine in humans. *Cancer Res.* 1977;37:2597-2602.
13. Nijstad AL, Barnett S, Lalmohamed A, et al. Clinical pharmacology of cytotoxic drugs in neonates and infants: providing evidence-based dosing guidance. *Eur J Cancer.* 2022;164:137-154.
14. Adamson PC. It's not easy being small. *Pediatr Blood Cancer.* 2010;54:341-343.
15. Veal GJ, Boddy AV. Chemotherapy in newborns and preterm babies. *Semin Fetal Neonatal Med.* 2012;17(4):243-248.
16. Veal GJ, Errington J, Hayden J, et al. Carboplatin therapeutic monitoring in preterm and full-term neonates. *Eur J Cancer.* 2015;51(14):2022-2030.
17. Zhou-Pan XR, Séréé E, Zhou XJ, et al. Involvement of human liver cytochrome P4503A in vinblastine metabolism: drug interactions. *Cancer Res.* 1993;53:5121-5126.
18. Horio M, Gottesman MM, Pastan I. ATP-dependent transport of vinblastine in vesicles from human multidrug-resistant cells. *Proc Natl Acad Sci USA.* 1988;85:3580-3584.
19. de Wildt SN, Kearns GL, Leeder JS, van den Anker JN. Cytochrome P450 3A: ontogeny and drug disposition. *Clin Pharmacokinetic.* 1999;37(6):485-505.
20. Brouwer KLR, Aleksunes LM, Brandys B, et al. Human ontogeny of drug transporters: review and recommendations of the pediatric transporter working group. *Clin Pharmacol Ther.* 2015;98(3):266-287.

SUPPORTING INFORMATION

Additional supporting information may be found in the online version of the article at the publisher's website.

How to cite this article: Carruthers V, Barnett S, Rees R, et al. Clinical utility of vinblastine therapeutic drug monitoring for the treatment of infantile myofibroma patients: A case series. *Pediatr Blood Cancer.* 2022:e29722. <https://doi.org/10.1002/pbc.29722>