



COMMISSIONED PAPER (NL)

Plumage disorders in psittacine birds - part 1: feather abnormalities

Yvonne R.A. van Zeeland^{1*}, Nico J. Schoemaker¹

SUMMARY

Plumage disorders in parrots represent one of the more common, but also one of the more challenging and frustrating problems that veterinarians dealing with parrots in their daily practice face on a day-to-day basis. Various types of plumage disorders may be identified, including stress marks, damaged or broken feathers, poor feather quality, feather discoloration, feather dystrophy, feather loss and feather damaging behaviour. This first article will deal with plumage disorders that result in feather abnormalities in psittacines, including the most common underlying causes, as well as their diagnostic work-up and treatment.

Keywords: Feathers; Feather disorders; Integument; Parrot; Plumage; Dermatology

This paper was commissioned by FECAVA

Introduction

Feathers are one of the most prominent features of a bird's anatomy that distinguishes them from all other classes of vertebrates. They serve many functions of which the most noticeable is enabling a bird to fly. In addition, feathers also serve an important role in the protection against the elements because of their insulating and waterproofing properties, whereas their colour and pattern may provide camouflage to protect them from predators and/or enable them to communicate with conspecifics (e.g. during courtship and mating). In general, seven types of feathers may be distinguished, each serving its own function (Fig. 1).

These include 1) the long, stiff and asymmetrically shaped flight feathers of the wing (remiges) and tail (rectrices), which help to generate thrust and lift, thereby enabling flight; 2) the contour or covert feathers that line the bird's body and provide streamlining, waterproofing, camouflage and ability to communicate with conspecifics; 3) the small, fluffy down



Figure 1. Feathers of a white or umbrella cockatoo (*Cacatua alba*). The four main types of feathers that can be distinguished in a parrot include: a) tail feathers or rectrices with a symmetrically shaped vane; b) the primary flight feathers or remiges with an asymmetrically shaped vane; c) covert feathers; and d) down feathers. The other feather types (i.e., semiplumes, powder down feathers, filoplumes and bristle feathers) are not depicted here.

¹ Division of Zoological Medicine, Department of Clinical Sciences of Companion Animals, Faculty of Veterinary Medicine, Utrecht University Yalelaan 108, NL-3584 CM, Utrecht.

* Corresponding author E-mail: Y.R.A.vanZeeland@uu.nl

feathers that are located underneath the contour feathers and have an insulating function; 4) the semiplumes, that are slightly larger than down feathers and act as thermal insulation and help to increase buoyancy in aquatic birds; 5) the brittle powder down feathers that shed a fine waxy powder that forms a waterproof dressing for the contour feathers; 6) the long, fine, hairlike filoplumes that serve a proprioceptive function; and 7) the long, stiff bristle feathers that are located around the bird's mouth and eyes which may have a sensory function, similar to a cat's whiskers^[1,2].

Each of these feathers is made up of keratin and can basically be divided into a) a calamus, which is the hollow portion of the shaft that inserts into the feather follicle; b) a rachis, which is the central, solid portion of the shaft to which the vane is attached; and c) a vane, which is the flattened part of the feather that is attached to either side of the rachis and comprises of barbs and barbules that overlap and interlock like zippers, giving the feather its strength and rigidity (Fig. 2). Throughout time,




Figure 2. Feather of a Grey parrot (*Psittacus erithacus erithacus*). In general, each feather consists of a shaft (rachis) to which the vane of the feather is attached. The calamus (or quill) is the hollow, featherless portion of the shaft that is inserted into the feather follicle.

feathers suffer from wear and tear, thereby deteriorating their quality and reducing their ability to insulate and/or enabling the bird to fly. To prevent this deterioration from occurring, feathers are regularly shed and replaced by new ones in a process called moulting.

Various different diseases and disorders may affect the plumage of birds, resulting in poor feather quality, colour changes, malformations, loss of feathers and/or improper moulting. In addition, birds – in particular parrots – are presented commonly with signs of feather damaging behaviour (also referred to as feather plucking or feather picking), which can have a variety of medical and behavioural causes that result in the parrot pulling, biting and/or fraying its own feathers^[3,4].

When confronted with a parrot with feather abnormalities, one should consider that, aside from a primary skin and feather disorder, a more serious, generalized or systemic disorder or a behavioural issue may be present. The list of potential aetiologies is long and includes a variety of infectious, toxic, nutritional, neoplastic, immune-mediated, metabolic, endocrine, behavioural, traumatic and management-related conditions^[5-7]. In order to be able to effectively treat the bird and resolve the problem, it is thus of utmost importance to identify the underlying cause for the feather abnormalities. For this purpose, a full diagnostic work-up is warranted. As a first step, a thorough and comprehensive history needs to be obtained, which includes information on the presenting complaint (e.g. duration, initial appearance, progression, [responses to] previous treatments and presence of pruritus or self-inflicted trauma), husbandry, diet, living conditions, general condition and behaviour of the bird. Next, a full physical examination should be performed, in which attention should not only be paid to the overall condition of the skin, feathers and feather follicles, but also to identifying signs of a potential underlying generalized illness. If specific dermatologic lesions (e.g. nodules, papules, plaques, ulcers and/or exudate) and/or feather abnormalities are present, these should be examined closely and classified according to their type, localization and distribution. Dependent on the findings during the physical examination, diagnostic work-up may furthermore include a complete blood count and plasma biochemistry, faecal cytology including wet mount, diagnostic imaging (ultrasound, radiographs, CT imaging or MRI) and/or endoscopy to identify or exclude presence of a systemic illness or organ dysfunction (Table 1). In addition, specific tests may be performed to identify presence of a specific

Table 1. Diagnostic tests that may be performed in birds with feather abnormalities

Diagnostic test	Indications
CBC & Biochemistry	Hepatopathy, nephropathy, generalized infection or inflammatory process, diabetes mellitus, hypocalcemia
Toxicology	Suspected lead or zinc toxicosis. Collect heparinized whole blood (lead) or plasma/serum in non-rubber plastic or glass tubes
TSH stimulation test	Hypothyroidism
Faecal cytology (incl. wet mount and/or flotation)	Giardiasis (common in cockatiels), helminth infection, candidiasis, macrorhabdus ornithogaster infection (avian gastric yeast), bacterial gastroenteritis
Radiology	Heavy metal intoxication, reproductive disorder (e.g. egg binding), hepato-, spleno- or renomegaly, proventricular dilatation disease, pneumonia, airsacculitis, neoplastic conditions, musculoskeletal disease (e.g. osteoarthritis, osteomyelitis, fractures, osteosarcoma)
Ultrasound	Hepatomegaly, reproductive disorders (e.g. egg peritonitis, cystic ovary), neoplastic conditions, cardiac disease, ascites
Endoscopy	Air sacculitis, hepato- or nephropathy, splenomegaly, pancreatic disorders, reproductive disease
Skin scrapings	Ectoparasites, in particular mites (e.g. Knemidokoptes)
Impression smear, swab cytology or tape strip	Bacterial or fungal dermatitis, dermatophytosis, Malassezia, Candida, ectoparasites (e.g. feather mites, lice), pox virus
Fine needle aspirate	Skin neoplasia, xanthomatosis, feather follicle cyst, haematoma, bacterial dermatitis or abscess
Feather digest (using potassium hydroxide)	Ectoparasites (quill mites)
Feather pulp cytology	Bacterial or fungal folliculitis, PBFDF or polyomavirus infection, quill mites
Culture	Bacterial or fungal dermatitis, folliculitis
Skin and/or feather follicle biopsy (histopathology)	Various infectious, inflammatory and/or neoplastic skin diseases, e.g. PBFDF, polyomavirus, bacterial and fungal folliculitis, quill mite infestation, xanthomatosis, squamous cell carcinoma, feather follicle cysts
Intradermal skin testing	Hypersensitivity reactions, allergic skin disease. Thus far not found to be reliable due to the bird's diminished reaction to histamine
Tests for specific causative agents	<ul style="list-style-type: none"> • PCR testing on whole blood, feather pulp or tissue for Psittacine beak and feather disease virus (PBFDF) • PCR testing on faecal swab or tissue for presence of Polyomavirus • PCR on cloacal swab/faeces and/or serologic testing for Avian Bornavirus (ABV) • PCR on conjunctival/choanal/cloacal swab and/or serologic testing for Chlamydia psittaci

pathogen, such as PCR on whole blood to screen for presence of circovirus, the virus causing Psittacine Beak and Feather Disease (PBFDF). Other diagnostic procedures that may be used in the medical work-up of a patient with (localized) feather abnormalities and/or skin lesions include (superficial or deep) skin scrapings, fine needle aspirates, tape strip samples, impression smears, feather digest and/or feather pulp cytology, culture and sensitivity

tests and/or histopathological examination of skin and/or feather biopsies (Table 1). When diagnostic work-up fails to identify an underlying medical condition for the feather abnormalities, self-inflicted trauma due to a psychogenic cause may be suspected, which subsequently requires the conduction of an extensive behavioural assessment to identify the triggering events.

The current review will focus on the various types of feather abnormalities that may be noted in parrots and discuss their most common aetiologies as well as the currently available techniques that may be employed in the diagnostic work-up, treatment and prevention of these disorders.

Stress Marks

Stress marks, also referred to as stress lines or stress bars, are translucent lines across the vane of a feather (Fig 3). They are generally oriented perpendicular to the shaft and represent segmental dysplasia that occurred in the developing barb and barbules due to a brief period of dysfunction in the epidermal collar from which the feather arises. Any type of disease or condition resulting in stress (e.g. due to transport, restraint, nutritional deficiencies, food deprivation or environmental stressors) that occurs at the time that a feather is growing will be able to induce these lesions^[5,8,9]. Similarly, administration of exogenous corticosteroids during feather growth may induce such lesions^[5]. Particularly in neonates, stress marks are a common finding as their feeding schedule is disrupted during the weaning process.

Stress marks may be readily identified upon spreading the wing and/or tail feathers and holding them against the light. Their clinical relevance is largely dependent on the extent to which they are present in a bird and the bird's general condition. A few stress marks in an otherwise healthy bird may merely have (temporary) aesthetic consequences and thus be of limited importance, whereas larger numbers of stress bars may be cause for concern and warrant further investigation to identify the underlying cause. The latter is often difficult as the marks



*Figure 3. Stress marks in the feather of a Blue and Gold macaw (*Ara ararauna*). These translucent lines in the vane of a feather are generally oriented perpendicular to the shaft and may develop in a growing feather during a transient period of stress or disease.*

are the result of a problem during feather development in the past and the inciting event does not need to be present anymore. However, if the underlying cause can be identified and eliminated or corrected, the abnormalities will generally resolve when the old, affected feathers are replaced by new ones during the next moult.

Broken or abraded feathers

Broken or abraded feathers are a relatively common finding in caged birds (Fig. 4). Particularly the primary flight feathers, alula and carpal coverts and tail feathers are easily damaged^[5]. Often, this damage is the result from errors in management, such as housing the bird in a small or overcrowded cage, or in a cage in which perches are too close together. Feather damage may furthermore be self-inflicted (see paragraph feather damaging behaviour) or occur due to trauma, e.g. during restraint, transport or crash landings, which are particularly common in parrots that are trimmed too aggressively. Other predisposing factors include malnutrition (particularly mineral [e.g. calcium, zinc, selenium, magnesium, manganese] and amino acid deficiencies) and/or stress which may result in weakening of the feathers, which are subsequently more prone to wear and tear^[5,9]. To identify the potential underlying causes for the trauma, a thorough anamnesis is necessary, whereas a dermatologic examination may help to identify whether an improper wing trim or other feather abnormalities, resulting in a weakened feather (e.g. stress bars) are present. Elimination of the predisposing factors may help to prevent problems in future, but a moult is necessary to shed the damaged feathers. This usually does not pose a huge problem as the consequences are often merely aesthetic, but occasionally the damage may be so



*Figure 4. Abraded flight feathers in a Grey parrot (*Psittacus erithacus erithacus*). In this bird, the damage was self-inflicted and started after a poor wing trim. Note the ragged, split ends of the remaining shaft of the primary feathers.*




Figure 5. Imping technique to repair a primary wing feather in a bird of prey. First, the damaged or broken feather is clipped approximately 15-25 mm distal to the skin using a nail cutter or sharp scissors (a). Next, a donor feather is cut to the same length as the recipient feather, after which both shafts are cleaned out so that a thin bamboo stick fits tightly in the shaft (b). Using superglue, the two ends are subsequently glued together. Paper is placed underneath the imping site to prevent glue exposure to the adjacent feathers (c). Once connected and before the glue dries, the donor feather is rotated to achieve proper positioning (d).

severe that it results in difficulties with e.g. flight and balance. In such cases, the damaged flight feathers may be repaired using a technique called imping (Fig 5a-d). During the procedure, which is commonly used in falconry, donor feathers (preferably of the same bird or a healthy conspecific) are attached onto the hollow shaft of the damaged feather by the use of small splints^[10]. Although the technique may be effective to restore the functionality of the feather in cases of iatrogenic damage, its use in birds with self-inflicted damage is more controversial and is advised primarily to remove the stimulus to chew at the cut ends of (poorly) clipped feathers^[10]. Whereas damage to most feathers is primarily aesthetic, damage to newly emerging pin or blood feathers may be more problematic as this can result in severe haemorrhage (Fig. 6). Electrocautery or using caustic substances (e.g. silver nitrate) is not advised in such cases as this may result in damage to the feather follicle, resulting in cessation of feather growth or abnormally growing feathers^[7]. To prevent this from occurring, manual pressure or application of a substance to stimulate coagulation (e.g.

flour) may be used to control the bleeding. Alternatively, the damaged blood feather may be removed by slightly twisting and pulling the feather from its base in the direction of the feather growth, after which firm digital pressure is placed on the follicle until the bleeding has stopped^[7].



Figure 6. Newly emerging pin or blood feather. (Black arrow) Trauma to such feathers may easily result in severe haemorrhage.



*Figure 7. Wild Hyacinth macaw (*Anodorhynchus hyacinthinus*) with an unkempt plumage. The poor plumage quality in this bird may be explained by the fact that this bird (a female) was incubating her eggs. The relative small nesting site (a hollow tree) severely restricts her movements and ability to stretch the wings, thereby easily resulting in feather damage and an overall poor plumage quality. Also note the black discolouration of various covert feathers on the dorsal surface of the wing.*

Poor feather quality

Birds with poor feather quality often present with a ragged, dull, unkempt plumage (Fig 7). This poor feather quality may arise from any condition that prevents a bird from preening, such as the use of Elizabethan collars, neck braces, beak malformations, obesity, arthritis, pathological fractures and other conditions that restrict the bird's movement^[9,11]. Other factors that may negatively affect feather quality include housing conditions (e.g. low humidity, irregular or inappropriate photoperiod, exposure to aerosols or cigarette smoke), ingestion of toxins (e.g. trichothecene), malnutrition (e.g. vitamin A deficiency), feather or quill mites and chronic, systemic illness (e.g. infections, neoplasia, gastrointestinal, hepatic, pancreatic disease)^[9,11-15]. Diagnostic work-up should therefore include a thorough history to identify management errors in housing, care and/or nutrition, combined with a full physical and dermatologic examination to identify presence of parasites or signs of underlying systemic illness. In the

latter case, further diagnostic tests may be performed. Correcting the underlying cause usually will help to improve the feather quality, but one or more consecutive moults may be required to completely resolve the issue.

Malnutrition

Malnutrition is one of the most commonly encountered problems in captive psittacines. Many birds are still fed on all-seed diets which are deficient in a number of nutrients, including vitamins (e.g. vitamins A, D, K, B12, riboflavin, pantothenic acid, choline, niacin), minerals (e.g. calcium, phosphorus, sodium), trace elements (e.g. manganese, zinc, iron, iodine, selenium), and essential amino acids (particularly lysine and methionine) and fatty acids (omega-3 fatty acids) ^[14-17]. Many of these nutrients, such as essential amino and fatty acids, copper, zinc, vitamins A, B and E, are important for normal feather growth^[18,19]. As a consequence, the normal moulting process may be delayed or interrupted in birds which are fed an imbalanced or deficient diets and may thereby give rise to development of depigmented or discoloured, poor quality feathers that break easily and have a dull, ragged-looking appearance (Fig. 8) ^[14,20]. Other signs of malnutrition include thickening and scaling of the skin, especially on the face, feet and legs^[14,15]. Birds may furthermore be predisposed to develop skin infections and inflammation as a result of deficiencies, particularly hypovitaminosis A (Fig. 9) ^[14,15]. Although abnormalities are seldom specific, an underlying nutritional component should be suspected in any abnormally feathered bird that is primarily fed seeds. In such cases, treatment should at least be aimed at correction of the malnutrition and may include administration of multivitamin injections (5,000-20,000 IU/kg IM; based on vitamin A content), oral administration of supplements and conversion to a complete (pelleted) diet.

Feather or quill mites

Birds are host to a variety of different mites that may inhabit the skin and/or feathers^[13]. Quill mites predominantly live and reproduce inside the feather quills where they feed on the available tissue and secretions^[13]. Although many different species have been identified (e.g. *Syngophilus*, *Dermoglyphus*, *Pterolichus*, *Analges* and *Harporhynchus* spp.), quill mites are a relatively uncommon cause for feather abnormalities in parrots^[7,9]. When present in large numbers, they may cause damage



Figure 8. Amazon parrot (*Amazona* spp.) with a severely abnormal plumage resulting from chronic malnutrition. Note the feather discoloration and depigmentation as well as the overall dull- and ragged looking plumage of this bird. Surprisingly, the bird was not presented for these feather abnormalities, but rather for the presence of a tumour of the uropygial gland, which turned out to be a squamous cell carcinoma.

to the feathers by destroying the medulla from the quill to the rachis. Affected quills tend to break or bleed easily and may change in appearance from transparent to opaque. Although most quill mites primarily feed on the keratin and medulla of the feather quills, quill wall mites (e.g. *Syringophylus* spp.) primarily feed on feather follicle fluid and outer, unkeratinized layers of the feather germ of developing feathers, thereby triggering hyperkeratosis of the feather sheath.

Feather mites (e.g. *Protolichus*, *Dubininia* spp.) live between the barbs of the contour, wing and tail feathers and primarily feed on the feather fragments and skin debris^[13]. Feather mites are generally considered apathogenic, but may cause problems when present in high numbers, non-host adapted species or birds with a compromised immune system^[21]. The mites, which may be identified as tiny dark spots of grains of sand on the

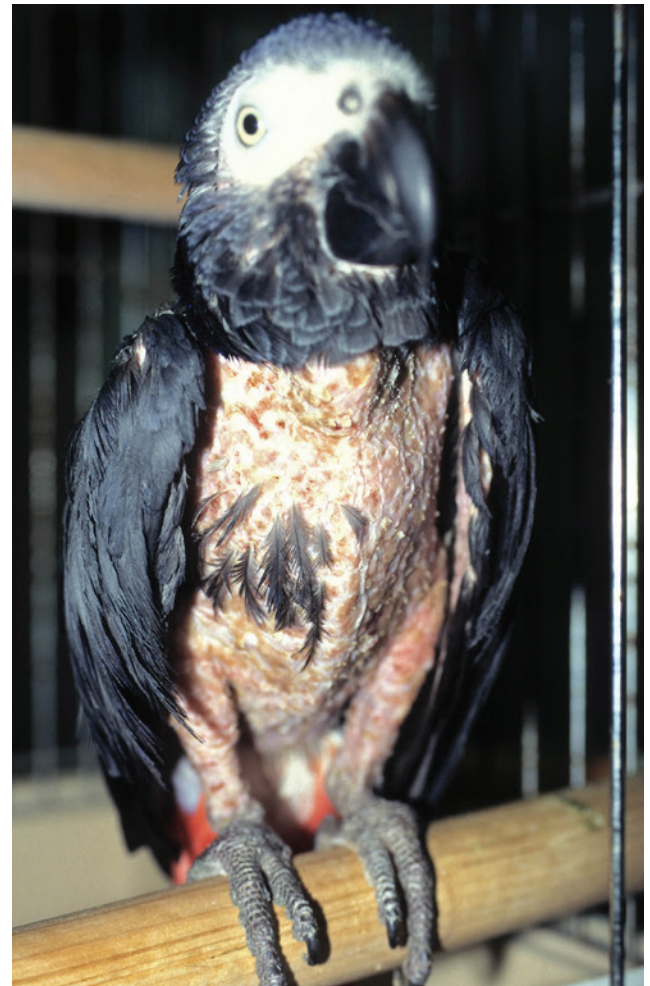

Figure 9. Grey parrot (*Psittacus erithacus erithacus*) with *Klebsiella dermatitis*. The bird was fed an all-seed diet, which probably predisposed the bird to the development of secondary infections. As a sequel to the dermatitis, the bird started to pluck its feathers, but fortunately the plucking ceased after treatment with antibiotics and conversion to a pelleted diet.

ventral surface of feathers, may cause irritation (leading to feather damaging behaviour) and induce feather lesions such as darkened areas, dots or stripes on bright feathers or bright dots and stripes on dark feathers.

Feather and quill mites are usually detected upon microscopic examination of the pulp and/or vane of a damaged or developing feather (Fig. 10). They can usually be treated effectively with ivermectin (0.2 mg/kg PO or IM for a minimum of two treatments given 10-14 days apart), selamectin (25 mg/kg topically q3-4 weeks), moxidectin (0.2-0.5 mg/kg orally) and/or topical acaricides (e.g. permethrin, pyrethrin, fipronil)^[9,13,21].

Abnormal colouration of feathers

Feathers derive their colouration from pigments (melanins, porphyrins and carotenoids) and/or structural conditions

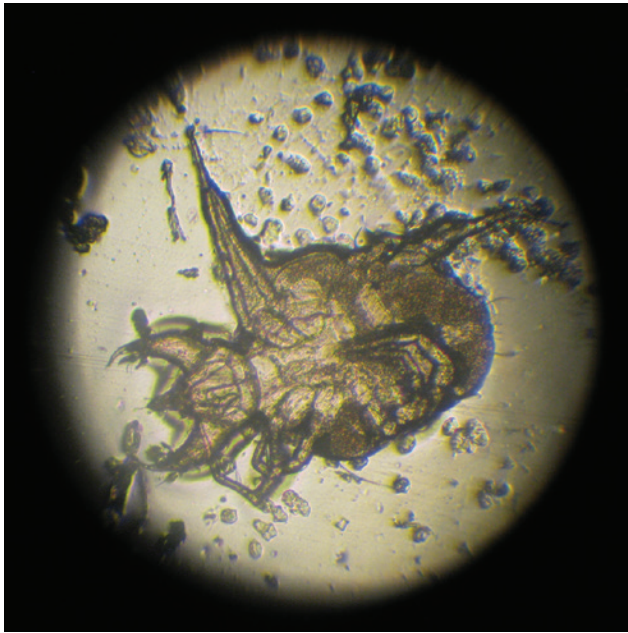


Figure 10. Feather mite, found in a Turquoise parrot (*Neophema pulchella*) with poor feather condition.



Figure 11. Black discoloration of the feathers due to chronic malnutrition in a conure

of the feather that modify or separate the components of white light^[2]. As a consequence, any condition resulting in a change of the feather structure may also result in a change of colour. Changes in colouration of the feathers may be localized or generalized. The most common cause for a generalized change in feather colour is malnutrition (Fig. 11). A lack of dietary carotenoids, which give rise to the yellow, orange and red colours in the plumage, results in a muted feather colour^[14]. Colour changes may also result due to low levels of non haem iron, which is needed for production of porphyrins that give rise to green and reddish colouration, or due to tyrosine and/or copper deficiencies which results in impaired melanin production and causes the feathers to become lighter^[14]. Achromatosis (loss of colouration) of the primary feathers has furthermore been found to occur in cockatiels when fed choline or riboflavin deficient diets^[15]. In such cases,



Figure 12. Reddish discoloration of the feathers on the chest in a peach-faced lovebird (*Agapornis roseicollis*).

correction of the malnutrition by conversion to a complete, pelleted diet may result in a change of colour back to normal after the subsequent moult.

Other causes of generalized feather discoloration include liver disease, chronic lead toxicosis, hypothyroidism, neoplasia (e.g. pituitary tumour), drug administration (e.g. thyroxine, fenbendazole), early circovirus infection (feather dystrophy) and genetic mutations (Fig. 12). Localized colour changes involving a single or few feathers, in contrast, are most likely the result of a localized inflammatory process or trauma that affected the feather follicle during its development.

Feather cysts

Feather cysts usually present as oval or elongated lumps or masses in which a yellow-whitish material (keratin) accumulates (Fig. 13). Although these lesions can appear anywhere on the body, they are most commonly found on the wings. Particularly the soft-feathered canary breeds such as Gloucester and Norwich appear prone to developing feather cysts thereby raising suspicion of a



Figure 13. Norwich canary (*Serinus canaria*) with a feather follicle cyst. Particularly soft-feathered breeds are prone to developing such cysts, which are filled with white-yellowish keratinaceous material.

hereditary condition^[22]. The condition may, however, also incidentally be encountered in parrots and parakeets. In these species, the cysts most often represent an acquired condition which may be the result of an infection, trauma or other condition that interferes with the normal feather growth^[5,6]. Diagnosis is usually based on the clinical signs and appearance of the mass. Cytology of the mass may reveal erythrocytes, erythrophagocytosis, mixed-cell inflammation with a marked amount of background debris, multinucleated giant cells and/or presence of feather fragments. Surgery is often indicated to treat these cases, especially in those cases in which self-mutilation and/or (secondary) infections are present, and may involve curettage or surgical excision of the feather cyst, or of the whole feather tract, if multiple cysts are present^[23].

Folliculitis

Folliculitis (inflammation of the feather follicles) is a condition that may develop due to (secondary) bacterial and/or fungal pathogens. Pathogens that have been implicated in folliculitis include *Staphylococcus* spp., *Aeromonas* spp., *Mycobacterium* spp., *Aspergillus* spp. and *Malassezia* spp. ^[7,24,25]. Grossly, the lesions are characterized by presence of perifollicular swelling and erythema, but hyperkeratosis, crust formation and discolouration of the feathers have also been noted when fungal organisms are involved (Fig. 14) ^[7]. Birds may furthermore show signs of pruritus and/or pain, which may be expressed by restlessness, shivering and/or feather damaging behaviour. To identify presence of a fungal or bacterial organism, an affected feather may be pulled and aseptically opened, after which the pulp may be cytologically examined using specific stains (e.g. Gram's stain) and/or cultured

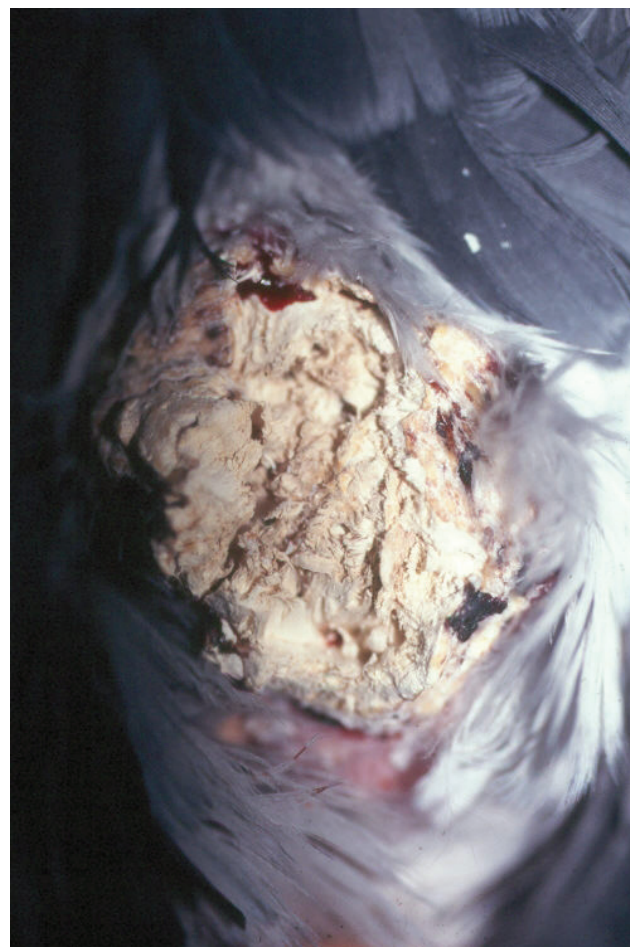


Figure 14. Fungal dermatitis due to *Aspergillus* spp. in a Grey parrot (*Psittacus erithacus erithacus*). Note the hyperkeratosis and crust formation of the skin.

to identify whether and which pathogenic organisms are present. Occasionally histologic examination of feather follicle biopsies may be needed to identify the cause of the folliculitis. In case of bacterial folliculitis, treatment is preferably based on the results of the sensitivity test; in case of fungal folliculitis, antimycotic drugs such as itraconazole, fluconazole, clotrimazole and terbinafine may be used. Prolonged treatment periods of >3 weeks are often needed to effectively eliminate the infection.

Polyfolliculitis

Polyfolliculitis is a condition that is characterized by the appearance of multiple feathers from the same follicle (Fig. 15a and b). The condition is commonly seen in budgerigars, cockatiels and lovebirds and appears to primarily affect the feather tracts of the tail and dorsal region of the neck ^[5,7,26,27]. Newly emerging feathers which arise from the follicle often have short, stout quills with retained sheaths. The condition often results in pruritus, thereby provoking the birds to pluck their feathers and/or automutilate themselves. The exact aetiology remains

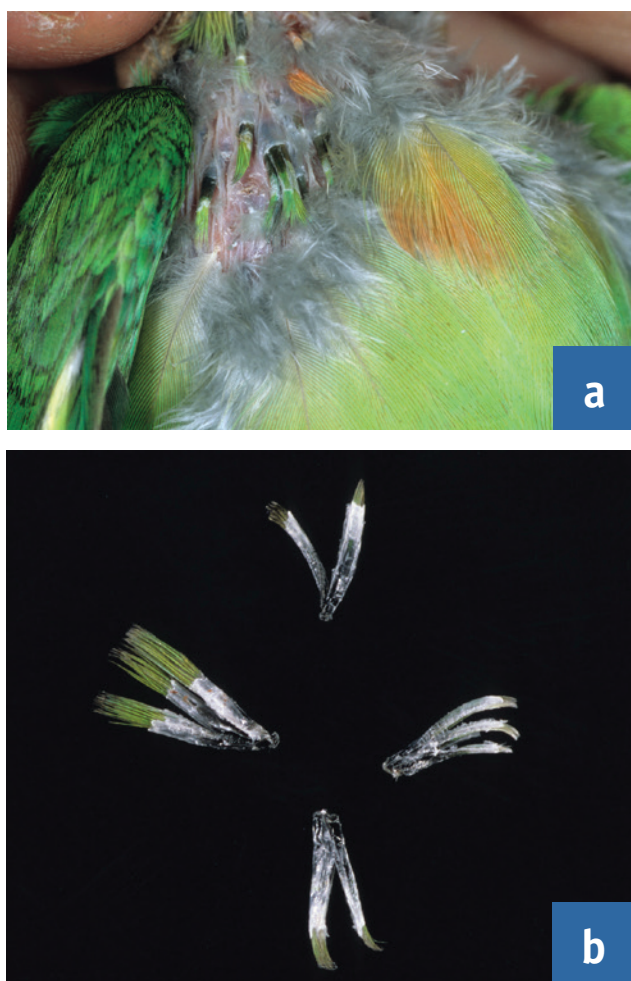


Figure 15. Polyfolliculitis in a lovebird (a). Note the abnormal appearance of the feathers, which often have short, stout quills with retained sheaths (b).

unknown, but viruses such as PBFV-virus, polyomavirus, poxvirus have long been suspected as the potential cause. Diagnosis is usually based on the clinical appearance of the feather follicles, and may be confirmed by histopathological examination of feather follicle biopsies which reveal the presence of multiple feather shafts arising from a single follicle, chronic inflammation beneath the pulp cap and thickening of the feather sheath. Occasionally, large, keratin-filled cysts (feather cysts) may also be noted. Because no definite aetiology has been established, treatment is usually palliative and consists of (manual or surgical) removal of the abnormal feathers, treatment of secondary infections and anti-inflammatory drugs [26].

Feather dystrophy

Feather dystrophy is characterized by the formation of abnormally shaped feathers and may result from direct or indirect damage to the follicular collar or developing feathers. The most common causes for feather dystrophy



Figure 16. Chrysanthemum or feather duster disease in a budgerigar (*Melopsittacus undulatus*).

in psittacine birds include infections with a circovirus that gives rise to the development of PBFV and polyomavirus, which are both discussed below.

In budgerigars, a hereditary condition has also been described [28]. The disease is characterized by a continuous growth of the contour, tail and flight feathers, giving the bird the appearance of a feather duster, hence the name 'feather duster disease' or 'chrysanthemum disease' (Fig. 16). Birds with this condition often appear less alert than nest mates and often cannot fly. There is no treatment for the condition; birds are often euthanized in the nest.

Psittacine beak and feather disease

Psittacine beak and feather disease (PBFV) is caused by a virus of the family Circoviridae and may affect both Old and New World parrots [29,30]. The disease, which is enzootic in Australia and transmitted via oral ingestion or inhalation of infected skin and feather dander, primarily affects juvenile and young adult birds up to 3 years of age. Two syndromes are recognized: 1) an acute form, which occurs predominantly in nestlings and juvenile Grey parrots (*Psittacus erithacus*) and is characterized by the rapid onset of leucopenia and liver necrosis that result in the development of secondary infections and general malaise; birds often die within a week after onset of the clinical signs, without obvious feather lesions present [31], but cases may also be noted in which generalized feather loss is present (Fig. 17) [29,30]; 2) a chronic form which usually becomes apparent when the bird goes through its first moult and the normal feathers are replaced by dystrophic feathers giving rise to progressive and often



Figure 17. Acute PBFD in young Grey parrots (*Psittacus erithacus erithacus*). Feather abnormalities may be generalized, but affected birds, especially young Grey parrots, may also die prior to developing the characteristic feather lesions, as a result of immunosuppression and secondary infections.

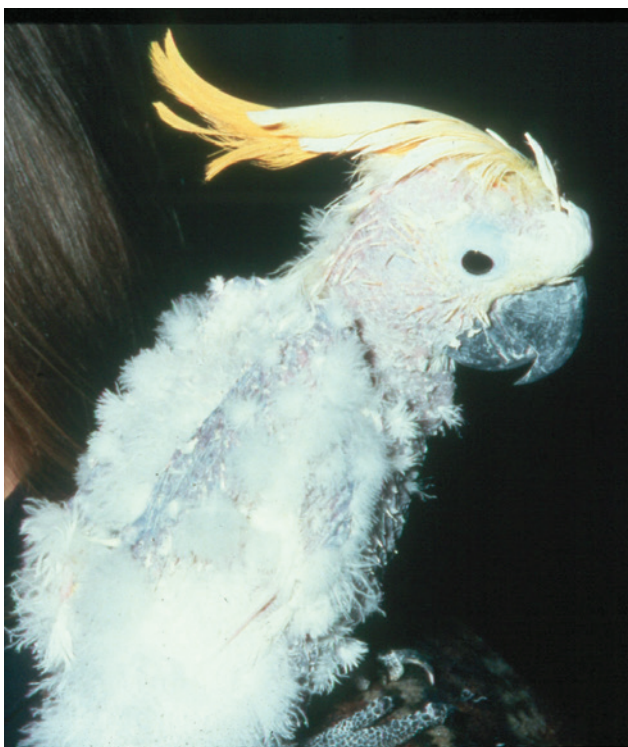

Figure 18. Sulphur-crested cockatoo (*Cacatua galerita*) with chronic feather abnormalities due to PBFD.

bilateral symmetrical feather, claw and beak deformities. The pattern of feather dystrophy may depend on various factors such as the stage of moult that the bird was in at the time of onset of the disease, and the type of parrot species involved^[30,31]. Powder down feathers may be the first affected in cockatoos (*Cacatua* spp.), followed by other types of feathers when the disease progresses, eventually giving rise to a generalized pattern of feather abnormalities and feather loss (Fig. 18)^[7,31]. In other species, feather



Figure 19. Reddish discoloration of the feathers in an adult Grey parrot (*Psittacus erithacus erithacus*) with PBFD.

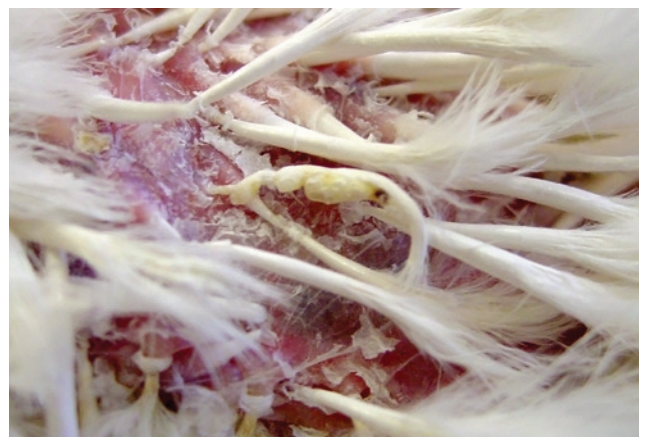

Figure 20. Annular constriction and bending of the feathers in a bird with PBFD.

lesions may be mild and localized (e.g. in lovebirds^[32]), primarily characterized by delayed moult or poor quality feathering (e.g. in Eclectus parrots^[7]) or affect the colouration of feathers (e.g. in Grey parrots, Fig. 19^[33]).

Feather abnormalities commonly seen in PBFD-affected birds generally comprise of one or more of the following: thickened and/or retained feather sheath; haemorrhage within the shaft or pulp cavity; stunting or clubbing of feathers; stress lines across the vanes; annular constrictions of the calamus; curling of the feathers and feather necrosis of both contour and down feathers (Fig. 20). In the later stages, feather development is hampered until eventually all feather growth ceases and the bird becomes progressively bald. In addition to feather changes, beak and claw abnormalities (e.g. overgrowth, malformation, necrosis, fractures and fissures) may also develop^[29,30]. The clinical course of the chronic form of the disease may run from months to years until the birds eventually succumb to secondary infections^[29,30]. A presumptive diagnosis can usually be made based on the distinct clinical features of the disease, but further

diagnostic tests are needed to confirm the diagnosis. A polymerase chain reaction (PCR) on blood, fresh feather pulp or tissue samples is considered the most sensitive method for detecting latent or early infections, but may sometimes yield false-negative as well as false-positive results [7,29,30,34]. In those cases, histological examination of feather follicles (plucked feathers or a feather follicle biopsy) can be used to confirm the disease [7,30]. Other diagnostic tests to confirm presence of the virus include a haemagglutination assay (HA) on feather material, a haemagglutination inhibition test (HI) on blood. Serological testing with the use of HI, or enzyme-linked immunosorbent assays (ELISA) may in particular be useful to detect PBFD-infected flocks and/or demonstrate seroconversion in an individual bird, but not all of these aforementioned tests are available in every country [30]. There is no treatment for PBFD and affected birds may be euthanized once the disease progresses. Although experimental inactivated vaccines are available in Australia these do not prevent infection [35] and prevention is therefore aimed primarily at reducing spread of the disease by maintaining closed flocks, quarantine measures and (repeated) testing. Proper hygiene and disinfection protocols, including the use of glutaraldehyde as a disinfectant, are also recommended to reduce the risk of transmission [30].

Polyomavirus

Polyomavirus can infect all psittacine birds, but most commonly affects budgerigars (*Melopsittacus undulatus*), macaws (*Ara* spp.), conures (*Aratinga* and *Pyrhura* spp.), caiques (*Pionites* spp.), Eclectus parrots (*Eclectus roratus*), Ringneck parrots (*Psittacula* spp.) and lovebirds (*Agapornis* spp.) [7]. Nestling and juvenile birds are most susceptible. In larger psittacine species the virus usually causes an acute, fatal disease in nestlings characterized by subcutaneous haemorrhage, hepatomegaly, anorexia, crop stasis, depression and sudden death without feather abnormalities present [30,36]. In budgerigars, feather dystrophy may develop in the nestlings that survive, similar to that seen in PBFD. This form of the disease, also termed 'French moult' follows a relatively typical pattern: budgerigars less than 2 weeks of age show a lack of powder down on the head and neck; those of 2 to 4 weeks of age show a lack of or incompletely developed flight feathers; and those older than 25 days of age will develop

feathers, but the tail and/or some flight feathers may remain underdeveloped or absent [37]. The failure to develop rectrices and/or remiges generally renders the birds flightless. Often, these individuals are termed 'runners' or 'creepers' (Fig. 21) [7,30,36].



Figure 21. Polyomavirus infection in a budgerigar (*Melopsittacus undulatus*), resulting in a condition called 'French moult'. The primary flight feathers often do not develop in affected juveniles, essentially rendering them flightless. This is why such birds are often called 'runners' or 'creepers'.

A presumptive diagnosis of polyomavirus infection is usually based on the history, clinical findings and pathological features. Definite diagnosis requires serology or PCR testing of cloacal swabs, blood or tissues. PCR is currently the method of choice for many veterinarians. Due to the short viraemia and irregular shedding, however, many false-negative results may be obtained. Definite diagnosis may therefore sometimes require histopathologic examination of tissue samples to identify the presence of basophilic intranuclear inclusion bodies in various tissues (e.g. liver, spleen, kidney and feather follicles), which may be confirmed as polyomavirus using electron microscopy or in situ hybridization techniques [29,30]. Currently, there is no specific treatment for polyomavirus infection. A commercially available polyomavirus vaccine is available in the US to protect nestlings of large psittacines in aviaries in which the virus is endemic [38]. Other measures to control and prevent spread of polyomavirus in the population include hygiene and quarantine measures similar to those discussed for PBFD as well as PCR testing to identify viraemic and/or shedding birds. In addition, temporary cessation of breeding in flocks of affected budgerigars may help to reduce spread of the disease as the disease may be transmitted both vertically and horizontally [36].

Conclusions

A variety of different conditions may affect the plumage of parrots resulting in various feather abnormalities. For all of the disorders a thorough history and medical work-up are needed to identify any underlying causes that should be treated accordingly. Plumage disorders are, however, not restricted to development of abnormal feathers, but also include problems with feather growth, feather loss. Particularly self-inflicted pulling, plucking, biting, chewing or fraying of the feathers (so-called feather damaging behaviour) is commonly seen in parrots. The disorders involving problems with feather loss and feather growth, including feather damaging behaviour will be discussed in part 2 (EJCAP Summer 2014).

References

- [1] King AS, McLelland J. Integument. In: King AS, McLelland J. *Birds: their structure and function*. Baillière Tindall, East Sussex, UK;. 1984. pp. 23-42.
- [2] Pass DA. Normal anatomy of the avian skin and feathers. *Sem Avian Exotic Pet Med*. 1995; 4: 52-160.
- [3] van Zeeland YRA, Spruit BM, Rodenburg TD, Riedstra B, Buitenhuis B, van Hierden YM, Korte SM, Lumeij JT. Feather damaging behaviour in parrots: a review with consideration of comparative aspects. *Appl Anim Behav Sci*. 2009; 121: 75-95.
- [4] Rubinstein J, Lightfoot TL. Feather loss and feather destructive behavior in pet birds. *J Exotic Pet Med*. 2012; 21: 219-234.
- [5] Cooper JE, Harrison GJ. Dermatology. In: Ritchie BW, Harrison GJ, Harrison LR (Eds.). *Avian Medicine: Principles and Application*. Wingers Publishing, Lake Worth, Florida, USA;. 1994. pp. 1165-1169.
- [6] Chitty J. Feather and skin disorders. In: Harcourt-Brown N, Chitty J (Eds.). *BSAVA Manual of Psittacine Birds*, 2nd Edition. British Small Animal Veterinary Association, Gloucestershire, UK;. 2005. pp. 191-204
- [7] Schmidt RE, Lightfoot TL. Integument. In: Harrison GJ, Lightfoot TL (Eds.). *Clinical Avian Medicine*. Spix Publishing, Palm Beach, Florida, USA; 2006. pp. 395-410.
- [8] Gill JH. Avian skin diseases. *Vet Clin North Am Exotic Anim Pract*. 2001; 4: 463- 492.
- [9] Koski MA. Dermatologic diseases in psittacine birds: an investigational approach. *Sem Avian Exotic Pet Med*. 2002;11: 105-124.
- [10] Lierz M, Fischer D. Clinical technique: imping in birds. *J Exotic Pet Med*. 2011; 20: 131-137.
- [11] Gill JH. Avian skin diseases. *Vet Clin North Am Exotic Anim Pract*. 2001;4: 463-492.
- [12] Campbell TW. Mycotoxicosis: A potential threat to captive birds. *Proc Assoc Avian Vet*, Miami, FL, USA; 1986 pp. 129-131.
- [13] Philips JR. Avian mites. *Comp Contin Educ Pract Vet*. 1993; 15: 671-683.
- [14] Macwhirter P. Malnutrition. In: Ritchie BW, Harrison GJ, Harrison LR (Eds). *Avian Medicine: Principles and Application*. Wingers Publishing, Lake Worth, Florida, USA; 1994. pp. 842-861.
- [15] Harrison GJ, McDonald D. Nutritional disorders. In: Harrison GJ, Lightfoot TL (Eds.). *Clinical Avian Medicine*. Spix Publishing, Palm Beach, Florida, USA;2006. pp. 108-140.
- [16] Roudybush T. Growth, signs of deficiency, and weaning in cockatiels fed deficient diets. In: *Proceedings of the Annual Conference of the Association of Avian Veterinarians*, Miami, Florida, USA;1986. pp. 333-340.
- [17] Ullrey DE, Allen ME, Baer DJ. Formulated diets versus seed mixtures for psittacines. *J Nutr*. 1991; 121: S193-S205.
- [18] Deschutter A, Leeson S. Feather growth and development. *World's Poultry Sci J*. 1986; 42: 259-267.
- [19] Klasing KC. *Comparative Avian Nutrition*. CABI Publishing; Oxfordshire, UK. 1986
- [20] Bauck LD. Nutritional problems in pet birds. *Sem Avian Exotic Pet Med*. 1995; 4: 3-8.
- [21] Burgmann PM. Common psittacine dermatologic diseases. *Sem Avian Exotic Pet Med*. 1995; 4: 169-183.
- [22] Bauck L. Radical surgery for the treatment of feather cysts in the canary. *AAV Today*. 1987; 1: 200-201.
- [23] Bowles HL, Odberg E, Harrison GJ. Surgical resolution of soft tissue disorders. In: Harrison GJ, Lightfoot TL (Eds.). *Clinical Avian Medicine*, Spix Publishing, Palm Beach, Florida, USA; 2006 pp. 775-829.
- [24] Schmidt RE. Avian skin diseases: a pathologist's perspective. In: *Proceedings of the Annual Conference of the Association of Avian Veterinarians*, USA; 1987 pp. 117-124.
- [25] Pass DA. The pathology of the avian integument: A review. *Avian Pathol*. 1989; 18: 1-72.
- [26] Perry RA. Pruritic polyfolliculitis and dermatitis in budgerigars (*Melopsittacus undulatus*) and African lovebirds (*Agapornis spp.*). In: *Proceedings of the Association of Avian Veterinarians*, Chicago, IL, USA; 1991 pp. 32-37.
- [27] Oglesbee BL, Oglesbee MJ. Feather dystrophy in a cockatiel (*Nymphicus hollandicus*). *J Assoc Avian Vet*. 1994; 8: 16-20.
- [28] Perry RA, Gill J, Cross GM. Disorders of the avian integument. *Vet Clin North Am Small Anim Pract*. 1991; 21: 1307-1327.
- [29] Ritchie BW. Circoviridae. In: Ritchie BW (Ed.) *Avian viruses: function and control*. Wingers Publishing, Lake Worth, Florida, USA; 1995 pp. 223-252.
- [30] Raidal SR. Avian circovirus and polyomavirus diseases. In: Miller RE, Fowler ME (Eds.). *Fowler's Zoo and Wild Animal Medicine: Current Therapy*, Vol. 7. Elsevier Saunders Inc, St. Louis, Missouri, USA; 2012 pp. 297-303.

- [31] Schoemaker NJ, Dorrestein GM, Latimer KS, Lumeij JT, Kik MJ, van der Hage MH, Campagnoli RP. Severe leukopenia and liver necrosis in young African grey parrots (*Psittacus erithacus erithacus*) infected with psittacine circovirus. *Avian Dis.* 2000; 44: 470-478.
- [32] Cornelissen JMM, Gerlach H, Miller H. An investigation into the possible role of circo and avian polyoma virus infections in the etiology of three distinct skin and feather problems (CUD, FLS, PF) in the rose-faced lovebird (*Agapornis roseicollis*). In: *Proceedings of the European College of Avian Medicine and Surgery*, Munich, Germany; 2001 pp. 3-5.
- [33] Schoemaker NJ. Selected dermatologic conditions in exotic pets. *Exotic DVM.* 1999; 1: 5-11.
- [34] Hess M, Scope A, Heinz U. Comparative sensitivity of polymerase chain reaction diagnosis of psittacine beak and feather disease on feather samples, cloacal swabs and blood from budgerigars (*Melopsittacus undulates*, Shaw 18005). *Avian Pathol.* 2004; 33: 477-481.
- [35] Bonne N, Shearer P, Sharp M, Clark P, Raidal S. Assessment of recombinant beak and feather disease virus (BFDV) capsid protein as a vaccine for psittacine beak and feather disease (PBFD). *J Gen Virol.* 2009; 90: 640-647.
- [36] Ritchie BW. Papovaviridae. In: Ritchie BW (Ed.) *Avian viruses: function and control*. Wingers Publishing, Lake Worth, Florida, USA; 1995. pp. 127-170.