

Angular Limb Deformities in Foals

WHAT IS AN ANGULAR LIMB DEFORMITY?

Angular limb deformities (ALDs) are a relatively common set of conditions affecting foals, primarily during the first few months of life. Reports have estimated a prevalence of up to 11% in Thoroughbred populations but no gender predisposition has been identified. The knee, fetlock and hock are the most frequently affected joints and the condition is described by the direction in which the leg deviates from midline.

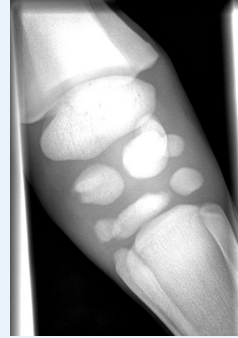CAUSES

Many contributing factors for the development of ALDs have been identified. Maternal diseases that cause an insult to the foal whilst in the uterus such as placentitis, colic and severe metabolic disease may result in incomplete ossification of the small bones, especially in the knees and hocks.

Premature foals may also have incomplete ossification of these bones and early identification is important because the external appearance of the bones can be normal with the limb deformities developing later when the foal exercises. Pressure on these incompletely formed, weak bones may result in the development of an ALD. In addition, once the foal is on the ground, soft tissue trauma and laxity of the soft tissues surrounding the joints can also impact on the straightness of the leg.

Radiograph of Failure of Ossification of the Cuboidal Bones

This radiograph was taken from a newborn foal that had been admitted to the Neonatal Intensive Care Unit because it was collapsed and seizing with a history of premature placental separation. Although it was a Thoroughbred it weighed only 32kg. Although the external appearance of the bones was normal, the small bones of the knee are very small and rounded – in some instances barely there at all. This foal, had it survived, would have had significant orthopaedic problems and therefore it was decided that it would not be appropriate to provide high level intensive care to address its more immediate problems.

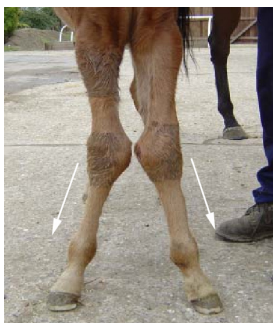

Older foals may develop limb deformities due to inappropriate feeding and the resultant dietary imbalance and disproportionate growth.

MANAGEMENT

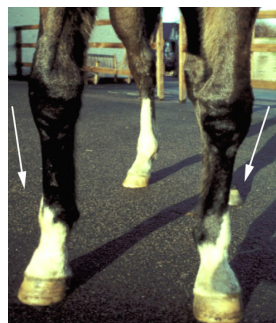
Treatment of ALDs depends on the severity of the condition and the age of the foal. In the simplest of cases with only a mild deformity in a young animal, exercise restriction for a few weeks may be enough to correct the problem.

Should the deformity be more marked, or the foal older, or should the deformity not have responded to restricted exercise alone, then a number of other options are available.



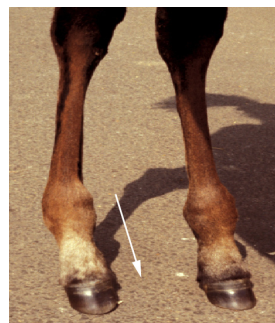CARPAL VALGUS

The limb deviates outward from midline below the knee



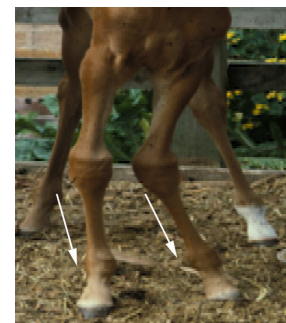
CARPAL VARUS

The limb deviates in towards midline below the knee



FETLOCK VARUS

The right hindlimb deviates towards midline below the fetlock



WINDSWEPT FOAL

An abnormality in which limbs are slanted in one direction in one limb (valgus) and in the opposite direction (varus) in the other. In this foal there is a right forelimb carpal varus and a left forelimb carpal valgus.

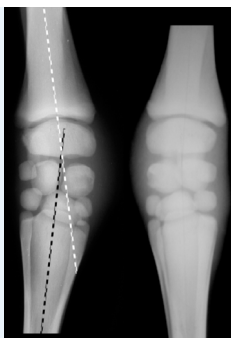
The age of the foal must be kept in mind when treating these conditions. The growth plates in different joints close at different times. Once they close then bone growth stops and so any correction required is then very difficult to achieve. The table below outlines timings for treating these joints.

Joint	When To Treat
Fetlock	Before 2 months of age
Hock	Before 4 months of age
Knee	Before 6 months of age

In order to quantify the problem in hand it is important to take radiographs to make an accurate assessment of the degree and site of angulation involved. Repeat radiographs can also be taken to monitor progress.

Radiograph of Carpal (Knee) Valgus

The cannon bone deviates away from midline below the knee. The white dashes show the direction the cannon bone should follow. The black dashes show the direction it actually follows.



TREATMENT

Corrective Farriery

Firstly the foot should be trimmed to balance the hoof wall. Nailed or glue-on extensions can then be applied to one wall whilst the other wall is often lowered by trimming.



Regular assessment by the farrier, vet and stud team is essential to ensure this is aiding in correction of the deformity and to ensure that over-correction does not occur.

Shockwave therapy

A useful non-invasive procedure that can be performed in the sedated foal in an attempt to try and stimulate bone growth at the point of



application. Shockwaves are high energy soundwaves that are produced by a projectile within the handheld unit. When the unit is applied to the foal's skin they are transferred across the skin to the target tissue. The energy transferred by the shockwave is thought to cause an inflammation-like response and recruit new blood vessels and bone-building cells (osteoblasts) to the area. A typical course would consist of 3 treatments at 2 weekly intervals but is dependent upon progress.

Surgery

This is often advised for more severe deformities or for those near the end of the window for maximum growth. Two types of procedures can be performed:

1. **A periosteal strip** - this involves cutting into the periosteum (bone lining) and releasing the tension at the level of the growth plate, therefore accelerating growth on the shorter side.
2. **Transphyseal Bridging** - a screw or wire with screws can be placed across the growth plate to slow growth on the long side. The implants can then be removed once the desired growth retardation has been achieved.

PROGNOSIS

The prognosis for ALDs is generally good if the deformity is identified and quantified early and the appropriate management instituted within the window of opportunity for that particular joint. In most instances, conservative treatment alone is generally most successful.

ACKNOWLEDGEMENTS

Many thanks to Tim Greet, Andy Bathe and Sarah Boys-Smith at Rosssdales Equine Hospital for their photographs and assistance.