



**University of
Zurich**^{UZH}

**Zurich Open Repository and
Archive**

University of Zurich
University Library
Strickhofstrasse 39
CH-8057 Zurich
www.zora.uzh.ch

Year: 2011

New vertebral and rib material point to modern bauplan of the Nariokotome *Homo erectus* skeleton

Häusler, Martin ; Schiess, Regula ; Böni, Thomas

Abstract: The double S shape of the vertebral column is one of the most important evolutionary adaptations to human bipedal locomotion, providing an optimal compromise between stability and mobility. It is commonly believed that a six element long lumbar spine facilitated the critical adoption of lumbar lordosis in early hominins, which contrasts with five lumbar in modern humans and four in chimpanzees and gorillas. This is mainly based on the juvenile *Homo erectus* skeleton KNM-WT 15000 from Nariokotome, Kenya. Yet, the biomechanical advantage of a long lumbar spine is speculative. Here we present new vertebral and rib fragments of KNM-WT 15000. They demonstrate that the sixth to the last presacral vertebra possesses rib facets and therefore indicate the presence of only five lumbar and twelve thoracic segments, as is characteristic of modern humans. Moreover, they show that no additional element was located between the sixth to the last presacral vertebra and Th11 as suggested in the original description. The transition from thoracic to lumbar type orientation of the facet joints that takes place at Th11 is thus at the same segment as in over 40% of modern humans, suggesting an identical lumbar mobility and capacity for lordosis. Taken together, KNM-WT 15000 had one vertebra less than previously thought irrespective of whether rib-free lumbar vertebrae or vertebrae that bear lumbar-like articular processes are counted. Furthermore, the new rib fragments imply a rearrangement of the ribs that results in a symmetrical rib cage. This challenges previous claims for idiopathic or congenital scoliosis. We conclude that the bauplan of the hominin axial skeleton is more conservative than previously thought.

DOI: <https://doi.org/10.1016/j.jhevol.2011.07.004>

Posted at the Zurich Open Repository and Archive, University of Zurich

ZORA URL: <https://doi.org/10.5167/uzh-50126>

Journal Article

Accepted Version

Originally published at:

Häusler, Martin; Schiess, Regula; Böni, Thomas (2011). New vertebral and rib material point to modern bauplan of the Nariokotome *Homo erectus* skeleton. *Journal of Human Evolution*, 61(5):575-582.

DOI: <https://doi.org/10.1016/j.jhevol.2011.07.004>

New vertebral and rib material point to modern bauplan of the Nariokotome *Homo erectus* skeleton

Martin Haeusler^{1,2,3,4}, Regula Schiess² & Thomas Boeni^{3,4}

¹ *Cantonal Hospital Chur, Loëstrasse 190, 7000 Chur, Switzerland*

² *Anthropological Institute and Museum, University of Zuerich, Winterthurerstrasse 190,
8057 Zuerich, Switzerland*

³ *Centre for Evolutionary Medicine, University of Zuerich, Winterthurerstrasse 190, 8057
Zuerich, Switzerland*

⁴ *Orthopaedische Universitaetsklinik Balgrist, Forchstrasse 340, 8008 Zuerich, Switzerland*

Corresponding author:

Martin Haeusler, *Cantonal Hospital Chur, Loëstrasse 190, 7000 Chur, Switzerland*

email: mfh@aim.uzh.ch

Abstract

The double S-shape of the vertebral column is one of the most important evolutionary adaptations to human bipedal locomotion, providing an optimal compromise between stability and mobility. It is commonly believed that a six element long lumbar spine has facilitated the critical adoption of the lumbar lordosis in early hominins, which contrasts to five lumbar in modern humans and four in chimpanzees and gorillas. This is mainly based on the juvenile *Homo erectus* skeleton KNM-WT 15000 from Nariokotome, Kenya. Yet, the biomechanical advantage of a long lumbar spine is speculative. Here we present new vertebral and rib fragments of KNM-WT 15000. They demonstrate that the sixth to the last presacral vertebra possessed rib facets and therefore indicate the presence of only five lumbar and twelve thoracic segments, as is characteristic of modern humans. Moreover, they show that no additional element was located between the sixth to the last presacral vertebra and Th11 as suggested in the original description. The transition from thoracic to lumbar type orientation of the facet joints that takes place at Th11 is thus at the same segment as in over 40% of modern humans, suggesting an identical lumbar mobility and capacity for lordosis. Taken together, KNM-WT 15000 had one vertebra less than thought previously irrespective of whether rib-free lumbar vertebrae or vertebrae that bear lumbar like articular processes are counted. Furthermore, the new rib fragments imply a rearrangement of the ribs that results in a symmetrical rib cage. This challenges previous claims for idiopathic or congenital scoliosis. We conclude that the bauplan of the hominin axial skeleton is more conservative than previously thought.

Keywords

Early hominids; vertebral column; axial skeleton; scoliosis; facet joint orientation

The lumbar spine is the focus of the ubiquitous low back problems in modern humans in response to locomotor adaptations during hominin evolution. It also has experienced the most extensive morphological changes. A number of different scenarios have been developed to explain the evolution of the axial skeleton and its segmentation pattern (Latimer and Ward, 1993; Sanders, 1998; Haeusler et al., 2002; Pilbeam, 2004; Rosenman et al., 2004; Lovejoy, 2005; Filler, 2007; Lovejoy et al., 2009; McCollum et al., 2010). Most authors believe that early hominins possessed a long lumbar spine of six elements, which only after *Homo erectus* has been reduced to the modern mode of five elements. In contrast, our closest living relatives, the African great apes, have a stiffened trunk skeleton with a modal number of four lumbar vertebrae (Schultz, 1930). As their body centre of gravity is located near the umbilicus, they have to flex their hips and knees when they stand up on their hind legs in order to prevent falling over, which requires constant muscle activity during bipedal standing (Kummer, 1975). In humans, on the other hand, the lumbar lordosis brings the body mass centre above the hip joints, which is thus fundamental to bipedality. The critical adoption of lumbar lordosis in early hominins is often believed to have been facilitated by a numerical elongation of the lumbar spine, thereby reducing the wedging angle and shearing stress at each element compared to the five element lumbar spine of modern humans (Latimer and Ward, 1993; Sanders, 1998). Recently, however, Lovejoy and colleagues (2009; McCollum et al., 2010) conjectured that the six-element long lumbar spine of early hominins was retained from the common ancestor of apes and old world monkeys, which would imply that the lumbar region was shorted independently in gibbons, orang-utans, gorillas, chimpanzees and humans.

Yet the hypothesis of a long lumbar region in early hominins is based on only three fossils that preserve the lower spinal column including the complete lumbar region. Sts 14, a

partial *Australopithecus africanus* skeleton from Sterkfontein, South Africa, preserves the entire series from the second or third thoracic vertebra to the second sacral vertebra. However, its sixth to the last presacral vertebra is anomalous in that the right side has a rib facet, to which a long movable rib articulates, whereas the left side bears a lumbarlike lateral process. Robinson (1972) therefore identified it as the first of six lumbar. Its lateral process shows, however, a costo-transverse foramen that indicates an incomplete fusion of the rib anlage with the vertebra (Haeusler et al., 2002). According to Schultz' (1930) criteria, Sts 14, therefore, counts at best 5 ½ lumbar vertebrae.

Unfortunately, the vertebrae of the thoracolumbar junction are fragmentary in the second *Australopithecus africanus* partial skeleton from Sterkfontein, Stw 431. It was originally reported to possess five lumbar (Benade, 1990; Tobias, 1992). However, subsequent to the description of six lumbar vertebrae in the *Homo erectus* skeleton KNM-WT 15000 (Walker and Leakey, 1993), the presence of six lumbar was mentioned in Stw 431 too (Sanders, 1998). But, after a re-arrangement of the vertebral body and lamina fragments and based on a broken-off rib facet on the sixth to the last presacral element, there now remains little doubt that this specimen possesses five lumbar vertebrae only (Haeusler et al., 2002; Toussaint et al., 2003).

The assumption of a six element long lumbar region in early hominins therefore rests on KNM-WT 15000 (*Homo erectus*). However, the vertebra identified as the first of six lumbar is again fragmentary, preserving only part of the body and the lamina with a lumbar type inferior articular process (Walker and Leakey, 1993). The cranially adjacent vertebra (Th12) is reported to be missing, but Th11 is well preserved. At this vertebra takes place the functionally important transition from lumbar to thoracic type facets, which in many primate species is coupled to locomotor adaptations (Erikson, 1963). This would imply for KNM-WT

15000 an unusually long series of seven vertebrae with dorsomedially oriented superior facet joints, which exceeds the range of variation of modern humans. Haeusler et al. (2002) therefore suggested that the sixth to the last presacral vertebra might in fact be Th12 rather than L1, and that it directly articulates with Th11. This would not only result in a number of five lumbar vertebrae in KNM-WT 15000, but also in just six elements with dorsomedially oriented superior facet joints, a pattern commonly found in modern humans.

While browsing through the boxes containing the KNM-WT 15000 skeleton at the National Museums of Kenya, Nairobi, we identified three previously undescribed vertebral and two dozen rib fragments that were stored in several plastic bags within the skull box of the fossil. Here we describe these fragments and discuss their implications for the segmentation pattern and the thoracic shape of KNM-WT 15000.

Material and methods

The juvenile *Homo erectus* skeleton KNM-WT 15000, discovered in 1984 at Nariokotome, west Lake Turkana, Kenya, is the most complete early hominin fossil, lacking only a few ribs, the first six cervical and two to three thoracic vertebrae, as well as both radii and most hand and foot bones (Brown et al., 1985; Walker and Leakey, 1993). Geologically, the skeleton is approximately 1.53 Ma old and belongs to a boy whose skeletal development is comparable to 11 – 15 year old modern humans (Smith, 1993; Clegg and Aiello, 1999; Smith, 2004), although its absolute age was slightly younger (Dean et al., 2001; Zihlman et al., 2004; Graves et al., 2010). It was studied by MH and RS at the National Museums of Kenya in Nairobi.

The new rib and vertebral fragments do not bear notes or any other marks. Nevertheless, it is very likely that most of them derive from sieving. Others, and particularly the vertebral fragments, may also have been retrieved during a later re-examination of the faunal material from Nariokotome (Walker and Leakey, 1993, and A. Walker, personal communication). The reason for not having been included in the original description may be that some of the rib fragments have been considered too small to be important (Walker and Leakey, 1993). However, they can securely be attributed to KNM-WT 15000 because they (1) do not sample known parts of the skeleton; (2) no other hominin bones have been recovered from the excavation site; the non-hominin species include fish, reptiles, a suid, two hippopotamus and two bovid species (Walker and Leakey, 1993) that all can easily be distinguished from *Homo*; (3) morphology, size, colouring and surface structure of the new fragments closely fit the KNM-WT 15000 fossils; and (4) all vertebral and some rib fragments articulate to previously described parts of the skeleton.

As the transition of facet joint orientation is described to lie more cranially in the juvenile KNM-WT 15000 than in modern humans (Walker and Leakey, 1993), we assessed the position of the transitional vertebra in a comparative sample of 37 subadult modern human vertebral columns with a dental or skeletal age between 8 and 18 years. The skeletons are housed at the Anthropological Institute, University of Zürich. They date from medieval to early modern times and originate from archaeological excavations in the Canton of Zürich, Switzerland. The transitional vertebra has “thoracic type” superior articular facets that are arcs of a circle, the centre of which lies ventrally to the vertebral canal, and “lumbar type” inferior articular facets that are arcs of a circle the centre of which lies dorsally to the vertebral canal.

The present description uses wherever possible the official terminology of human anatomy according to the Terminologia Anatomica (Federative Committee on Anatomical Terminology, 1998).

Results

Right and left pedicle fragments of AR/BA

Insert
Fig. 1
here

Figure 1 shows two of the new vertebral fragments. They can be identified as right and left pedicles of a lower thoracic vertebra due to the presence of rib facets that are placed entirely on the lateral surface of the pedicles and superior articular facets that are dorsomedially oriented. The base of the right fragment includes a wedge-shaped portion of the vertebral body with a 1 cm² large section of the inferior vertebral endplate that exactly fits to the body of the sixth to the last presacral vertebra AR. Moreover, the dorso-caudal extremity of the fragment has an almost perfect contact with the isolated right inferior articular process BA that is only interfered by a few matrix grains sticking on the contact area. The new right pedicle thus confirms that AR and BA belong together.

The left pedicle fragment has a less close contact to the vertebral body AR. The contact area is more eroded compared to that on the right side and a large wedge-shaped flake of bone is missing from the inferior side of the left pedicle's root. However, morphology and metrics closely correspond to the right pedicle fragment and it does not fit to any other vertebra of KNM-WT 15000 than to AR. There is no direct contact between the left pedicle fragment and the lamina BA. It remains a gap of 1 to 2 mm.

The cross-section of the right pedicle measures 5.4 mm medio-laterally and 11.1 mm supero-inferiorly. The left pedicle is 4.6 mm medio-laterally – its supero-inferior diameter cannot be determined because of the damage at the inferior margin. If all fragments are joined, the width of the neural canal can be estimated to about 16 ± 0.5 mm; its height cannot be assessed with enough reliability.

Only a small portion of the right superior articular process is preserved, but the left one is almost complete. The left facet measures 8.2 mm medio-laterally and 13.7 mm supero-inferiorly. Its concave morphology that forms a cylinder sector facing medio-dorsally is thus both compatible with a last thoracic or first lumbar vertebra. However, it is perfectly congruent with the inferior articular facet of vertebra Y (Th11), and the presence of rib facets on the middle of the two new pedicle fragments corroborates the hypothesis of Haeusler et al. (2002) that this vertebra represents Th12 rather than L1.

Pedicle fragment of BI

This fragment is a right pedicle including the superior articular process of a mid-thoracic vertebra. Its basis bears a demi-facet for a rib head. The fragment perfectly fits to vertebra KNM-WT 15000 BI that was identified by Walker and Leakey (1993) as Th9 (Fig. 2). This vertebra so far consists of the lamina with the spinous process and the right inferior articular process only. The contact of the right pedicle fragment with BI is excellent, but a flake of bone is still missing at the base of the transverse process.

Insert
Fig. 2
here

The cross-section of the pedicle measures 5.3 mm medio-laterally and 10.2 mm cranio-caudally. The superior articular facet measures 8.7 mm medio-laterally and 13.4 mm supero-inferiorly.

According to Walker and Leakey (1993), BI is directly caudal of vertebra V (identified as Th8). However, the rather flat joint surface of the new superior articular facet is not congruent to the transversely concave shape of its counterpart on V. This suggests that an additional vertebra was originally interposed in between V and BI.

Rib fragments

The new rib fragments of KNM-WT 15000 comprise five partial rib heads, five sternal extremities and several large fragments of rib bodies. The rib heads can tentatively be attributed to the right fifth rib, left and right sixths ribs, and left and right eighths ribs (Fig. 3). Other fragments include the tubercles probably of the left fourth rib and the left eighth rib. The sternal extremities best fit to the right third rib, left fourth rib, right eighth rib, and left and right twelfth ribs. Another long fragment is the counterpart of AN, the caudalmost left rib.

Insert
Fig. 3
here

A slightly different allocation of the new rib material from that tentatively proposed here cannot be excluded. Nevertheless, the new rib fragments almost certainly imply a major numerical rearrangement of the ribs compared to the original description. The greatest change concerns specimens KNM-WT 15000 BR and BJ, which have been identified originally as the fourth left and fifth right rib, respectively. From a comparison of their metrics, curvature and morphology we conclude, however, that they are direct counterparts and rather should be identified as the eighth pair of ribs (Fig. 3). This leads to a caudal shift by one segment of AU,

AO, BS and AN on the left side, which thus become ribs 9 through 12, and AS and AJ on the right side, which become ribs 10 and 11. On the other hand, ribs AI, AK, AL and AM on the right side, and AP on the left side are shifted by one segment cranially. A consequence of this relocation is a remarkably symmetrical rib cage.

Sequence of the vertebrae

Including vertebra AR/BA, which we have identified as Th12, there are now parts of ten thoracic vertebrae of KNM-WT 15000 known. Based on the number of twelve recovered pairs of ribs, this means that two thoracic vertebrae still have not been recovered. Walker and Leakey (1993) proposed that the missing vertebrae are Th4 and Th6, i.e. the two neighbours of CA. However, the apparently marked change in the orientation of the spinous processes between Th3 and CA does not necessarily imply that a segment is missing here as such a pattern is not uncommon in modern human vertebral columns. Moreover, most metrics of CA are very similar to those of Th3 (see Haeusler et al., 2002, Fig. 8), and the articular facets are acceptably congruent between these two vertebrae.

On the other hand, as described above, the incongruity between the new upper articular facet of BI (Th9) and the lower one of V suggests another gap between these vertebrae. This is also supported by the serial change of the pedicles' cross-sections, the only measurements that are now available for all recovered vertebrae of KNM-WT 15000. We thus tentatively propose the vertebral sequence represented in Figure 4. In the mid-thoracic region, it differs from that suggested by Walker and Leakey (1993) in that Th3 and vertebra CA are direct neighbours, the latter becoming Th4. This leads to a cranial shift of vertebrae W and V to Th6

Insert
Fig. 4
here

and Th7, respectively. The next element, Th8, is missing, and, finally, AR/BA has become Th12 instead of L1.

Discussion

The new elements of the KNM-WT 15000 skeleton, though small in themselves, provide important clues to the function and segmentation of the vertebral column and the shape of the rib cage.

The presence of rib facets on the new pedicle fragments of vertebra AR/BA suggests that this element is the last thoracic instead of the first lumbar element as thought previously. The morphology of the rib facets is typical for a last thoracic and does not fit that of a lumbar vertebra bearing lumbar ribs. Because this vertebra is the sixth to the last presacral element it challenges the widely accepted interpretation that KNM-WT 15000 possessed six lumbar elements. It rather establishes a five element long lumbar spine in this specimen. In addition, the new rib fragments demonstrate the presence of twelve pairs of ribs, whereas so far only eleven pairs have been known. The last pair is relatively long and its morphology clearly differs from that of lumbar ribs, which would have a flat shape resembling that of detached lumbar transverse processes (see Haeusler et al., 2002, and references therein).

Although there are no complete early hominin spinal columns, the three fossils KNM-WT 15000, Stw 431, and Sts 14 preserve the entire lumbar region and a varying number of adjacent thoracic vertebrae (Haeusler et al., 2002). Whereas the anomalous Sts 14 specimen had at best five and a half lumbar vertebrae, both Stw 431 (Haeusler et al., 2002; Toussaint et al., 2003) and KNM-WT 15000 evince an essentially humanlike pattern of axial

segmentation with five rib-free lumbar vertebrae and, as indicated by the new rib fragments of KNM-WT 15000, twelve thoracic vertebrae.

This implies that there is no support from any fossil so far for a six-element-long lumbar column as hypothesised also for *Ardipithecus* by Lovejoy and colleagues (2009; McCollum et al., 2010). Likewise, there is no indication that the critical adoption of the lumbar lordosis in early hominins was facilitated by the incorporation of an extra lumbar element as suggested by Latimer and Ward (1993) and Sanders (1998). In fact, there are no clinical data of modern humans that would show a biomechanical benefit of an increased lumbar count. In contrast, one report suggests that patients with a six-element-long lumbar spine would need stronger muscles to stabilize the upright body, which might contribute to overstraining symptoms and degenerative changes (Rettig, 1959). It thus appears that only a number of five elements guarantees an optimal compromise between stability and mobility of the human lumbar spine (Putz and Müller-Gerbl, 1996).

Some authors thought that the orientation of the articular facets is functionally more important than the presence or absence of ribs and advocated the division of the spine into a pre- and post-transitional region as an alternative to the anatomical thoraco-lumbar definition (Washburn and Buettner-Janusch, 1952; Erikson, 1963). Whereas in the modal modern human condition the articular facets change their orientation at Th12 from thoracic to lumbar type, the transitional vertebra is at Th11 in KNM-WT 15000. According to the identification of the vertebrae by Walker and Leakey (1993) this would imply a post-transitional region of seven segments. Such an extraordinarily long post-transitional region is extremely rare in modern humans – in fact it was never observed in the combined sample of 347 modern human skeletons of Lanier (1939), Allbrook (1955) and Shinohara (1997). In Sts 14 and Stw 431, the post-transitional region includes six elements and is thus also longer than the modal condition

of modern humans. Lovejoy (2005), therefore, asserted that early hominins had a more mobile spine with a greater capacity of lordosis than that of average modern humans.

Insert
Tab. 1
here

Yet another consequence of the new vertebral fragments of KNM-WT 15000 is the refutation of an additional element between Th11 and the sixth to the last presacral vertebra. This implies that the post-transitional region of this specimen is only six instead of seven elements long as thought previously, and therefore the same length as that of Sts 14 and Stw 431. Although this is not the modal condition in modern humans, it is not at all unusual, as it occurs in between 40% to 50% of all skeletons. Our analysis of 37 subadult modern human vertebral columns confirmed these numbers. Thus, in 48.5% of them the transition in facet joint orientation was observed at level Th11 (Table 1). Earlier studies reported a lower frequency, but they used different definitions of thoracic and lumbar type articular facets (Hasebe, 1913; Stewart, 1932).

A study based on CT scans even found the transition to lie in as many as 70% of all cases at Th11 (Singer et al., 1988). This exceptionally high percentage might be inherent to the method of analyzing a single axial CT scan through the facet joints rather than the orientation of the entire facet as in skeletal studies, but it confirms that early hominins are not unique with respect to the position of the transitional vertebra. Moreover, 54% of all individuals in this study had a gradual rather than an abrupt transition. A high percentage of 10 to 20% with a gradual transition was also recorded by Shinohara (1997). Together with a high rate of asymmetries, this makes the functional significance of the transition from lumbar to thoracic type facet joint orientation questionable. As there are no data for modern humans that demonstrate a different spinal mobility or capacity for lumbar lordosis in the population with the transitional vertebra at Th11 compared to those individuals where the transitional

vertebra lies at Th12 or L1, we find no support for Lovejoy's (2005) assertion of a divergent spinal function in early hominins compared to modern humans.

A third possibility to divide the spinal column into different regions in addition to the presence or absence of ribs and the orientation of the articular processes has been proposed by Giebel (1853). He suggested that the direction of the spinous processes is functionally most important. The vertebra at which the spinous processes change their orientation is known as the diaphragmatic or anticlinal vertebra. In the modern human spine it is typically found at the level of Th11, with a range from Th10 to Th12 (Double, 1912; Danforth, 1930; Ankel, 1967). Although the spinous process of Th12 is not preserved in KNM-WT 15000, the abrupt change in the inclination of the spinous processes between Th10 and Th11 suggests that the position of the diaphragmatic vertebra did not differ from that of modern humans and that the vertebral columns of early hominins and modern humans can therefore be viewed as functionally equivalent with respect to this feature.

KNM-WT 15000 not only is crucial for deducing the evolution of lumbar lordosis and axial segmentation. The remarkably complete juvenile skeleton is also the main source for our knowledge of *Homo erectus* biology. This role is challenged by reports on the presence of significant congenital pathologies, including skeletal dysplasia and scoliosis with associated vertebral and rib distortions (Latimer and Ohman, 2001; Ohman et al., 2002; Lovejoy, 2005). Rib asymmetries are, however, only present in significant forms of scoliosis and result in the pathognomonic rib hump on the convex side of a thoracic curve (Stokes et al., 1989). This does not fit the heterogeneous pattern of asymmetries inherent to the original identification of the ribs (Fig. 3), and the alleged presence of scoliosis is in stark conflict with the symmetrical rib cage that results from the reallocation of the ribs suggested by the new fragments. Other pathologies cited by Latimer and Ohman (2001), including clavicular asymmetries, spina

bifida, diminutive and platyspondylic vertebrae, condylus tertius, and neural canal stenosis, are either of no pathological value or their presence could not be confirmed in KNM-WT 15000, thus making the diagnosis of a congenital dysplasia unlikely (Schiess et al., 2006a, b; Haeusler et al., in prep).

Alternatively, Jellema (1993) proposed that some ribs with an anomalous curvature might be plastically deformed, particularly the fourth and fifth ribs according to the original numbering. These are, however, just those ribs that become the farthest displaced in the present analysis. In addition, the now symmetrical rib cage makes the presence of major plastic deformation implausible.

Jellema (1993) deduced an essentially modern human barrel shaped thorax in KNM-WT 15000, which is cranially and caudally narrow. This is consistent with the new arrangement of the ribs since the first, second and the left third ribs retain their original positions. On the other hand, the two most inferior ribs in Jellema's (1993) analysis, ribs 9 and 10, seemed to be unusually short compared to those of either adult or juvenile humans. Their lengths fit, however, better the here proposed positions at segment 10 and 11.

In contrast to the ribs, only the mid-thoracic region is affected by the rearrangement of KNM-WT 15000's vertebrae. Because in this region MacLarnon (1993; MacLarnon and Hewitt, 1999) did not observe the expansion of the vertebral canal that is typical of modern humans, she deduced a less developed capacity for breathing control and speech in *H. erectus*. Surprisingly, however, she based her analysis on minimum vertebral canal height and width, which lies in KNM-WT 15000 at Th1 and Th10. This is far from the mid-thoracic expansion of the spinal canal that reflects the better innervation of the intercostal and abdominal muscles of modern humans. Thus, although MacLarnon (1993) probably showed that spinal canal

dimension in the cranial- and caudalmost sections of the thorax of KNM-WT 15000 are smaller than expected in modern humans, the question of inferior breathing control does not seem to be adequately answered and it must remain open whether the present rearrangement of the mid-thoracic vertebrae that is implied by the new superior articular facet of BI had any influence on it.

Summary and conclusions

Although the new vertebral and rib fragments might initially have appeared irrelevant due to their smallness, they provide valuable information about the axial skeleton of *Homo erectus*. They indicate that

(1) KNM-WT 15000 possessed twelve thoracic and five lumbar vertebrae and thus the same segmentation pattern of the spinal column as most modern humans. This is based on the number of 12 pairs of ribs and the presence of rib facets on the new pedicles of the sixth to the last presacral vertebra. Its articular processes match those of Th11, suggesting that no additional vertebra is missing in between these two elements. This implies that the KNM-WT 15000 vertebral column included one vertebra less than described by Walker and Leakey (1993). As a number of five lumbar is best compatible with the evidence from Sts 14 and Stw 431, it likely characterized early hominins in general. Hence, there is no indication that the important adoption of lumbar lordosis in early hominins has been facilitated by a six-element-long lumbar spine.

(2) The transition from ventrally to dorsally oriented articular facets takes place in KNM-WT 15000, as in both Sts 14 and Stw 431, at the sixth rather than the seventh to the last presacral

vertebra as thought previously. This is because the new vertebral fragments show that no additional vertebra is missing between Th11 and the sixth to the last presacral vertebra, now identified as Th12. Although this still is not the modal configuration in modern humans, it is not permissible to infer a different spinal function in early hominins, as it is shared with more than 40% of modern humans. There is no indication that they possess a significantly distinct lumbar mobility from the rest of the population where the transitional vertebra is at Th12 or L1.

(3) Ten of the twelve thoracic vertebrae of KNM-WT 15000 are now known. Whereas Walker and Leakey (1993) proposed that Th4, Th6 as well as Th12 are missing, our results indicate that rather Th5 and Th8 are missing, and that Th12 is preserved as the sixth to the last presacral vertebra. The effect of the associated rearrangement of the mid-thoracic vertebrae on breathing control and speech in *H. erectus* remains to be re-analyzed.

(4) The rearrangement of the ribs of KNM-WT 15000 indicates a symmetrical rib cage that refutes previous claims for idiopathic or congenital scoliosis (Latimer and Ohman, 2001; Ohman et al., 2002; Lovejoy, 2005).

Acknowledgements

We thank Emma Mbuu and Meave Leakey who kindly permitted us to study the original KNM-WT 15000 skeleton. We are also very grateful to the rest of the staff of the National Museums of Kenya, Nairobi, for their great help and welcome. We thank Alan Walker, Katherine Whitcome, Georg Halder, Frank Ruehli and especially Henry McHenry for constructive comments on earlier drafts of the manuscript. Travelling expenses of MH and RS have been supported by the A.H. Schultz-Stiftung.

References

- Allbrook, D.B., 1955. The East African vertebral column. *Am. J. Phys. Anthropol.* 13:489-514.
- Ankel, F., 1967. Morphologie von Wirbelsäule und Brustkorb. In: Hofer, H., Schultz, A.H., Starck, D. (Eds.) *Primatologia*. Karger, Basel, pp 1-120.
- Benade, M.M., 1990. Thoracic and lumbar vertebrae of African hominids ancient and recent: Morphological and functional aspects with special reference to upright posture. Master's Thesis, University of the Witwatersrand, Johannesburg.
- Brown, F., Harris, J., Leakey, R., Walker, A., 1985. Early *Homo erectus* skeleton from west Lake Turkana, Kenya. *Nature* 316:788-792.
- Clegg, M., Aiello, L.C., 1999. A comparison of the Nariokotome *Homo erectus* with juveniles from a modern human population. *Am. J. Phys. Anthropol.* 110:81-93.
- Danforth, C.H., 1930. Numerical variation and homologies in vertebrae. *Am. J. Phys. Anthropol.* 14:463-481.
- Dean, M.C., Leakey, M.G., Reid, D.J., Schrenk, F., Schwartz, G.T., Stringer, C., Walker, A., 2001. Growth processes in teeth distinguish modern humans from *Homo erectus* and earlier hominins. *Nature* 414:628-631.
- Double, A.F., Le, 1912. *Traité des variations de la colonne vertébrale de l'homme*. Vigot Frères, Paris.
- Erikson, G.E., 1963. Brachiation in New World monkeys and in anthropoid apes. *Symp. Zool. Soc. Lond.* 10:135-164.

Federative Committee on Anatomical Terminology, F.C.A.T., 1998. Terminologia Anatomica - International anatomical terminology. Thieme, Stuttgart.

Filler, A.G., 2007. Homeotic evolution in the mammalia: diversification of therian axial seriation and the morphogenetic basis of human origins. PLoS One 2:e1019.

Giebel, C.G., 1853. Mittheilungen über die Gränze zwischen Brust- und Lendengegend in der Wirbelsäule der Säugethiere und deren Zahlenverhältnisse. Zeitschrift für die gesammten Naturwissenschaften 1:261.

Graves, R.R., Lupo, A.C., McCarthy, R.C., Wescott, D.J., Cunningham, D.L., 2010. Just how strapping was KNM-WT 15000? J. Hum. Evol. 59:542-554.

Haeusler, M., Martelli, S., Boeni, T., 2002. Vertebrae numbers of the early hominid lumbar spine. J. Hum. Evol. 43:621-643.

Haeusler, M., Schiess, R., Boeni, T., in prep. Evidence for degenerative changes and low back pain but no skeletal dysplasia in juvenile *Homo erectus* skeleton.

Hasebe, K., 1913. Die Wirbelsäule der Japaner. Z. Morphol. Anthropol. 15:259-380.

Jellema, L.M., Latimer, B., Walker, A., 1993. The rib cage. In: Walker, A., Leakey, R. (Eds.) The Nariokotome *Homo erectus* Skeleton. Springer, Berlin, pp 294-325.

Kummer, B.K.F., 1975. Functional adaptation to posture in the pelvis of man and other primates. In: Tuttle, R.H. (Ed.) Primate Functional Morphology and Evolution. Mouton, The Hague, pp 281-290.

Lanier, R.R., 1939. The presacral vertebrae of American White and Negro males. Am. J. Phys. Anthropol. 25:341-420.

Latimer, B., Ohman, J.C., 2001. Axial dysplasia in *Homo erectus* [abstract]. J. Hum. Evol. 40:A12.

Latimer, B., Ward, C.V., 1993. The thoracic and lumbar vertebrae. In: Walker, A., Leakey, R. (Eds.) The Nariokotome *Homo erectus* Skeleton. Springer, Berlin, pp 266-293.

Lovejoy, C.O., 2005. The natural history of human gait and posture. Part 1. Spine and pelvis. Gait Posture 21:95-112.

Lovejoy, C.O., Suwa, G., Simpson, S.W., Matternes, J.H., White, T.D., 2009. The great divides: *Ardipithecus ramidus* reveals the postcrania of our last common ancestors with African apes. Science 326:100-106.

MacLarnon, A., 1993. The vertebral canal. In: Walker, A., Leakey, R. (Eds.) The Nariokotome *Homo erectus* Skeleton. Springer, Berlin, pp 359-447.

MacLarnon, A.M., Hewitt, G.P., 1999. The evolution of human speech: The role of enhanced breathing control. Am. J. Phys. Anthropol. 109:341-363.

McCollum, M.A., Rosenman, B.A., Suwa, G., Meindl, R.S., Lovejoy, C.O., 2010. The vertebral formula of the last common ancestor of African apes and humans. J Exp Zool B Mol Dev Evol 314:123-134.

Ohman, J.C., Wood, C., Wood, B., Crompton, R.H., Günther, M.M., Yu, L., Savage, R., Wang, W., 2002. Stature-at-death of KNM-WT 15000. Hum. Evol. 17:79-94.

Pilbeam, D., 2004. The anthropoid postcranial axial skeleton: Comments on development, variation, and evolution. J. Exp. Zool. 302B:241-267.

Putz, R.L.V., Müller-Gerbl, M., 1996. The vertebral column - a phylogenetic failure? A

theory explaining the function and vulnerability of the human spine. *Clin. Anat.* 9:205-212.

Rettig, H., 1959. Patho-Physiologie angeborener Fehlbildungen der Lendenwirbelsäule und des Lendenwirbelsäulen-Kreuzbein-Überganges. *Z. Orthop. Ihre Grenzgeb.* 91:1-135.

Robinson, J.T., 1972. *Early Hominid Posture and Locomotion*. University of Chicago Press, Chicago.

Rosenman, B.A., Heiple, K.G., Lovejoy, C.O., 2004. Lumbar vertebral number in early hominids: Anatomical and developmental considerations [abstract]. *Am. J. Phys. Anthropol. Suppl.* 38:169-170.

Sanders, W.J., 1998. Comparative morphometric study of the australopithecine vertebral series Stw-H8/H41. *J. Hum. Evol.* 34:249-302.

Schiess, R., Haeusler, M., Langenegger, E., 2006a. How pathological is the Nariokotome boy KNM-WT 15'000 (*Homo erectus*)? [abstract]. *Am. J. Phys. Anthropol. Suppl.* 42:159.

Schiess, R., Haeusler, M., Langenegger, E., 2006b. Wie pathologisch ist die Wirbelsäule des Nariokotome Boys KNM-WT 15'000 (*Homo erectus*)? *Bulletin der Schweizerischen Gesellschaft für Anthropologie* 12:13-22.

Schultz, A.H., 1930. The skeleton of the trunk and limbs of higher primates. *Hum. Biol.* 2:303-438.

Shinohara, H., 1997. Changes in the surface of the superior articular joint from the lower thoracic to the upper lumbar vertebrae. *J. Anat.* 190 (Pt 3):461-465.

Singer, K.P., Bredahl, P.D., Day, R.E., 1988. Variations in zygapophyseal joint orientation and level of transition at the thoracolumbar junction. Preliminary survey using computed

tomography. *Surg. Radiol. Anat.* 10:291-295.

Smith, B.H., 1993. The physiological age of KNM-WT 15000. In: Walker, A., Leakey, R. (Eds.) *The Nariokotome Homo erectus skeleton*. Springer, Berlin, pp 195-220.

Smith, S.L., 2004. Skeletal age, dental age, and the maturation of KNM-WT 15000. *Am. J. Phys. Anthropol.* 125:105-120.

Stewart, T.D., 1932. The vertebral column of the Eskimo. *Am. J. Phys. Anthropol.* 17:123-136.

Stokes, I.A., Dansereau, J., Moreland, M.S., 1989. Rib cage asymmetry in idiopathic scoliosis. *J. Orthop. Res.* 7:599-606.

Tobias, P.V., 1992. New researches at Sterkfontein and Taung with a note on Piltdown and its relevance to the history of palaeo-anthropology. *Trans. Roy. Soc. S. Afr.* 48:1-14.

Toussaint, M., Macho, G.A., Tobias, P.V., Partridge, T.C., Hughes, A.R., 2003. The third partial skeleton of a late Pliocene hominin (Stw 431) from Sterkfontein, South Africa. *S. Afr. J. Sci.* 99:215-223.

Walker, A., Leakey, R., 1993. The postcranial bones. In: Walker, A., Leakey, R. (Eds.) *The Nariokotome Homo erectus Skeleton*. Springer, Berlin, pp 95-160.

Washburn, S.L., Buettner-Janusch, J., 1952. The definition of thoracic and lumbar vertebrae. *Am. J. Phys. Anthropol.* 10:251-252.

Zihlman, A., Bolter, D., Boesch, C., 2004. Wild chimpanzee dentition and its implications for assessing life history in immature hominin fossils. *Proc. Natl. Acad. Sci. U. S. A.* 101:10541-10543.

Tables

Table 1. Position of the vertebra bearing thoracic type superior facet joints and lumbar type inferior facet joints in modern humans

Author	Material	Sample size	Th11	Th12	L1
Present study	subadult skeletons	N=37	48.6% ¹	48.6% ²	2.7%
Shinohara (1997)	Adult skeletons	N=32	44% ³	53% ⁴	3%
Allbrook (1955)	Adult skeletons	N=115	43.5%	51.3%	5.2% ⁵
Lanier (1939)	Adult skeletons	N=200	40.5%	49%	10.5%
Singer et al. (1988)	CT scans, adults	N=214	70% ⁶	29%	0.5%

¹ including 2 specimens (5.4%) asymmetric Th11 right/Th12 left

² including 1 specimen (2.7%) asymmetric Th12 left/L1 right

³ including 22% with a more gradual change

⁴ including 9% with a more gradual change

⁵ four of these six vertebral columns had six lumbar vertebrae

⁶ including 54% with a more gradual change; the percentages of Th11 – L1 do not sum up to 100 in Singer et al. (1988)

Figures




Figure 1. Thoracic vertebra 12 of KNM-WT 15000, showing the two new right and left pedicle fragments joined with the previously described vertebral body AR and lamina fragment BA (semitransparent). Note the costal facets on the lateral side of the pedicles that identify this vertebra as the last thoracic rather than as L1 as thought previously (arrows).

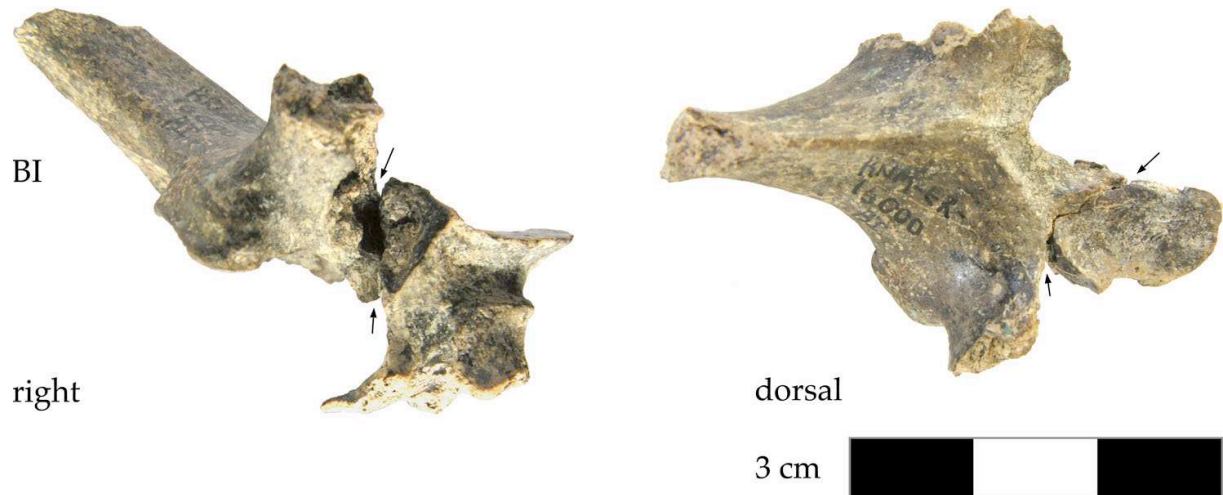


Figure 2. The lamina KNM-WT 15000 BI (Th9) together with the new right pedicle and superior articular process. The contact between the two pieces is excellent though a flake of bone broken off from the base of the transverse process (arrows).

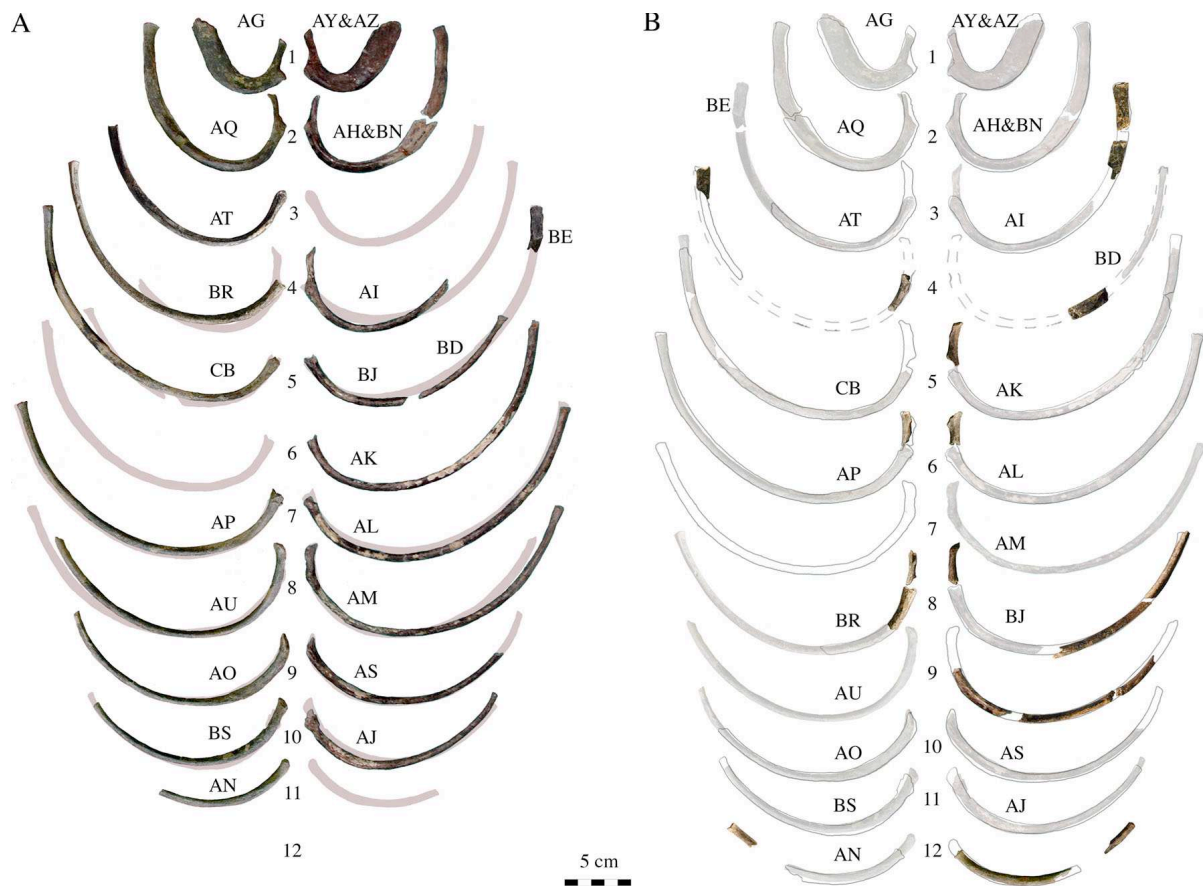

Figure 3. Ribs of KNM-WT 15000, superior view. **A**, Original sequence according to Walker and Leakey (1993). The marked non-systematic asymmetry that is made evident by the mirrored ribs shown in light grey does not fit a rib hump, which would be pathognomonic of significant scoliosis. **B**, Tentative position of the new fragments and consequent rearrangement of the ribs. Previously described specimens are semitransparent. The rib cage has become perfectly symmetric as shown by the contours of the mirrored ribs and includes now 12 partial rib pairs.




Figure 4. The vertebral column of KNM-WT 15000 reconstructed with the three new fragments. **A**, The original identification of the vertebrae according to Walker and Leakey (1993) is indicated in brackets. Note that Th12 is not longer missing. **B**, Measurements of the supero-inferior (SI) and medio-lateral (ML) diameter of the pedicles (in mm). The dimensions of the new pedicles harmonically fit in the series of the other vertebrae.